

# Van neck-odelberg disease: An unusual cause of pain on the hip in children.

Andrea Cosentino\*, Gianni Odorizzi, Olaf Stefan Schmidt, Wilhelm Berger

Department of Orthopedic and Traumatology, Franz Tappeiner Hospital–ASDAA Azienda Sanitaria Alto Adige, Meran (Bz), Italy

**Received:** 27 February, 2023, Manuscript No. AAJCP-23-89264; **Editor assigned:** 01 March, 2023, Pre QC No. AAJCP-23-89264(PQ); **Reviewed:** 10 March, 2023, QC No. AAJCP-23-89264; **Revised:** 20 March, 2023, Manuscript No. AAJCP-23-89264(R); **Published:** 30 March, 2023, DOI:10.35841/0971-9032.27.03.1825-1827.

## Abstract

**Introduction:** An atypical ossification pattern of the ischiopubic synchondrosis, also known as van neck-odelberg disease, is often a misdiagnosed cause of pain in the pediatric pelvis. The main symptom is an unusual pain of one (rarely both) hip, without trauma or after an overuse of the limb, which can lead to a limitation in movement or limping. The purpose of our article is to describe the clinical and radiological findings of this rare and often misdiagnosed condition.

**Materials and methods:** Because of the non-specificity of the symptoms, those young patients are often over-studied with numerous unnecessary instrumental investigations: hip-ultrasound, radiographs, magnetic resonance or computer tomography scans and some other invasive procedure. The simple radiograph can identify this condition, but, especially for boys, those are often negative because of the external protection of the reproductive system. In the acute phase of this clinical condition, Non-Steroidal Anti-Inflammatory Drugs (NSAIDs) and rest from sport are the main therapy and the symptoms are resolved in about 1-2 weeks. The radiological findings will come back to the normality in some years.

**Results and conclusion:** A child that comes in the emergency room complaining about strong pain in the hip is always a challenging situation. Understanding this misdiagnosed condition can lead to avoid unnecessary instrumental examinations.

**Keywords:** Van Neck-Odelberg; Hip pain; Ischiopubic synchondrosis, Osteochondrosis.

## Abbreviations

NSAIDs: Non-Steroidal Anti-Inflammatory Drugs; MRI: Magnetic Resonance Imaging; CT: Computer Tomography;

CRP: C-Reactive Protein; ESR: Erythrocyte Sedimentation Rate; STIR: Short-TI Inversion; IPS: Ischiopubic Synchondrosis.

Accepted on 19th March, 2023

## Introduction

An atypical ossification pattern of the ischiopubic synchondrosis (also defined osteochondrosis of the synchondrosis) leads in children to a strong pain in the hip joint, referred often also to the quadriceps or adductor muscles, without an history of trauma.

This condition, also known as van neck-odelberg-voltancoli disease, is a rare and often misdiagnosed skeletal growth disturb of the ischiopubic synchondrosis, the connection between the ischium and pubic bone, made primarily of hyaline cartilage [1,2].

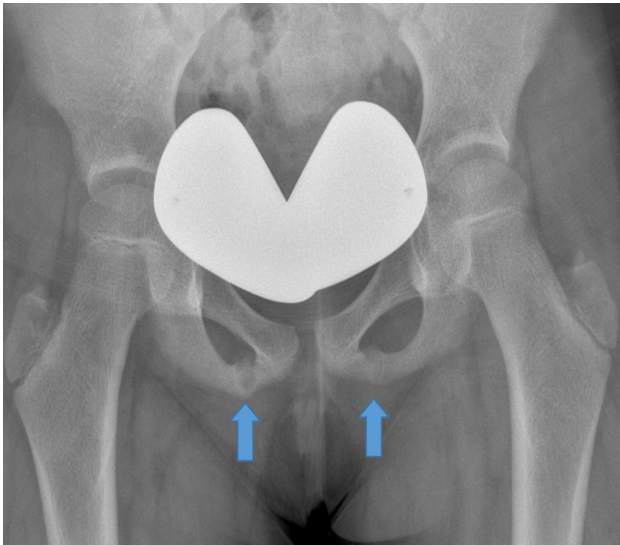
In our little hospital in this year, we've already found six children with unspecific hip pain; pediatricians had referred them to us after several hospitalizations without any definitive diagnosis. The purpose of our review is to describe the most common clinical and radiological findings of this rare or

misdiagnosed condition, in order to reduce stress and anxiety in children and their parents and to reduce costs of unnecessary examinations [3].

## Materials and Methods

Due to an asymmetric and delayed closure of this cartilaginous joint between four and twelve years old (average at nine), those children refer a diffuse pain in their hip without a history of trauma, often after a sport training or overuse of the lower limb. The clinical examination shows a groin pressure pain above the lower pubic extremity. Passive stretching of the adductor muscles can also cause pain [1].

The first step in these clinical findings is always a standard antero-posterior radiograph (Figure 1) and sometimes a hip-ultrasound, just to rule out a coxitis fugax. Blood test are always negative, especially for C-Reactive Protein (CRP) or Erythrocyte Sedimentation Rate (ESR) [4].



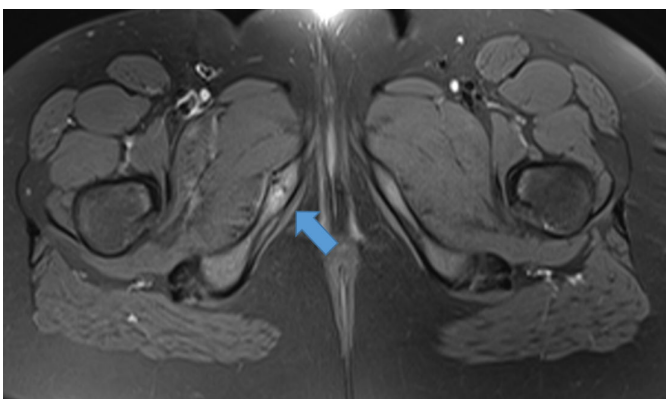
**Figure 1.** Antero-posterior radiograph and a hip-ultrasound.

While performing the radiographs, comes often the most important error for the misdiagnosis of this condition: because of the young age of the children, the radiology technician put a lead protection over the reproductive system that covers the area of interest [5].

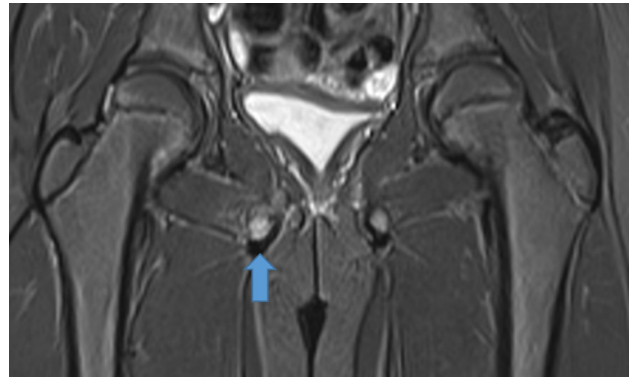
We suggest performing a standard anterior-posterior pelvic radiograph in order not to overlook a double-sided finding. The only radiological finding is a uni or bilateral overgrowth of the pre-pubescent junction between the inferior pubic ramus and ischium, which can be seen on radiographs during skeletal maturation. Other investigations are performed just to increase certainly diagnosis and will allow the correct differential diagnosis with stress fractures, posttraumatic osteolysis, infections or tumors that leads to unnecessary invasive procedures (for example biopsy, scintigraphy, etc.).

## Results

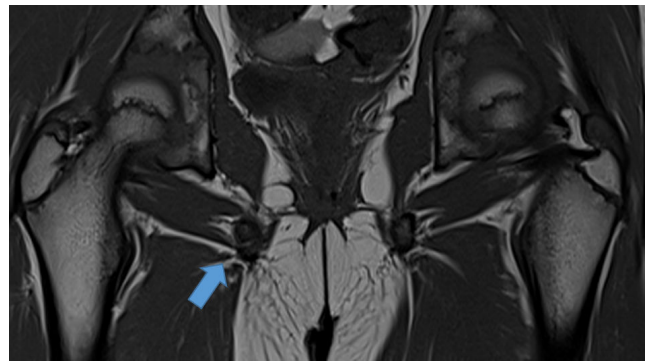
If the diagnosis is still unclear, an MRI is required [2]. In the ossification phase, the child's pelvis shows focal low signal in T1 weighting and increased signal in T2 weighting, fat saturation, or STIR sequence. Elevated signal from adjacent adductors may also be a sign of underlying tendinopathy (Figures 2-4).



**Figure 2.** Diagnosis of MRI scan in ossification phase.



**Figure 3.** Child's pelvis shows focal low signal in T1 weighting and increased signal in T2 weighting.



**Figure 4.** Elevated signal from adjacent adductors may also be a sign of underlying tendinopathy.

The treatment of this condition is the same of the other osteochondrosis, such as osgood-schlatter or severe. In the acute phase of the inflammation, because of the strong pain, it should be suggested reducing the activity that makes it worse, icing the painful area, and anti-inflammatory medication. The acute and symptomatic phase is usually resolved in 1-2 weeks, with the normalization of the radiological findings in some years.

## Discussion

In 1923, Odelberg first reported three patients, two boys aged 11, 13 years, and a girl 12 years and he described the radiolucent swelling of the ischio-pubic junction of the prepuberal bones. In 1924, van neck also recorded a similar discovery; he reported two patients and he applied the term "ischio-pubic osteocondritis" [1]. Voltancoli in 1925 reported the lesion in four boys all aged 8 or 9 years who were treated by rest in bed [6].

Syncondroses are temporary joints, which appear during skeletal maturation. A hyperostosis of ischio-pubic syncondrosis is the main cause of this pathology. Bilateral widening of IPS is a normal growth entity, but if painful and unilateral, diagnosis becomes difficult [4].

The asymmetric enlargement of IPS is a physiological phenomenon, which is related to the asymmetric mechanical stress of some muscles, such as the adductor, iliopsoas and femur on each half of the pelvis. This will cause the IPS to continue to produce an inflammatory response, and delay the

combination of the cartilage layer and the ossification center [7].

In most cases, the finding is clinically mute children affected by the symptoms often complain of spontaneous or stressful pain in the groin or buttocks. Symptoms often occur when the mutual leg needs to be relieved or when sporty children/adolescents put more stress on the dominant leg [2,7,8].

Any other hip disease should be excluded, for example Morbus Perthes, slipped capital femoral epiphysis, bone tumors or inguinal hernia; a correct radiograph can exclude every one of those just with one image. Reviewing the literature, there are about 30 articles on Pubmed, 10 articles on Pubmed Central and no articles on MeSH.

In a retrospective study, 61% of the investigated children that underwent to instrumental investigations for other reasons, presented this clinical condition [2]; thus, it isn't difficult to think that these clinical findings may be often misdiagnosed for many reasons, such as technical errors by performing radiographs and the lack of knowledge of this situation.

## **Conclusion**

A child that comes in the emergency room referring with strong pain affecting the hip joint should be always correctly investigated. Understanding the appearance of imaging appearances is essential to avoid an unnecessary interventional diagnostic or therapeutic measure that exposes the child and their parents to potential risks, considerable physical and mental stress, and the healthcare system to not essential costs. The course of the disease is benign and improvement occurs in weeks or months with adequate conservative treatment; changes in the images can last for a longer time until complete ossification of the joint.

## **Declarations**

### ***Ethics approval and consent to participate***

Not applicable.

### ***Consent for publication***

Not applicable.

## ***Availability of data and materials***

The datasets used and/or analyzed during the current study are available from the corresponding author on reasonable request.

## ***Acknowledgements***

Not applicable.

## **References**

1. Macarini L, Lallo T, Milillo P, et al. Case report: Multimodality imaging of van neck-odelberg disease. *Indian J Radiol Imaging* 2011; 21(2): 107-10.
2. Herneth AM, Trattnig S, Bader TR, et al. MR imaging of the ischiopubic synchondrosis. *Magn Reson Imaging* 2000; 18(5): 519-24.
3. Paul Byers D. Ischio-pubic osteochondritis. *J Bone Joint Surg Br* 1963; 45(4): 694-702.
4. Oliveira F. Differential diagnosis in painful Ischiopubic Synchondrosis (IPS): A case report. *Iowa Orthop J* 2010; 30: 195-200.
5. Chaudhari AP, Shah G, Patil SS, et al. Van neck-odelberg disease: A rare case report. *J Orthop Case Rep* 2017; 7(1): 24-27.
6. Wait A, Gaskill T, Sarwar Z, et al. Van neck disease: Osteochondrosis of the ischiopubic synchondrosis. *J Pediatr Orthop* 2011; 31(5): 520-4.
7. Stormacq S, Gauquier N, Gilliaux O. Ischiopubic osteochondrosis revealed by an atypical "acute transient synovitis of the hip": A case report. *Arch Pediatr* 2017; 24(11): 1111-1114.
8. Holsti LR. Osteochondritis Ischiopubica. *Acta Radiol* 1956; 45(3): 178-184.

## **\*Correspondence to:**

Andrea Cosentino

Department of Orthopedic and Traumatology,

Franz Tappeiner Hospital,

Via Rossini 5, Meran (BZ), 39012, Italy

E-mail: [Andreacosentino2@gmail.com](mailto:Andreacosentino2@gmail.com)