



Severe Postoperative Hemorrhage following Primary Cheiloplasty in an Adult Patient: A case report

Jezmhyn Marie R Paelmo, Dindo P Retreta and Virgilio R De Gracia

Manila Doctors Hospital, Philippines

Abstract

Bleeding that requires re-operative hemostasis is a rare but serious complication after cheiloplasty. The goal of this paper is to present a case of an early postoperative bleeding from primary cheiloplasty in an adult patient and its management. This is a case of a 21-year old, male with a unilateral complete cleft lip and palate, with no known co-morbidities, who underwent primary cheiloplasty and rapid expanding hematoma on the upper lip on first postoperative day. The patient was brought back to the operating room for exploration and control of bleeders after conservative management was unable to control bleeding. There are several factors that may predispose to postoperative bleeding such as pre-operative planning, timing of surgery, surgical technique, surgeon's experience, post-operative care and monitoring. Prompt recognition of early signs of bleeding as well as timing and decision to re-operate is crucial for the final functional and aesthetic outcome for the patient.

Biography

Paelmo is a senior resident at the Department of Otorhinolaryngology – Head and Neck Surgery at manila doctors hospital, Philippines. Bulk of her patients who, have come from the provinces are suffering from late- stage head and neck tumors, unoperated cleft lip and palate in late childhood and adolescence, long-standing ear infections and rhinosinusitis. residency training have made her realize that better outcome would have been possible if only her patients were seen by a physician in the early stages of their disease / condition. After residency, she plans on practicing in the poorer areas of her country with limited to no access to healthcare.

IMAGES

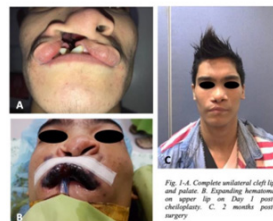


Fig. 1-A. Complete unilateral cleft lip and palate. B. Expanding hematoma on upper lip on Day 1 post-cheiloplasty. C. 2 months post-surgery

References

- Adesina, O. A., Efunkoya, A. A., Omeje, K. U., & Idon, P. I. (2016). Postoperative complications from primary repair of cleft lip and palate in a semi-urban Nigerian teaching hospital. *Nigerian medical journal: journal of the Nigeria Medical Association*, 57(3), 155–159.
<https://doi.org/10.4103/0300-1652.184059>
- Aziz, S.R., Rhee, S.T., & Redai, I. (2009). Cleft Surgery in Rural Bangladesh: Reflections and Experiences. *Journal of Oral Maxillofacial Surgery* 67:1581-1588
- DeMey, A., Vadoud-Seyedi, J., Demol, F. & Govaerts, M. (1997) Early postoperative complications in primary cleft lip and palate surgery. *European Journal of Plastic Surgery* 20:77-79
- Murphy, J. (2009). Management of cleft lip and palate in adults. *Indian Journal of Plastic Surgery Supplement* 1 2009 Vol 42
- Padwa, B.L., & Mulliken, J.B. (2003). Complications associated with cleft lip and palate repair. *Oral and Maxillofacial Surgery Clinics*, 15: 285-296
- Park, E., Gaurav, D., Schonmeyr, B., Retropo C., & Campbell, A. (2019). Optimizing Outcomes in Cleft Surgery. *IntechOpen*. <http://dx.doi.org/10.5772/intechopen.89882>
- Schonmeyr, B., Wendby, L. & Campbell, A. (2015). Early surgical complications after primary cleft lip repair: A report of 3108 consecutive cases. *The Cleft Palate-Craniofacial Journal* 52(6) pp. 706-710.

11th International Conference on Otorhinolaryngology and ENT Surgery
 Webinar | February 09, 2022

Citation: Jezmhyn Marie R Paelmo et al., *Severe Postoperative Hemorrhage following Primary Cheiloplasty in an Adult Patient: A case report*, *Otorhinolaryngology* 2022, 11th International Conference on Otorhinolaryngology and ENT Surgery | February 09, 2022