

Pediatric pulmonary actinomycosis: Case report and review of literature.

Albar Rawia F¹, Alqurashi Mansour A², Alfaidi Ahmed M³, Alesa Abdullah A³, Fatani Abrar N³

¹Assistant Professor, Consultant General Pediatrics and Pediatric Pulmonology, Section Head of General Pediatrics, KAMC, KSAU-HS, Jeddah, Saudi Arabia.

²Section Head and Consultant Neonatologist, Department of General Pediatrics, KAMC, Jeddah, Saudi Arabia.

³Department of General Pediatrics, Ministry of National Guard – Health Affairs, King Abdulaziz Medical City, Westren Region, Jeddah, Kingdom of Saudi Arabia.

Abstract

Pulmonary actinomycosis is a rare infection that usually needs biopsy confirmation to be diagnosed. They usually present with chest wall mass or with chest pain. Upon investigation, many have worrisome imaging results that usually represent a mass with some periosteal destruction. Patients can fully recover from this infection if the appropriate treatment was not delayed. A 12 years old boy presents to our department with a one month history of chest wall mass and one week of chest pain that showed great improvement after less than two months of antibiotic treatment.

Keywords: Actinomycosis, Pulmonary, Chest wall mass.

Accepted October 20, 2016

Introduction

Pulmonary actinomycosis is a rare infection in infants and children. Because of its non-specific clinical presentation, it can be confused with suppurative lung diseases or lung tumors. Actinomyces species are gram positive anaerobic bacilli, and of its many species, *Actinomyces israelii* is the most commonly reported. Most common anatomical sites of actinomyces infection are cervicofacial, thoracic and abdominal [1]. Here we report a case of a 12 year old Saudi boy with a chest wall mass that was biopsy proven to be caused by actinomyces. The patient presented electively to outpatient clinics and was admitted to our hospital for further workup. Aside from our case, a literature review of 35 cases of pediatric pulmonary actinomycosis was made.

Case Report

A 12 year old Saudi boy known case of partially controlled bronchial asthma, on Salbutamol, Fluticasone and Montelukast. The patient presented to outpatient clinic with one month history of a chest wall mass. Initially, it was painless, until one week prior to presentation, it started increasing in size and became erythematous, tender and warm, with the pain increasing with deep inspiration. There was no history of fever, cough, shortness of breath, night sweats, weight loss or any other swelling.

Examination revealed an afebrile, thin oriented child. His height was on 25th centile and weight below 5th centile. His oxygen saturation was 99% on room air; respiratory rate was 24/min, pulse of 104/min and blood pressure of

106/69 mm Hg. There was no spontaneous cough but he had poor oral hygiene. His chest examination showed a red, hot, tender and fluctuating right anterior non mobile chest wall mass measuring 4 × 10 cm (Figure 1) with no active discharge. On auscultation, there was decreased air entry on the right side with fine crepitations. The remainder of his examination was unremarkable.

Investigations revealed hemoglobin level of 10.8 g/dL with a normal mean corpuscular volume and mean corpuscular hemoglobin. Leukocytes: $10.8 \times 10^9/L$ with neutrophils: $7.08 \times 10^9/L$, lymphocytes: $2.63 \times 10^9/L$, platelets: $577 \times 10^9/L$, and C-Reactive Protein (CRP): 147 mg/L. Purified protein derivative skin test and gastric aspiration were both negative. Pulmonary function test was consistent

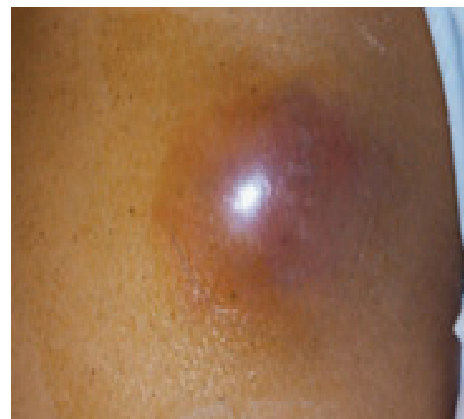

Figure 1. Chest examination

with a restrictive pattern with vital capacity (VC) of 0.93 L (54% of predicted) and forced expiratory volume 1 (FEV1) of 0.91 L (61% of predicted) and FEV1/VC of 98%. A chest radiograph (Figure 2) was obtained and showed hyperinflation with right lung consolidation and pleural effusion. Computed Tomography (CT) scan with contrast was performed and showed (Figures 3 and 4) a right soft tissue mass in mid chest wall, measuring 10.3 × 3 cm involving lung parenchyma and pleural surface associated with periosteal reaction and destruction of the 5th, 6th and 7th rib.

Excisional biopsy and abscess drainage were performed with no complications and the patient was started on intravenous (IV) Augmentin. The pathology report revealed, after 4 days of performing the biopsy, the presence of acute and chronic inflammation and necrosis. The biopsy was negative for malignancy and tuberculosis, but positive for actinomyces species.

Ceftriaxone IV was started on a dose of 90 mg/kg/day for a total of 30 days, to be received as an out on pass patient. During that time he was vitally stable and improving symptomatically. It was noticed that an itchy papular rash started to appear at the site of dressing and then involved the right upper limb, which resolved with anti-histamine treatment. The patient was started on oral Amoxicillin 500 mg three times per day for six weeks, with a follow up appointment after three weeks.

After three weeks of oral Amoxicillin, chest X-ray and

CT (Figures 5 and 6) were done and showed significant decrease in size and opacity of the previously described actinomycosis of right lung and right chest wall, with a minimal residual pleural effusion and reaction around the involved ribs.

Discussion

Our review (Table 1) consisted of 35 cases of pulmonary actinomycosis in patients aging 18 years and younger, gathered by using the Pubmed database. The first case was in 1958 and the last one in 2013. The average age was 9.5 years, ranging from 27 months to 16 years (17 male,

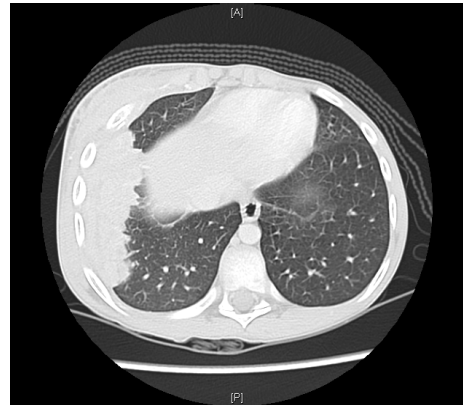

Figure 4. Computed tomography (CT) scan that shows periosteal reaction and destruction

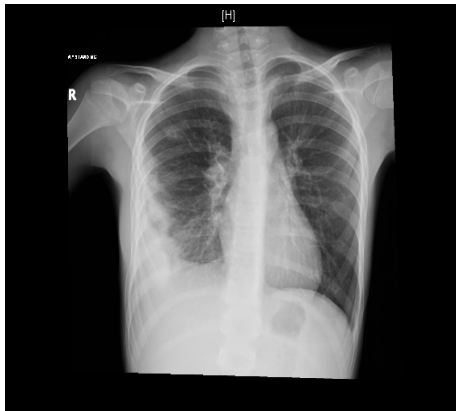

Figure 2. Chest radiograph

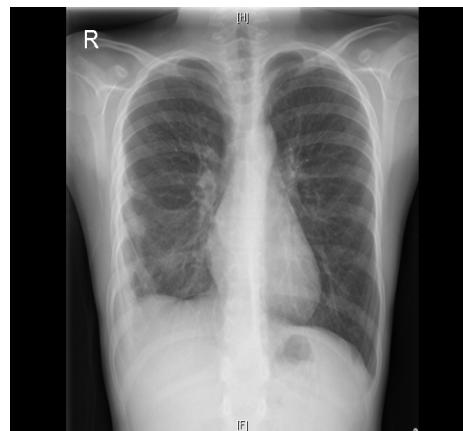


Figure 5. Chest X-ray

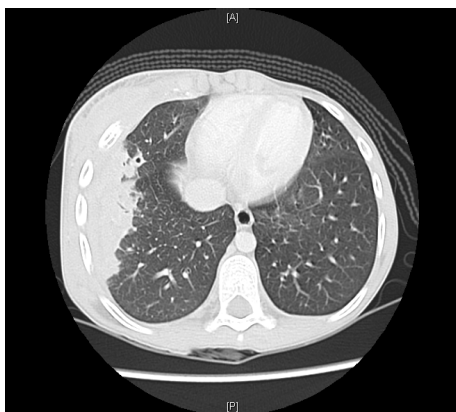

Figure 3. Computed tomography (CT) scan with contrast shows lung parenchyma

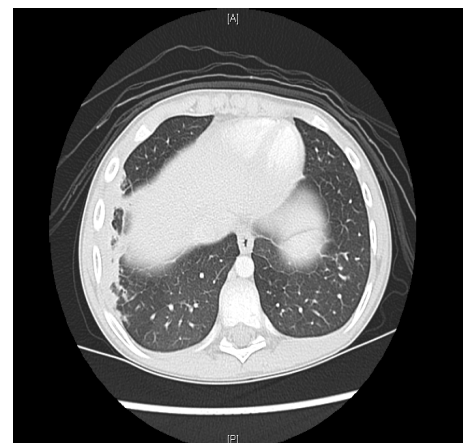


Figure 6. Chest CT with a minimal residual pleural effusion

18 female). The most common presenting complaint was the same as the presenting complaint of our case, which was chest wall mass (49%). Then cough and fatigue (43%) followed, although our case did not have either one

of these symptoms. followed by chest pain (37%) as the third most common manifestation. There were 3 cases that developed active discharge through draining sinus tracts, and only one case with positive history of chest trauma

Table 1. Pediatric pulmonary actinomycosis cases

	Authors	Ref/Gender/ Age	Chest Wall Mass	Cough	Fatigue	Chest Pain	Weight Loss	Pre-Treatment Imaging
1	Weese WC	2/M/10	-	+	+	+	+	Not mentioned
2	Weese WC	2/M/5	-	-	-	+	-	Not mentioned
3	Drake DP	3/F/3	-	-	-	-	-	Not mentioned
4	Drake DP	3/F/5	-	-	-	-	-	Not mentioned
5	Drake DP	3/M/7	+	-	-	+	-	Clear
6	A.J. Thompson	4/M/15	+	-	+	-	+	X-ray: consolidation, periostitis of ribs
7	A.J. Thompson	4/F/11	+	-	+	+	-	X-ray: consolidation, periostitis of ribs
8	A.J. Thompson	4/F/7	+	-	-	-	-	X-ray: collapse, consolidation with a mass
9	Lowe RN	5/M/14	-	+	+	-	-	X-ray: pleural thickening, bilateral alveolar and interstitial infiltrates
10	Webb WR	6/F/7	-	-	+	-	-	X-ray: density. CT: mass, periostitis. Bone radiography: rib destruction
11	Golden N	7/M/14	+	+	-	-	-	X-ray: pleural thickening. CT: infiltration of lung parenchyma, periosteal reaction, soft tissue mass.
12	Hsieh MJ	8/F/16	+	-	-	-	-	Not mentioned
13	Hsieh MJ	8/F/8	-	+	-	-	-	Not mentioned
14	Hsieh MJ	8/M/8	-	-	-	-	-	Not mentioned
15	Hsieh MJ	8/M/7	+	-	-	+	-	Not mentioned
16	Hsieh MJ	8/M/8	+	-	-	+	-	Not mentioned
17	Denton 3rd AE	9/M/11	+	+	+	-	+	CT: infiltrate, pleural effusion, periostitis of ribs, chest wall mass
18	MASTERS B	10/F/9	-	+	+	+	+	X-ray: bilateral collapse, consolidation of both lower lobes.
19	Dobson SR	11/F/10	+	-	-	-	-	X-ray: consolidation, pleural effusion. CT: abscess
20	Ray MS	12/M/12	-	+	+	-	+	X-ray: consolidation, periostial new bone formation on ribs.
21	Hachitanda Y	13/M/11	+	-	+	-	-	CT: mass involving chest wall and ribs
22	Wilson DC	14/M/10	+	-	+	+	+	X-ray: chronic consolidation, pleural effusion, rib periostitis
23	Snape PS	15/F/10	+	+	-	+	+	X-Ray: pneumonic infiltrate CT: probable inflammatory lesion extending through the chest wall
24	Wu CY	16/F/10	+	+	-	-	+	X-ray: multiple nodules. CT: variable sized nodules, soft tissue mass.
25	Goussard P	17/M/5	-	+	-	-	+	X-ray: consolidation
26	Kordes U	18/M/9	-	+	+	-	+	X-ray: consolidation, pleural effusion.

27	Pinarli FG	19/F/9	-	-	+	+	-	X-ray: consolidation, CT: soft tissue mass
28	Ganesan K	20/F/9	-	+	+	+	-	X-ray: periosteal new bone formation. CT, MRI and Bone scan: suggest neuroblastoma or small cell carcinoma
29	Celebi S	21/F/11	-	-	-	-	-	CT: solitary lesion, Scintigraphy: increased uptake in ribs
30	Bartlett AH	22/F/2	+	-	-	-	-	X-ray: pleural effusion. MRI: chest wall mass, infiltration of pleura, diaphragm, liver and chest wall
31	Lee JK	23/F/12	-	+	-	-	+	X-ray: pneumonic lesions. Sinogram: extension into subcutaneous tissues. CT: consolidation, pleural effusion.
32	Barikbin P	24/M/11	+	-	+	-	+	X-ray, CT: mass infiltrating chest wall. MRI: infiltration of pericardium, intercostal and pectoral muscles, atelectasis.
33	Yeung VH	25/M/12	+	+	-	-	+	X-ray consolidation, collapse. CT: chest wall tumor, pleural infiltration, rib erosion, lymph node metastases.
34	Lin CH	26/F/10	-	-	-	+	-	X-ray: consolidation CT: soft tissue mass, atelectasis of adjacent lung
35	Briceño G	27/F/14	-	+	-	+	+	CT: solid pulmonary mass with extension into the chest wall.

Ref: Reference Number; M: Male; F: Female; Age: In years; MRI: Magnetic Resonance Imaging; CT: Computed Tomography

as a risk factor for infection [2]. Regarding the laboratory investigations, there were 10 cases that did not mention any lab work. However, the most common laboratory finding was leukocytosis, which occurred in 56% of cases, then elevated erythrocyte sedimentation rate (ESR) in 52%, followed by CRP elevation in 40%. On the other hand, we did not order ESR level in our case, and the WBC count was normal. For the imaging reports, there were nine cases that did not mention any imaging modality report. As for the remaining 26 cases, the most common radiological findings were consolidation with periostitis in 50%, followed by pleural effusion in 35%. Both findings were present in our case in addition to hyperinflation of the right lung. Regarding the microscopy report, sulphur granules were seen in 19 cases (58%) and branching filaments were seen in 16 (49%). There were 7 cases that required surgical intervention, mainly due to suspicion of malignancy. There were only three cases that did not use penicillin derivatives, and one case did not mention the specific antibiotic. However, as we did with our patient, the remaining 31 cases (91%) used penicillin derivatives.

Pulmonary actinomycosis is not commonly encountered by pediatric physicians in Saudi Arabia. However, there are no epidemiological studies estimating the prevalence of this condition in our country. Most of the cases reported worldwide were caused by *Actinomycosis israelii*, which is a part of the normal flora of the mouth, and accordingly

it is usually linked to poor oral hygiene. Pulmonary actinomycosis can range from asymptomatic disease to a fatal one. Because of its nonspecific findings in radiological imaging, it might simulate many other disorders including pneumonia, tuberculosis, cryptococcosis, histoplasmosis, or malignancy. As for the microscopy, sulfur granules with branching filaments are considered pathognomonic, although the specimen may not contain an area that has this typical appearance. Penicillin remains the drug of choice for actinomyces, unless contraindicated, then other alternatives might be used, such as cephalosporins and macrolides. Surgery is usually performed to rule out malignancy, but it might also be required to manage some complications, such as, empyema, sinus discharge or hemoptysis [1-10].

In conclusion, pulmonary actinomycosis is considered rare in the pediatric age group, but should always be in the differential diagnosis when dealing with a lung mass lesion involving the chest wall. Usually, histopathology remains the definitive diagnosis method, but other investigations and imaging modalities help narrow the differential diagnosis and monitor response to therapy [11-23]. Treatment of pulmonary actinomycosis consists of long term IV antibiotic followed by oral antibiotic therapy. Primarily, penicillin is considered the drug of choice, unless contraindicated. With proper antibiotic treatment the prognosis is good [24-27].

References

- American Academy of Pediatrics. Summary of infectious diseases. In: Pickering LK, Baker CJ, Long SS, McMillan JA, eds. Red Book: 2006 Report of the Committee on Infectious Diseases. 27th ed. Elk Grove Village, IL: American Academy of Pediatrics 2006. 201-202.
- Weese WC, Smith IM. A study of 57 cases of actinomycosis over a 36 year period: A diagnostic failure with good prognosis after treatment. Archives of internal medicine 1975; 135: 1562-1568.
- Drake DP, Holt RJ. Childhood actinomycosis. Report of 3 recent cases. Archives of disease in childhood 1976; 51: 979-981.
- Thompson AJ, Carty H. Pulmonary actinomycosis in children. Pediatric radiology 1979; 8: 7-9.
- Lowe RN, Azimi PH, McQuitty J. Acid-fast actinomyces in a child with pulmonary actinomycosis. Journal of clinical microbiology 1980; 12: 124-126.
- Webb WR, Sagel SS. Actinomycosis involving the chest wall: CT findings. American Journal of Roentgenology 1982; 139: 1007-1009.
- Golden N, Cohen H, Weissbrot J, et al. Thoracic actinomycosis in childhood. Clinical pediatrics 1985; 24: 646-650.
- Hsieh MJ, Liu HP, Chang JP, et al. Thoracic actinomycosis. Chest 1993; 104: 366-370.
- Denton 3rd AE. Computed tomography findings in thoracic and renal actinomycosis: Case report and review of literature. The Journal of the American Osteopathic Association. 1985; 85: 23-26.
- Masters B, Phelan PD, Auldish AW. Pulmonary actinomyces in a child. Journal of Paediatrics and Child Health 1985; 21: 129-130.
- Dobson SR, Edwards MS. Extensive Actinomyces naeslundii infection in a child. Journal of Clinical Microbiology. 1987; 25: 1327-1329.
- Ray MS, Feldman S. Mixed fusobacterium and actinomyces pulmonary infection case report. Clinical Pediatrics 1989; 28: 426-428.
- Hachitanda Y, Nakagawara A, Ikeda K. An unusual anterior chest wall tumor due to actinomycosis in a child. Pediatric Radiology 1989; 20: 96.
- Wilson DC, Redmond AO. An unusual cause of thoracic mass. Archives of Disease in Childhood 1990; 65: 991-992.
- Snape PS. Thoracic actinomycosis: An unusual childhood infection. Southern Medical Journal. 1993; 86: 222-224.
- Wu CY, Li YW. Multifocal thoracic actinomycosis simulating lymphoma. Pediatric Radiology 1993; 23: 541-542.
- Goussard P, Gie R, Kling S, et al. Thoracic actinomycosis mimicking primary tuberculosis. The Pediatric Infectious Disease Journal 1999; 18: 473-475.
- Kordes U, Beutel K, Cachovan G, et al. Gingivitis as probable source of a thoracic actinomycosis due to *Actinomyces israelii* and *Actinobacillus actinomycetemcomitans*. Archives of Disease in Childhood 2004; 89: 895.
- Pinarli FG, Mutlu B, Çelenk Ç, et al. Pulmonary actinomycosis mimicking chest wall tumor in a child. Jpn J Infect Dis 2005; 58: 247-249.
- Ganesan K, Khan R, Eisenhut M. Pulmonary actinomycosis masquerading as a malignant lung tumor in a 9 year old boy. Clinical Pediatrics 2005; 44: 181.
- Celebi S, Sevinir B, Saraydaroglu O, et al. Pulmonary actinomycosis. The Indian Journal of Pediatrics 2009; 76: 236-238.
- Bartlett AH, Rivera AL, Krishnamurthy R, et al. Thoracic actinomycosis in children: Case report and review of the literature. The Pediatric Infectious Disease Journal 2008; 27: 165-169.
- Lee JK. Pulmonary actinomycosis and skin sinuses. Journal of Paediatrics and Child Health. 2007 Dec 1; 43: 854-855.
- Barikbin P, Grosser K, Hahn G, et al. Thoracic actinomycosis imitating a malignant chest wall tumor. Diagnosis: pulmonary actinomycosis. Journal of Pediatric Hematology/Oncology 2007; 29: 345-346.
- Yeung VH, Wong QH, Chao NS, et al. Thoracic actinomycosis in an adolescent mimicking chest wall tumor or pulmonary tuberculosis. Pediatric Surgery International 2008; 24: 751-754.
- Lin CH, Lin WC, Ho YJ, et al. Pulmonary actinomycosis with remote lower chest wall involvement in an immunocompetent child. Pediatrics International 2010; 52: 129-131.
- Briceño G, Guzman P, Schafer F. Cutaneous fistula due to pulmonary actinomycosis in a mapuche girl. Pediatric Dermatology 2013; 30: 504-505.

Correspondence to:

Ahmed Mohammed Alfaidi,
 Department of General Pediatrics,
 Ministry of National Guard – Health Affairs,
 King Abdulaziz Medical City,
 Westren Region, Jeddah,
 Kingdom of Saudi Arabia.
 Tel: +966506028863
 E-mail: Ahmed.al.faidi@gmail.com

Special issue: Pediatric Research

Editor: Abdulla A Alharthi, Department of pediatric nephrology, Taif University, Saudi Arabia