

Management of Disciform keratitis with Ayurvedic ocular therapeutics: A case report.

Veena Shekar*, Sujathamma K, Hamsaveni V

Department of PG Studies, Shalakya Tantra (Ophthalmology and Otolaryngology), Sri Kalabhyraveswara Swamy Ayurvedic Medical College Hospital and Research Centre Bengaluru, Karnataka, India

Abstract

The purpose of this study is to report a rare case of Disciform keratitis in a 75 years old healthy female, who had presented with 2 days of redness, pain and blurred vision in the right eye. Diagnosis was made based on slit lamp examination which revealed central stromal oedema with descemet's folds in the right cornea. A rapid response to Ayurvedic ocular therapeutics (kriyakalpas) consisting of bidalaka (application of medicated paste over the closed eyelids), pindi (application of medicated paste enclosed in a fabric material) and aschyotana (eye drops) was observed within 1 week of treatment. There was no recurrence in 6 months of follow-up. A total resolution of keratitis occurred within a short period of time with an effective Ayurvedic management.

Keywords: Stromal oedema, Descemet's folds, Disciform keratitis, Ayurvedic ocular therapeutics, Kriya kalpas, Bidalaka, Pindi, Aschyotana

Accepted on 07 January, 2019

Introduction

Disciform keratitis is a recurrent viral keratitis, most commonly associated with herpes simplex virus (type 1) and is typically unilateral. Traditionally disciform keratitis has been described under stromal keratitis. However the recent trend is to describe it under endothelitis as the actual mechanism involved is thought to be endothelial cell infection by herpes simplex virus and associated inflammation [1]. A primary ocular infection commonly manifests as blepharoconjunctivitis which is usually self-limiting. The virus then establishes latent infection in trigeminal ganglion, periodically reactivates leading to recurrent infection at any time proceeding from it [1-4].

Delayed hypersensitivity mediated by T lymphocytes is probably important in the pathogenesis of disciform keratitis. It may be preceded by dendritic ulceration [1]. Symptoms include blurred vision of gradual onset, which may be associated with haloes around lights, discomfort and redness. Signs include a central zone of stromal oedema often with overlying epithelial oedema, large keratic precipitates underlying the oedema, folds in descemet's membrane, a surrounding immune ring of deep stromal haze signifies deposition of viral antigen and host antibody complexes, reduced corneal sensation. Intraocular pressure may be elevated [2].

Progression to necrotising keratitis, vascularisation, scarring and thinning is also possible [1]. Diagnosis is usually done by its clinical presentation on the slit lamp examination. Recurrence can still occur, despite treatment with antiviral drugs. Reactivation is attributed to stress, trauma and ultraviolet radiation. Corneal scarring leading to blindness is an indication for corneal transplantation however transplantation is complicated by increased risk of graft rejection in patients with herpes simplex Keratitis [3]. Herein, we report a case of disciform keratitis with presumed herpes simplex virus etiology

which was successfully managed with Ayurvedic ocular therapeutics.

Case Report

A 75 years old healthy female presented to our OPD with 2 days of right eye pain (ocular discomfort) and redness. She also reported blurred vision in the right eye. Patient had used over the counter eye drops for the same problem for 2 days without any relief. Patient's past medical history was insignificant and she was not on any medications. She didn't report any ocular lesions before. On presentation, her best corrected visual acuity was 6/36 and 6/9 in the right and left eye respectively.

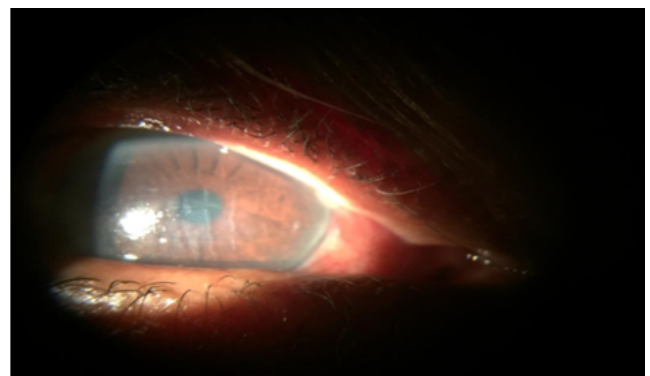


Figure 1. Right eye: At presentation: Diffuse conjunctival injection, central stromal oedema and descemet's folds.

The pupils were equal, round and reactive to light with no afferent pupillary defect. Slit lamp examination of the anterior segment of right eye revealed no vesicles on the eyelids, diffuse conjunctival congestion, central stromal haze with descemet's folds in the cornea (Figure 1), no epithelial defect on fluorescein staining, no keratic precipitates, no cells in the anterior chamber. Corneal sensitivity was diminished

subjectively in the right eye more than the left eye. The left eye had an unremarkable anterior segment.

The dilated posterior segment examination demonstrated grade II nuclear sclerosis and normal fundus in both the eyes. IOP recorded with applanation tonometry was 13 mmHg and 14 mmhg in right and left eye respectively. The case was primarily diagnosed as disciform keratitis in the right eye which was confirmed after taking an opinion from the consulting corneal specialist. Aim of the treatment was to prevent further progression of inflammatory process, to resolve corneal oedema and to prevent its permanent scarring.

Table 1. Treatment given.

S.No	Ocular therapeutics	Drugs used	Duration
1	Bidalaka (topical application)	Triphala (Terminalia chebula, Terminalia bellerica, Emblica officinalis), Yashtimadhu (glycyrriza glabra) Lodhra (Symplocus racemosus)	20 min once a day for 7 days
2	Pindi (topical application)	Kumari (Aloe barbadensis)	2 hours once a day for 7 days
3	Aschyotana (eye drops)	Mahatriphaladi ghrita Ophthacare drops	2 drops once a day for 7 days 6 times a day for 7 days

After 4 days of treatment, there was significant reduction in all the signs and symptoms. Slit lamp examination of anterior segment of right eye revealed clear conjunctiva and complete resolution of corneal oedema and descemet's folds (Figure 2).

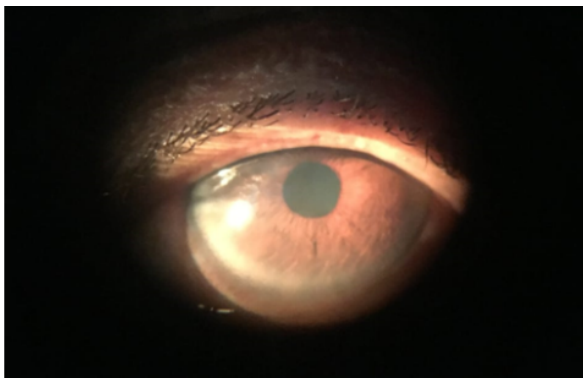


Figure 2. On 5th day of treatment: Clear conjunctiva, resolved corneal oedema and descemet's folds.

Best corrected visual acuity in the right eye was 6/9. Corneal sensation was normal. Patient was asked to continue ophthacare drops for one more week and come for follow up one month after cessation of drops. The best corrected visual acuity was 6/9 in the right eye and there were no signs and symptoms recorded in the first follow up (Figure 3). The case was followed every month up to 6 months.

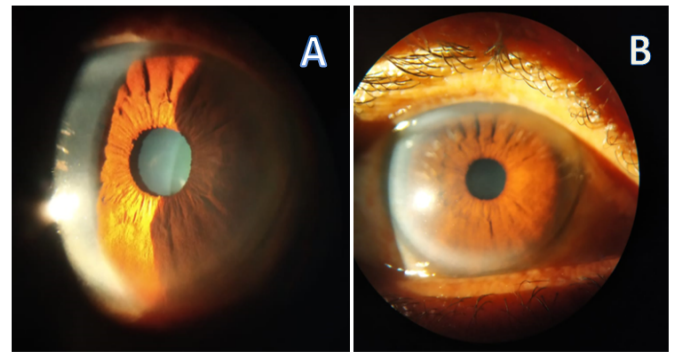


Figure 3. 1st follow up: One month following cessation of treatment: clear conjunctiva and cornea.

There was no recurrence of signs and symptoms and no peripheral vascularization of the cornea was seen in the follow up (Figure 4).

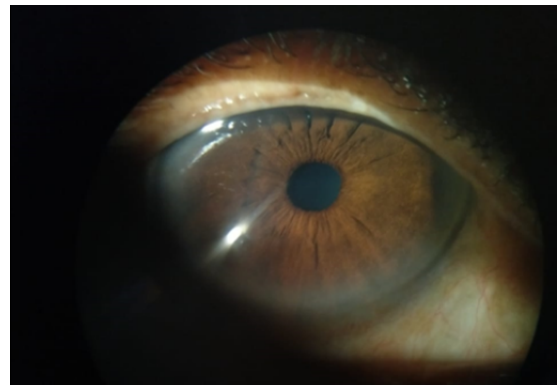


Figure 4. 6 months following cessation of treatment: clear cornea, no vascularization.

Discussion

Based on the clinical presentation and diminished corneal sensitivity of right eye, the diagnosis made in the present case was Disciform Keratitis with presumed herpes simplex virus etiology. Disciform Keratitis caused by Varicella zoster virus has similar features, but it is always preceded by nummular keratitis [4] and the patient gave only 2 days history of ocular discomfort. Primary infection was assumed to be subclinical as we could not elicit any skin, mucous membrane or ocular lesions from the past history. Predisposing stress stimulus found in the present case was emotional stress which is also mentioned in Ayurvedic classics under the etiology of eye diseases [5].

Disciform keratitis resembles Avranashukra, one of the corneal diseases mentioned in Ayurvedic classics, which develops from conjunctivitis (abhishtyanda) due to the derangement of blood (rakta). Its clinical features include appearance of white spot in the cornea (Krishna mandala) which is not associated with excessive pain or lacrimation. It is easily manageable if it does not involve two layers and if it is not long standing [5].

Pathogenesis and management as per Ayurveda

Emotional factors may derange digestive enzymes (jataragni) leading to improper digestion, which in turn alters metabolism. This results in the derangement of doshas (basic constitutional elements of the human body which under normal conditions bring about normal physiological functions and lead to pathology when aggravated), which then move upwards through channels of circulation (siras) and get localized in susceptible ocular tissues. When such eyes come in contact with external etiological factors (infectious agents), there occurs derangement of blood, which results in increased permeability of blood vessels (srotosyanda), leading to the disease abhishyanda. If these doshas are not eliminated properly by suitable treatment, they may become violent again, on exposure to predisposing factors and afflict different layers of cornea by further deranging rakta to cause Avranashukra.

Its management includes adopting abhishyanda line of treatment initially, [5] therefore the topical ocular therapeutics (kriyakalpas) were administered with various drug formulations, the pharmacological properties of which help to pacify the derangement of doshas and bring about normalcy of ocular tissues. Drugs which are bitter (tikta) and pungent (katu) in taste (rasa) viz triphala, *eclipta alba*, *tinospora cordifolia* etc. activate metabolic enzymes, digest metabolic byproducts or free radicals (dhatwagnimandyajanya ama) and pacify kapha dosha. Drugs which possess sweet taste (madhura rasa) viz *Glycyrrhiza glabra*, *Vitis vinifera* etc. and bitter taste viz *Aloe barbadensis*, *Symplocos racemosus* etc. being cold in potency (sheeta veerya) pacify pitta and rakta and reduce the inflammation (shotha). The drugs are conducive to health of ocular tissues, a specific action designated as chakshushya. The drugs used in the therapeutics also possess antiviral, anti-oxidant and anti-inflammatory properties (Table 1).

Bidalaka

It includes application of medicated paste over the external surface of eyelids excluding the eye lashes. Medicated paste prepared out of equal quantities of fine powders of Triphala, *Glycyrrhiza glabra* and *Symplocos racemosa* of the thickness of 0.5 cm approximately, was applied as bidalaka. According to Ayurveda, active fractions of the topically applied medicine undergo transformation by the heat (bhrajaka pitta) present in the skin and will be absorbed into systemic circulation through the vessels connected to the hair follicles [6].

HPLC analysis reveals that the most commonly occurring polyphenolic compounds in Triphala are phenolic acids (mainly gallic acid), flavonoids and tannins which possess antiviral, antioxidant and anti-inflammatory activities. [7] chebulagic acid (CHLA) and punicalagin (PUG), hydrolyzable tannins isolated from the fruits of Terminalia chebula targeted and inactivated HSV-1 viral particles [8]. 1,2,4,6-tetra-O-galloyl- β -D-glucose (1246TGG), a polyphenolic compound isolated from *Phyllanthus emblica* was found to inhibit Herpes simplex virus type 1 and type 2 infection [9]. Vitamin C present in *Phyllanthus emblica* is a potent antioxidant and possesses anti HSV activity. [10] Licorice contains two

triterpenoids, GL16, 17 (Glycyrrhizin) and GA18 (Glycyrrhetic acid) responsible for the antiviral activity. Glycyrrhizin component of licorice reduces adhesion force and stress between CCEC (cerebral capillary vessel endothelial cells) and PMN (polymorphonuclear leukocytes) in case of HSV infection and establishes a resistance state to HSV1 replication [11]. Flavonoids and tannins have been isolated from *Symplocos racemosa*.

Pindi

Drugs in the paste form are tied in a cotton cloth and kept over the closed eyes. Pulp of *Aloe barbadensis* used in pindi with its highly cooling nature reduces ocular discomfort. The anthraquinone aloin a phenolic compound present in the pulp of *aloe barbadensis* inactivates various enveloped viruses such as herpes simplex, varicella zoster and influenza. Beta carotene, vitamin C and E present in the pulp act as antioxidants. Gel extract contains anti-inflammatory compound C-glucosyl chromone [12].

Bidalaka and Pindi are nothing but the transdermal drug delivery methodologies adopted for drug delivery to ocular tissues through eye lid skin. Usage of material enclosed medicated paste in pindi, maintains the skin hydration for a longer duration and acts as a permeation enhancer. Bioavailability of the drug is enhanced as the contact time is increased. Eye lid serves as a potential site for drug delivery to conjunctiva and ocular tissues as it has a thinner stratum corneum which shows lower impedance to permeation of drug [13]. Drug molecules diffuse through stratum corneum and viable epidermis, enter microcirculation in dermis for systemic distribution. Hydration is the most important factor increasing the permeation of the skin [14]. Hydration present in Pindi and Bidalaka paste and factors which include rich vascularity of the eye lids, smaller molecules of the drugs and their adequate solubility in water and lipid make the penetration easier.

Aschyotana

It includes instillation of eye drops into the conjunctival sac from a height of 2 inches and is supposed to be the first line of treatment in all types of eye diseases.

Mahatriphaladya ghrita

It is a ghee based medicine prepared by boiling pastes and decoctions of medicinal herbs with cow's ghee and is indicated in all types of eye diseases [15]. Apart from triphala, anti HSV activities of *Tinospora cordifolia* [16], *Justicia adhatoda*, [17] *Vitis vinifera* [18] have been well documented. Due to the amphipathic nature of the medicated ghee, its active principles readily cross corneal epithelium and stroma to reach aqueous humor thereby reducing the inflammation in stroma and endothelium. High viscosity of the drug enhances its bioavailability by increasing the contact time and reduces ocular discomfort by providing lubrication to the ocular surface.

Herpes simplex type 1 infection induces oxidative stress [19]. Vitamin A and E present in the ghee, polyphenolic compounds present in the herbs act as antioxidants, reduce tissue damage caused due to oxidative stress. Vitamin E supplementation reduces the symptoms of HSV encephalitis [20]. Vitamin A maintains the integrity of the endothelium. *Eclipta Alba* extract, *Asperagus racemosus*, and piper longum possess anti-oxidant activities.

Ophthacare eye drops

A patent medicine, contains herb extracts in a purified honey base. Honey has a special quality of penetrating deeper tissues called as "yogavahi", therefore carries active components of the drugs to the target ocular tissues.

In addition to *emblica officinalis*, curcumin and its new derivatives of *Curcuma longa* [21]. Dichloromethane and methanol extracts of *Ocimum sanctum* [22] have shown anti HSV activity. Honey has anti HSV [23] and anti-oxidant activity. These drugs also possess anti-inflammatory activities. *Carum copticum*, *Terminalia belerica*, *Rosa damascene* and *Cinnamomum camphora* possess anti-oxidant activity.

Conclusion

Early treatment and anti-viral properties of most of the drugs used in the treatment helped to resolve the Keratitis within a short duration in our patient. The result shows the significance of Ayurvedic ocular therapeutics in the effective management of Disciform Keratitis. To the best of our knowledge, there have been no prior published reports of Disciform keratitis managed with Ayurvedic therapeutics.

Conflicts of Interest

There are no conflicts of interests.

References

- Suresh PS, Tullo AB. Herpes simplex keratitis. *Indian J Ophthalmol.* 1999;47:155-65.
- Brad Bowling, Kanski's Clinical Ophthalmology: A Systematic Approach. 8th ed. Elsevier 2016;168-237.
- Azher TN, Yin XT, Tajfirouz D, et al. Herpes simplex keratitis: challenges in diagnosis and clinical management. *Clin Ophthalmol.* 2017;11:185-191.
- A.K Khurana. *Comprehensive Ophthalmology.* 7th Ed. Jaypee Brothers Medical Publishers (P) Limited. New Delhi, 2019;98-150.
- Sharma PV. *Susruta samhita with English translation of text and Dalhana's commentary.* Chaukhambha Visvabharati, Varanasi, India. 2010;3:105-175.
- Sharma PV. *Susruta Samhita with English translation of text and Dalhana's commentary.* first ed, Chaukhambha Visvabharati, Varanasi, India. 2000;2:206-22.
- Tarasiuk A, Mosinska P, Fichna J. *Triphala: current applications and new perspectives on the treatment of functional gastrointestinal disorders.* *Chin Med.* 2018;13:39.
- Lin LT, Chen TY, Chung CY, et al. Hydrolyzable Tannins (Chebulagic Acid and Punicalagin) Target Viral Glycoprotein- Glycosaminoglycan Interactions To Inhibit Herpes Simplex Virus 1 Entry and Cell-to-Cell Spread. *J Virol.* 2011;85:4386-98.
- Xiang Y, Pei Y, Qu C, et al. In vitro anti-herpes simplex virus activity of 1,2,4,6-tetra-O-galloyl- β -D-glucose from *Phyllanthus emblica* L. (Euphorbiaceae). *Phytother Res.* 2011;25:975-82.
- Lopez BS, Yamamoto M, Utsumi K, et al. A Clinical Pilot Study of Lignin-Ascorbic Acid Combination Treatment of Herpes Simplex Virus. *In Vivo.* 2009;23:1011-6.
- Wang L, Yang R, Yuan B, et al. The antiviral and antimicrobial activities of licorice, a widely-used Chinese herb. *Acta Pharm Sin B.* 2015;5:310-5.
- Sarjushe A, Vasani R, Saple DG. Aloe vera: A short review. *Indian J Dermatol.* 2008;53:163-6.
- See GL, Sagesaka A, Sugasawa S, et al. Eyelid skin as a potential site for drug delivery to conjunctiva and ocular tissues. *Int J Pharm.* 2017;533:198-205.
- Nikhil Sharma, Geta Agaerwal, Rana AC, et al. A Review: Transdermal Drug Delivery System: A Tool For Novel Drug Delivery System. *Int J Drug Dev & Res.* 2011;3:70-84.
- Rao GP. Bhaishajya Ratnavali of Kaviraj Shri Govind Das Sen (2014). edn 1 Chaukambha Orientalia, Varanasi Reprint, India. pp 467-504.
- Pritvish R, Gopinatha SM. Antiviral perspective of *tinospora cordifolia* on HSV-1. *Int J Curr Microbiol App Sci.* 2018;7:3617-24.
- Chavan R, Shah VV, Gohil DJ, et al. Anti-viral activity of Indian medicinal plant *Justicia Adhatoda* against herpes simplex virus: An In-Vitro study. *International Journal of Pharma and Bio Sciences.* 2013;4:769-78.
- Orhan DD, Orhan N, Ozcelik B, et al. Biological Screening of *Vitis vinifera* L. Leaf Fractions. *Turkish Journal of Biology.* 2009;33:341-8.
- Sebastiano M, Chastel O, de Thoisy B, et al. Oxidative stress favours herpes virus infection in vertebrates: a meta-analysis. *Curr Zool.* 2016;62:325-32.
- Sheridan PA, Beck MA. The Immune Response to Herpes Simplex Virus Encephalitis in Mice Is Modulated by Dietary Vitamin E. *J Nutr.* 2008;138:130-7.
- Zandi K, Ramedani E, Mohammadi K, et al. Evaluation of Antiviral Activities of Curcumin Derivatives against HSV-1 in Vero Cell Line. *Nat Prod Commun.* 2010;5:1935-8.
- Yucharoen R, Anuchapreeda S, Tragoolpua Y. Anti-herpes simplex virus activity of extracts from the culinary herbs *Ocimum sanctum* L., *Ocimum basilicum* L. and *Ocimum americanum* L. *Afr J Biotechnol.* 2011;10:860-6.
- Ghapanchi J, Moattari A, Tadbir AA, et Al. The In vitro anti-viral activity of honey on Type 1 Herpes Simplex virus. *Aust J Basic & Appl Sci.* 2011;5:849-52.

Citation: *Veena S,Sujathamma K,Hamsaveni V. Management of Disciform keratitis with Ayurvedic ocular therapeutics: A case report. J Clin Ophthalmol 2020;4(1):196-200.*

***Correspondence to**

Veena Shekar

Department of PG studies in Shalakya Tantra

Sri Kalabhyraveswaraswamy Ayurvedic medical

College Hospital and Research Centre

Bengaluru

Karnataka

India

E-mail: ven280005@gmail.com

Tel: +91 9242314631