

Importance of multi-disciplinary team approach in Feingold syndrome.

Tomoko Tanaka¹, Thomas W McEwan², Catharine J Harris³, Sarah S Barnett³, Arshad R Muzaffar², Dawn H Huber⁴, N Scott Litofsky¹

¹Divisions of Neurosurgery, University of Missouri School of Medicine, One Hospital Drive, Columbia, USA.

²Department of Plastic Surgery, University of Missouri School of Medicine, One Hospital Drive, Columbia, USA.

³Department of Genetics, University of Missouri School of Medicine, One Hospital Drive, Columbia, USA.

⁴Department of Health Psychology, University of Missouri School of Medicine, One Hospital Drive, Columbia, USA.

Abstract

Feingold Syndrome is an autosomal dominant genetic disorder with a variable phenotypic expression similar to VACTERL association. These two disorders can be confusing since both have clinical similarities included vertebral defects, anal atresia, cardiac defects, tracheoesophageal fistula with esophageal atresia, renal and limb abnormalities. Metopic craniosynostosis demonstrates a spectrum of severity including varying degrees of metopic ridging, bitemporal narrowing and trigonocephaly. Craniosynostosis may require surgical intervention to increase cranial volume and correct dysmorphism. We encountered a patient who was initially diagnosed with VACTERL association by the neonatal intensive care service without formal genetic consultation. The patient was then referred to plastic surgery for positional plagiocephaly with noted isolated metopic craniosynostosis. The multi-disciplinary craniofacial team (consisting of a craniofacial anomaly fellowship trained plastic surgeon, pediatric neurosurgery fellowship training neurosurgeon, pediatric neuropsychologist, medical geneticist, speech pathology, and developmental pediatrician) was involved in the patient's assessment and treatment process. Genetic evaluation was conducted and suggested the diagnosis of Feingold Syndrome which was confirmed on testing by c.964C>T nonsense mutation in MYCN with a normal chromosomal microarray. Neuropsychiatric testing demonstrated global delay. Pre-existent conditions of microcephaly and developmental delay are part of Feingold syndrome, therefore, the decision of surgical intervention for mild to moderate metopic craniosynostosis was quite complex. The team felt that metopic craniosynostosis may have contributed to poor head growth; therefore, the patient underwent cranio-vault reconstruction (CVR) and subsequently developed a cerebrospinal fluid leak four weeks after CVR. Conservative management failed and the patient required ventriculo-peritoneal shunting. To our knowledge, craniosynostosis has never been reported with Feingold syndrome. In rare cases such as this, a multi-disciplinary team approach is important for properly making a correct diagnosis and treatment decision.

Keywords: Craniosynostosis, Metopic, Feingold syndrome, VACTERL association.

Accepted July 21, 2016

Introduction

Feingold Syndrome is a rare Autosomal Dominant (AD) genetic disorder with variable phenotypic expression and complete penetrance [1,2]. The constellation of malformations seen in Feingold Syndrome has considerable overlap with VACTERL Association, (vertebral defects, anal atresia, cardiac defects, tracheoesophageal fistula with esophageal atresia, renal and limb abnormalities), but can be distinguished by the microcephaly, brachymesophalangy and toe syndactyly [3]. Feingold Syndrome is caused by a heterozygous

mutation in the MYCN proto-oncogene located on chromosome 2p24 [3,4]. MYCN belongs to the Myc family of proto-oncogenes, which are transcription factors important for the regulation of gene expression associated with a range of cellular processes, including proliferation, apoptosis, energy metabolism, and differentiation. MYCN is not ubiquitously expressed in that expression during embryogenesis is limited to pre-B cells, kidney, forebrain, hindbrain, and intestine, with highest expression in the developing brain [5]. Mutations in MYCN, which sequence variants and partial gene

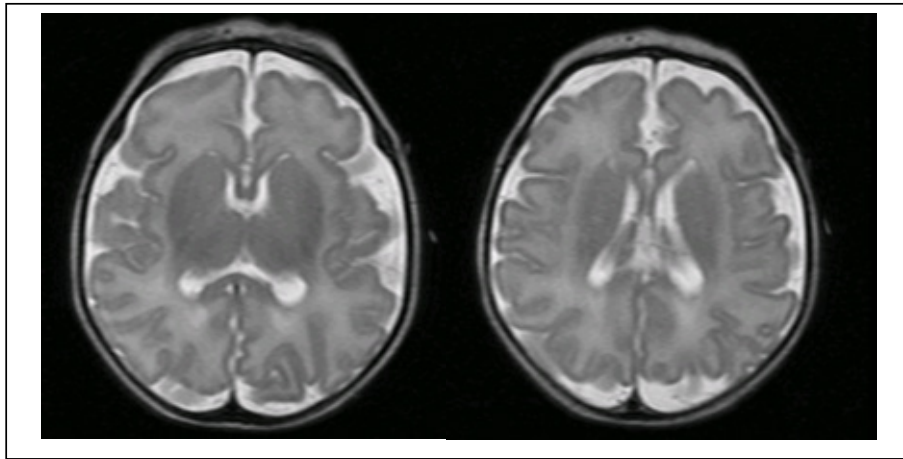


Figure 1. Brain MRI of age 6 weeks old demonstrated delayed myelination for age

deletions, are identified in 75% of patients clinically diagnosed with Feingold Syndrome [6,7].

Craniosynostosis, premature fusion of one or more cranial sutures, is a common craniofacial anomalies present in of 1 in 2,500 live births. Recently, incidence of metopic synostosis recently has increased [8]. The prevalence of metopic synostosis of 1 in 10,000-15,000 live births may be grossly underestimated due to unrecognized or insufficiently evaluated cases of trigonocephaly [9,10]. Most cases of metopic synostosis are believed to be spontaneous events without a clear underlying etiology; however, metopic synostosis can be induced by environmental factors such as valproate exposure in utero, neonatal hyperthyroidism, and intrauterine head constraint [11]. Additionally, monosomy 9p Syndrome, del 9p22p24 and Jacobsen Syndrome, del 11q23q24, have been associated with trigonocephaly [12].

We report a case of Feingold Syndrome, which presented with isolated metopic synostosis. The patient did not have an accurate diagnosis until evaluation by our craniofacial multi-disciplinary team.

Case Presentation

A male child was born by Cesarean section at 34 6/7 weeks gestation to a G2P2AB1 mother. The pregnancy was complicated by an ectopic twin terminated at 11 weeks. Shortly after birth, the patient was found to have a tracheoesophageal fistula with esophageal atresia and was transferred to our institution for pediatric surgery consultation. On the basis of evaluation by the neonatal intensive care service, additional diagnoses of microcephaly, absent sacral vertebrae, Grade II germinal matrix hemorrhage, hypertension, hypercalcuria, and bilateral hypoplastic kidneys were made, leading to a presumptive diagnosis of VACTERL association. Prior to discharge, brain MRI was obtained for further evaluation (Figure 1). There was no evidence of hydrocephalus, however, it demonstrated delayed myelination. No medical genetic evaluation was requested at that time.

At eight months of age, the patient was referred to

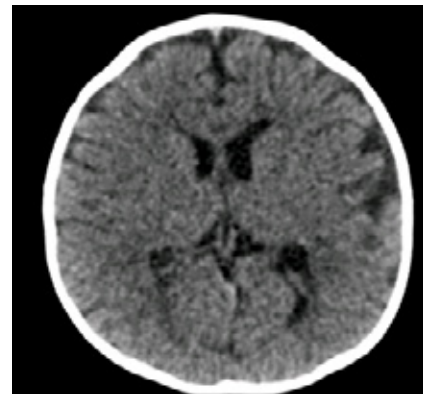


Figure 2a. Preoperative head CT demonstrated mild trigonocephaly without evidence of hydrocephalus

plastic surgery for deformational plagiocephaly. Physical examination revealed microcephaly (below the second percentile), a prominent metopic ridge, a small anterior fontanelle, pseudo-hypotelorism, a narrowed bitemporal distance, epicanthal folds, and bilateral “cup ear” deformities. Additionally the patient was noted to have bilateral Blauth Grade 1 thumb hypoplasia, clinodactyly of the 2nd and 5th fingers, and brachydactyly of the bilateral small fingers. Computed Tomography (CT) scan demonstrated metopic synostosis, a small anterior fontanelle, and mild trigonocephalic dysmorphology without enlarged ventricle (Figure 2a). Due to the multiple congenital anomalies, a medical genetics evaluation was requested. The genetic evaluation revealed a possible diagnosis of Feingold Syndrome. A chromosomal microarray showed normal 46,XY. Additional genetic testing confirmed the Feingold Syndrome diagnosis due to a nonsense mutation in the MYCN gene at position c.964C>T (p.Arg322X). Origin of mutation is unclear as family declined family studies. Neuropsychological testing revealed global delays (Table 1). Preoperative ophthalmologic evaluation showed no evidence of papilledema. Because of concerns that the craniosynostosis was aggravating the global developmental delay and microcephaly, CVR was performed at 12.5 months. A small durotomy was noted during surgery, which was primarily repaired. Post-operative head CT was

unremarkable. (Figure 2b) Four weeks post-operatively, the patient developed a CSF leak from the incision.

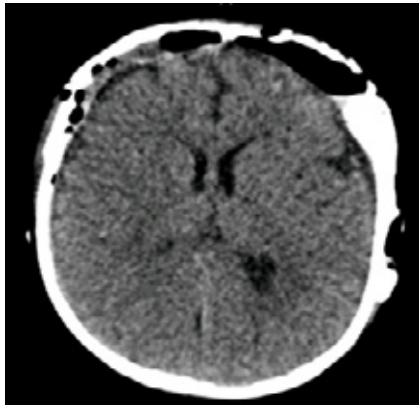


Figure 2b. Post CVR head CT demonstrated expansion of anterior skull base

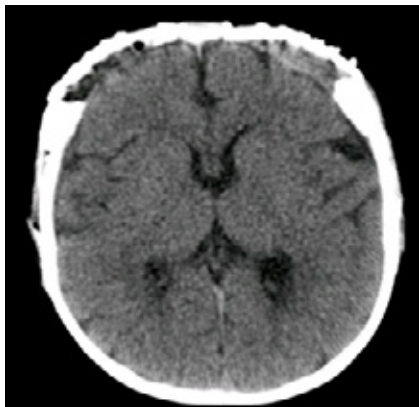


Figure 2c. Non-contrast CT at 4 weeks after CVR with CSF leak, no evidence of hydrocephalus. The ventricle slightly smaller compared to preoperative head CT

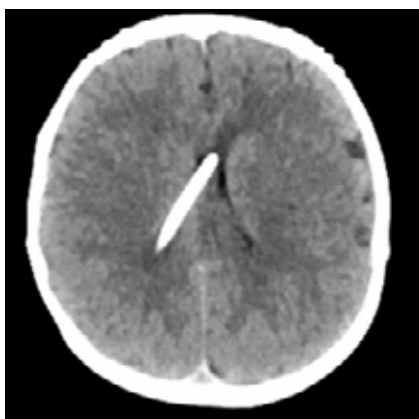


Figure 2d. Follow up head CT without contrast at age 4 demonstrated well decompressed ventricles with right occipital ventriculo-peritoneal shunt catheter

At that time the head CT noted the ventricular size was unchanged compared to the preoperative CT (Figure 2c). Treatment of the CSF leak failed to respond to lumbar drain management and subsequently required VPS placement at six weeks after CVR. The child is now almost five years old with some improvement in his global developmental delay. Following placement with a foster family, his cognitive function improved rapidly. However, follow-up neuropsychological testing demonstrated continued global impairment with some improvement. (Table 1) Significant microcephaly (Figure 3) remained. The patient continues to be followed by our multi-disciplinary craniofacial team. There is no current evidence of papilledema.

Discussion

Feingold Syndrome is very rare AD syndrome with similar clinical features to VACTERL association. Craniosynostosis of any cranial suture can be an isolated phenomenon or part of a syndrome. Currently there are over 180 syndromes associated with craniosynostosis, and these vary greatly in terms of identified genes and clinical presentation [8]. To our knowledge, craniosynostosis has not been previously reported concomitantly with Feingold Syndrome. One child with Feingold syndrome was previously reported to have a “prominent metopic suture,” but no further details on whether the child had an isolated metopic ridge or other evidence of metopic synostosis were provided [4]. It should be also noted that craniosynostosis has been reported in conditions with similar phenotypes as Feingold syndrome, specifically Baller-Gerold syndrome (OMIM #218600) and Fanconi’s anemia [13-15]. Interestingly, despite several large retrospective studies specifically attempting to identify additional congenital anomalies that present in children with VATER/VACTERL Association, it appears that craniosynostosis and VACTERL Association have not been reported in the same individual [16,17].

Despite this fact, craniosynostosis has been seen in conditions phenotypically similar to Feingold Syndrome, we feel it is important to note that craniosynostosis and Feingold syndrome can co-exist. The authors recognize the fact that the presence of both craniosynostosis and Feingold Syndrome in this child is possibly due to pure chance, especially given the fact that craniosynostosis is relatively common. With that said, Feingold syndrome is a rare condition that has not been exhaustively studied; and therefore, we cannot be certain that craniosynostosis is not a possible component of Feingold syndrome. Additionally,

Table 1. Summary of neuropsychiatric test score

Mullen Scales of Early Learning	Test Score (A.E.) 9 months : 07/28/2011	Test Score (A.E.) 4 years 6 months: 05/05/2015	Score range
Gross motor	T=50 (10 months)	NA (33 months)	Impaired
Visual Reception	T=43 (8 months)	20 (26 months)	Impaired
Fine Motor	T=44 (9 months)	20 (34 months)	Impaired
Receptive Language	T=26 (4 months)	20 (24 months)	Impaired
Expressive Language	T=29 (5 months)	20 (24 months)	Impaired

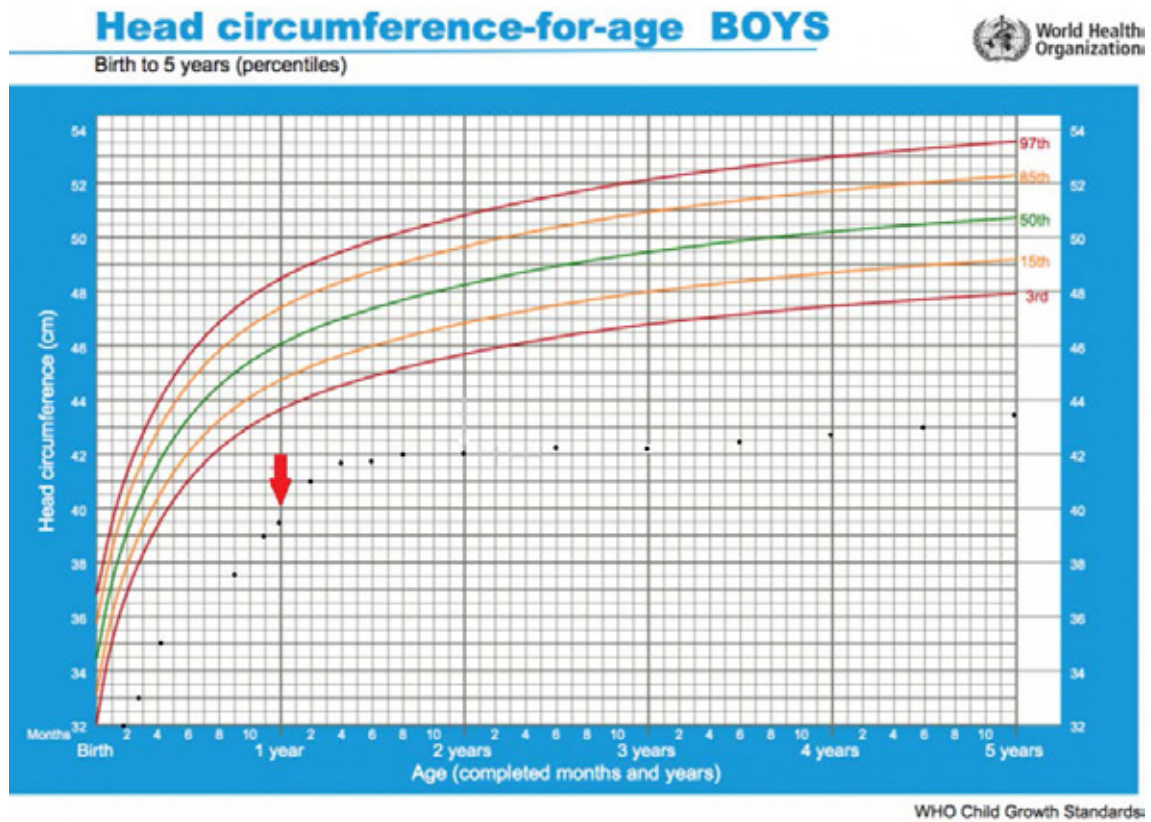


Figure 3. Head circumference of presented case. The red arrow indicated patient surgical intervention. Patient's head circumference has been significantly below standard percentiles

it should be noted given the phenotypic similarity between Feingold syndrome and other congenital conditions and genetic syndromes, the possibility exists that children with both Feingold syndrome and craniosynostosis have been included in previous studies, but were not specifically identified or diagnosed with these two conditions.

Older aged patients with syndromic craniosynostosis are more likely to demonstrate papilledema. Single suture synostosis in younger children generally does not correlate between intracranial pressure and fundoscopic examination, with the incidence of papilledema in younger children (age<1 year) at 20%. Therefore, an underline increased intracranial pressure may have caused prolonged CSF leak and delayed requirement of VPS placement [18]. It is unclear at this point, if there is an association between Feingold syndrome and increased intracranial pressure, although the crucial role of MYCN in development of the brain, limbs, visceral organs and nervous system during embryogenesis has been previously described [19,20].

Birgfeld et al. [21] emphasized that a multi-disciplinary team approach for high volume craniofacial surgical practice leads to improved outcomes and development of protocols for management. This case demonstrated the benefit of a multi-disciplinary team in the complex patient management of craniosynostosis, especially if the patient presents with other birth differences. Incorrect diagnosis by other medical providers without formal genetic consultation may lead to confused and misguided parents. If the patient is evaluated by multi-disciplinary team from

the beginning of care, parents may be better educated and have realistic expectations of treatment and outcome. Since Feingold syndrome itself is associated with microcephaly and developmental delays, the multidisciplinary team had extensive craniofacial group discussions prior to surgery. Each expert's opinions were important in the development of a treatment plan due to the rarity of the case. The focus should not be solely on the craniofacial malformation. Long term follow-up is essential in this patient, since the child is medically complex and developmentally challenged. The multi-disciplinary team can offer multiple resources and support long-term care and follow-up. The patient reported here continues to make slow progress despite the global developmental delay. Microcephaly, a component of Feingold Syndrome, remains an issue requiring continued vigilance.

Conclusion

Metopic craniosynostosis may be a component of craniofacial dysmorphism seen in Feingold syndrome. This case demonstrated importance of the multi-disciplinary team approach in making accurate diagnosis, determining surgical intervention and long-term follow up in Feingold syndrome with metopic craniosynostosis.

References

1. Feingold M, Gellis SS. Follow-up report on the syndrome identification and consultation service. Birth Defects Orig Artic Ser 1975; 11: 1-2.
2. Feingold M, Hall BD. Syndrome of microcephaly, facial

- and hand abnormalities, tracheoesophageal fistula, duodenal atresia and developmental delay. *Am J Med Genet* 1997; 69: 245-249.
3. Celli J, van Bokhoven H, Brunner, et al. Feingold syndrome: clinical review and genetic mapping. *Am J Med Genet A* 2003; 122A: 294-300.
 4. Lehman VT, Patterson MC. Cerebral and cerebellar white matter abnormalities with magnetic resonance imaging in a child with Feingold syndrome. *Am J Med Genet A* 2009; 149A: 2824-2827.
 5. Henriksson M, Luscher B. Proteins of the Myc network: Essential regulators of cell growth and differentiation. *Adv Cancer Res* 1996; 68: 109-182.
 6. Beltran H. The N-myc oncogene: Maximizing its targets, regulation and therapeutic potential. *Mol Cancer Res* 2014; 12: 815-822.
 7. Marcelis CL, Hol FA. Genotype-phenotype correlations in MYCN-related Feingold syndrome. *Hum Mutat* 2008; 29: 1125-1132.
 8. Panigrahi I. Craniosynostosis genetics: The mystery unfolds. *Indian J Hum Genet* 2011; 17: 48-53.
 9. Di Rocco F, Arnaud E, Renier D. Evolution in the frequency of non-syndromic craniosynostosis. *J Neurosurg Pediatr* 2009; 4: 21-25.
 10. Kweldam CF, van der Vlugt. The incidence of craniosynostosis in the Netherlands, 1997-2007. *J Plast Reconstr Aesthet Surg* 2011; 64: 583-588.
 11. Lajeunie E, Merrer LM, Marchac, et al. Syndromal and non-syndromal primary trigonocephaly: Analysis of a series of 237 patients. *Am J Med Genet* 1998; 75: 211-215.
 12. Jehee FS, Johnson D. Molecular screening for micro deletions at 9p22-p24 and 11q23-q24 in a large cohort of patients with trigonocephaly. *Clin Genet* 2005; 67: 503-510.
 13. Solomon BD. VACTERL/VATER Association. *Orphanet J Rare Dis* 2011; 6: 56.
 14. Giampietro PF, Adler Brecher. The need for more accurate and timely diagnosis in Fanconi anemia: A report from the International Fanconi Anemia Registry. *Pediatrics* 1993; 91: 1116-1120.
 15. www.omim.org/entry/218600
 16. Rittler M, Paz JE. VACTERL association, epidemiologic definition and delineation. *Am J Med Genet* 1996; 63: 529-536.
 17. Botto, LD, Khoury. The spectrum of congenital anomalies of the VATER association: An international study. *Am J Med Genet* 1997; 71: 8-15.
 18. Tuite, GF, Chong. The effectiveness of papilledema as an indicator of raised intracranial pressure in children with craniosynostosis. *Neurosurgery* 1996; 38: 272-278.
 19. Stanton BR, Perkins AS, Tessarollo L, et al. Loss of N-myc function results in embryonic lethality and failure of the epithelial component of the embryo to develop. *Genes Dev* 1992; 6: 2235-2247.
 20. Zindy F, Knoepfler PS, Xie S, et al. N-myc and the cyclin-dependent kinase inhibitors p18Ink4c and p27Kip1 coordinately regulate cerebellar development. *Proc Natl Acad Sci U S A* 2006; 103: 11579-11583.
 21. Birgfeld CB, Dufton. Safety of open cranial vault surgery for single-suture craniosynostosis: A case for the multidisciplinary team. *J Craniofac Surg* 2015; 26: 2052-2058.

Correspondence to:

Tomoko Tanaka,
Division of Neurological Surgery,
University of Missouri School of Medicine,
One Hospital Drive, MC318,
Columbia, MO 65212,
USA.
Tel: 573-882-4900
Fax: 573-884-5184
E-mail: tanakat@health.missouri.edu