

Importance of CT imaging in pediatric cochlear implantation: Emphasis the significance of the BCNC width.

Dokoska M^{1*}, Nikolovski N¹, Nikolova S², Kopcheva Barsova G¹

Departmental Clinic of Ear, Nose and Throat, Ss. Cyril and Methodius University in Skopje, Skopje, Macedonia

Department of Radiology, Ss. Cyril and Methodius University in Skopje, Skopje, Macedonia

Received: 04 July, 2022, Manuscript No. AAJCP-22-69792; **Editor assigned:** 05 July, 2022, PreQC No. AAJCP-22-69792(PQ); **Reviewed:** 11 July, 2022, QC No. AAJCP-22-69792; **Revised:** 19 July, 2022, Manuscript No. AAJCP-22-69792(R); **Published:** 27 July, 2022, DOI:10.35841/0971-9032.26.7.1520-1525.

Abstract

Introduction: Cochlear Implantation (CI), in the past more than 30 years, has become a standard of care for children with profound sensorineural hearing loss. As it became a routine intervention, requests for pre-op images have increased in the work-up for candidates. The optimal protocol for radio-diagnostics has not yet been defined. CT and MRI are complementary methods and both being used for this purpose. An absent cochlear nerve (CN) is the only absolute contraindication to cochlear implantation and MRI is a gold standard for CN detection. Some authors have reported the relationship between cochlear bony nerve canal (BCNC) stenosis and CN hypoplasia and aplasia.

Objectives: The aim of this study was to stress out the importance of CT by evaluating the width of the bony cochlear nerve canal (BCNC) in children with congenital sensorineural hearing loss (SNHL) and "normal" findings on thin section temporal bone CT.

Materials and methods: The width of the BCNC was retrospectively evaluated in two groups of patients. The study group included 11 children with congenital, bilateral SNHL who underwent cochlear implantation from July to December 2019. Eleven children aged 3-10 years, with no sensorineural hearing loss were taken as controls. Axial sections of their CT scans were used to measure the width of the BCNC.

Results: From the obtained results, the width of the BCNC in children with bilateral, profound sensorineural hearing impairment range from 1.0 to 2.3 mm with mean value of 1.5 ± 0.3 mm and is significantly smaller than in the control group.

Keywords: Bony cochlear nerve canal, children, congenital sensorineural hearing loss, CT.

Accepted on 20th July, 2022

Introduction

Hearing loss is the most common sensory disorder affecting the human population and over 5% of the world's population, 432 million adults and 34 million children, has total hearing loss that require rehabilitation to address their 'disabling' hearing loss. Prevalence of permanent bilateral childhood hearing impairment (>40 dB HL) varies from 1 to 1.4 per 1000 for newborns and increases to 1.62–1.68 per 100 at the age of 16 [1]. The prevalence of severe and profound hearing loss in children increases uniformly with age; this is because of non-diagnosis at screening, post-natal acquisition of hearing loss, late onset of progressive hearing loss, and immigration of children born in countries without neonatal hearing screening [1]. Of all newborns who have bilateral hearing loss, 25–30% have a profound loss (>90 dB HL) and 20–25% a severe loss (71–90 dB HL) and based on the current pediatric FDA guidelines, 45% of the children diagnosed with hearing loss are potential CI candidates. In most European countries the number of pediatric implantations falls into the range of 6–10 per million inhabitants annually [1].

The cochlear implant is an innovative electronic device that converts the auditory signal into an electrical signal which in turn stimulates neurons in the spiral ganglion and thus transmits the signal through the cochlear nerve and central auditory pathway to the auditory cortex. Therefore, the integrity of the cochlear nerve is a major factor influencing the development of auditory-speech performance after cochlear implantation and absence of the cochlear nerve (cochlear nerve aplasia) is the only absolute contraindication for CI. MRI is a gold standard for CN detection but on the other hand, CT of the temporal bone which historically has been the modality of choice for evaluating patients with bilateral SNHL can be easily and quickly utilized in almost all situations [2,3].

Recently, some authors have reported a relationship between bony cochlear nerve canal (BCNC) stenosis detected on CT and CN hypoplasia [4-6]. In a report by Komatsubara et al., patients with a narrow BCNC on CT studies were diagnosed as having CN hypoplasia on MRI with 88.9% sensitivity and 88.9% specificity. Those authors stated that in ears in which bony CNC was <1.5 mm on CT, CN hypoplasia could be seen on MRI [6]. Bony cochlear nerve canal, also referred to as the

cochlear fossette, is a short bony canal between the base of the cochlear modulus and the fundus of the internal auditory canal and contains the cochlear nerve fibers that run from the spiral ganglion to the cochlear nerve. The width of the canal is directly correlated with the diameter of the cochlear nerve, so narrowed canal is associated with hypoplasia or aplasia of the cochlear nerve and sensorineural hearing loss [5,7]. According to the literature, patients with sensorineural hearing loss who are candidates for cochlear implantation and have a hypoplastic or absent cochlear nerve may have less benefit from the cochlear implant [8]. Papsin has shown that the benefits of cochlear implantation in patients with narrowed internal auditory canal (IAC) or cochlear nerve canal are lower than in children who are implanted and do not have this abnormality [9]. Hence the need for preoperative assessment of its width.

The aim of this study was to assess the width of the cochlear nerve canal in a series of children with bilateral, profound sensorineural hearing loss (b-SNHL) in whom no abnormalities of the high-resolution temporal bone computed tomography (TBCT) were detected comparable to the group of patients without sensorineural hearing loss and emphasize the importance and significance of measuring this radiological biomarker (BCNC) on pre-op CT in children who should undergo CI.

Materials and Methods

Study design and patient selection

In this pilot study we retrospectively reviewed the data from 11 children, with bilateral, congenital sensorineural hearing loss, who underwent CI in the period July - December 2019 at the University Clinic for Ear, Nose and Throat in Skopje. As part of the diagnostic protocol, in all children brainstem evoked response audiometry (BERA) was done and profound sensorineural hearing loss, which means absence of auditory responses at the strongest sound stimuli (in the range 80-100 dB) was confirmed. Also, all of them underwent pre-operative CT scan of the temporal bone with a thin section and no abnormalities of the inner, middle and outer ear were detected.

To design a control group, we recruited 11 age matched patients without sensorineural hearing loss. CT scan of the temporal bone in these children was performed for another reason such as suspected of acute mastoiditis, chronic otitis media, or perforation of the tympanic membrane, and also have a normal inner ear finding.

All 22 children underwent 0.5 mm-thickness high-resolution TBCT on a 64-slice Somatom Definition AS + computed tomography (Siemens Healthiness, USA) at the Institute of Radiology, performed according to a standard temporal bone evaluation protocol. In addition, each cochlea was examined separately to check for possible malformation according to the Sennaroglu classification system [10].

Radio-diagnostics and measurement of the width of the BCNC

Axial plane images were used to measure the width of the BCNC. The diameter of the cochlear nerve canal was measured as a distance between the inner boundary of its bony walls in the middle of an axial section at the level of the base of the modulus. The BCNC is located between the bottom of the internal auditory canal (IAC) and the base of the cochlea and contains the nerve fibers that run from the spiral ganglion to the cochlear nerve [1] (Figure 1). Therefore, a narrow BCNC probably indicates an anatomical or functional defect of the cochlear nerve due to which the width of the cochlear nerve canal seems to be a reliable radiological marker of the presence and status of the cochlear nerve.

As these data represent appropriate pairs, the widths of a total of 22 were measured BCNC in the study group and 22 BCNC in the control group. From the obtained measurements, the following factors were considered retrospectively:

- Range of the width of BCNC in children with bilateral severe sensorineural hearing loss and the children within in control group.
- The average value for the channel width in the groups was calculated and using the t-test their correlation was analyzed.

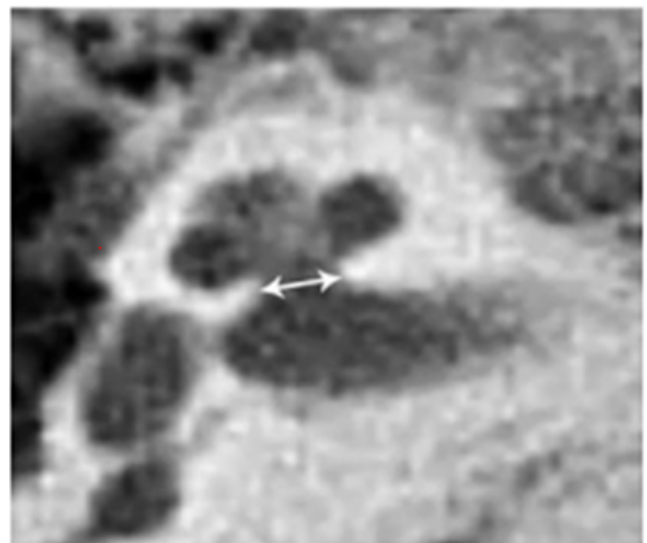


Figure 1. Axial- length resolution CT section showing bony cochlear nerve canal diameter at the mid-modiolar level.

Results

Demographic characteristics

The study involved 22 children aged 2 to 12 years divided into two groups, the study group (SG) 11 children with congenital, bilateral SNHL and 11 children without hearing impairment (control group-CG). 72.7% of children with SNHL are male and 27.3% are female, the percentage difference registered in relation to gender is statistically significant for $p < 0.05$ (Difference test, $p = 0.0332$). In CG 54.5% is male, and with

45.6% female, the percentage difference is statistically insignificant for $p > 0.05$ (table and figure 1). The mean age of the children in the study group was 4.8 ± 3.7 years, minimum 2 years, maximum 12.50% of patients were older than 3 years for Median IQR = 3 (2-8) (table 2). The mean age of patients in the control group was 6.27 ± 2.63 (table 3) and there was no significant age difference between the two groups.

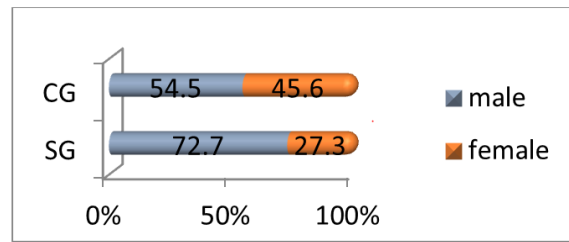


Figure 2. Distribution gender.

Gender	SG		CG	
	Number	%	Number	%
Male	8	72.7	6	54.5
Female	3	27.3	5	45.6
Total	11	100	11	100

Table 1. Distribution by gender.

Number (N)	Average (Mean)	Standard deviation (Std. Dev.)	Minimum (Min)	Maximum (Max)	Percentiles		
					25th	50th	75th
11	4.8	3.7	2	12	2	3	8

Table 2. Display of the mean age of the children in the study group.

Number (N)	Average (Mean)	Standard deviation (Std. Dev.)	Minimum (Min)	Maximum (Max)	Percentiles		
					25th	50th	75th
11	6.27	2.63	3	10	4	6	9

Table 3. Display of the mean age of the children in the control group.

Radiologic parameters of the BCNC and cutoff values for the width

Because the data being analyzed represent batch pairs (two measurements were obtained from one patient - left and right BCNC), separate and summarized calculations of the mean value of the width were made. The average value of the canal in the right ear in SG is 1.5 ± 0.3 mm, minimum 1.0 mm, maximum 2.1 mm, in 50% of patients the width is over 1.5 mm

for Median IQR = 1.5 (1.3-1.7). The average value of the canal in the right ear in CG is 2.1 ± 0.2 mm, minimum 1.7 mm, maximum 2.4 mm, in 50% of patients the width is over 2.0 mm for Median IQR = 2.0 (1.8-2.3) (Table 4 and Figure 2).

According to the t-test, the difference between the average values of the right ear canal width of SG and CG is statistically significant for $p < 0.05$ (t-test = 4.52776, $p = 0.000205$).

Right ear	Number (N)	Average (Mean)	Standard deviation (Std. Dev.)	Minimum (Min)	Maximum (Max)	Percentiles		
						25th	50th (Median)	75th
SG	11	1.5	0.3	1	2.1	1.3	1.5	1.7
CG	11	2.1	0.2	1.7	2.4	1.8	2	2.3

Table 4. Average width of the right BCNC in both groups.

Right ear	Number (N)	Average (Mean)	Standard deviation (Std. Dev.)	Minimum (Min)	Maximum (Max)	Percentiles		
						25th	50th (Median)	75th
SG	11	1.5	0.4	1.1	2.3	1.3	1.5	1.8
CG	11	2.1	0.2	1.8	2.5	2	2.1	2.2

Table 5. Average width of the left BCNC in both groups.

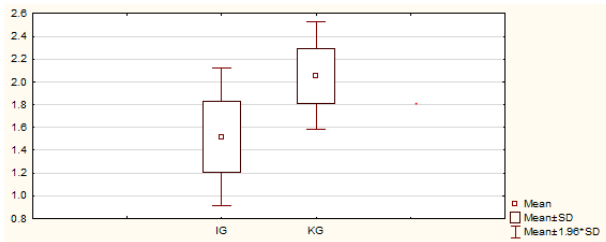


Figure 2. Average width of the right BCNC in both groups.

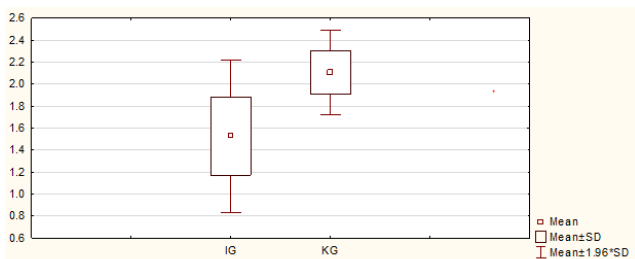


Figure 3. Average width of the left BCNC in both groups.

The average value of the canal in the left ear in SG is 1.5 ± 0.4 mm, minimum 1.1 mm, maximum 2.3 mm, in 50% of patients

Right ear	Number (N)	Average (Mean)	Standard deviation (Std. Dev.)	Minimum (Min)	Maximum (Max)	Percentiles		
						25th	50th (Median)	75th
SG	22	1.5	0.3	1	2.3	1.3	1.5	1.7
CG	22	2.1	0.3	1.7	2.5	1.9	2.15	2.3

Table 6. Average width of the BCNC in both groups.

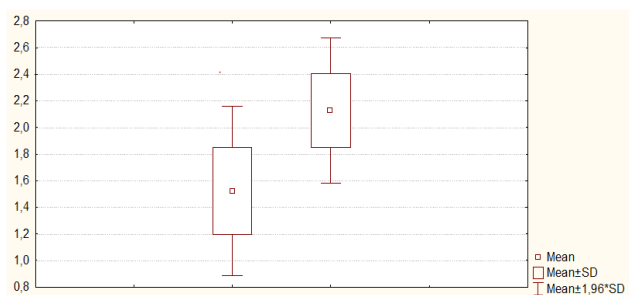


Figure 4. Average width of the BCNC in both groups.

Discussion

The data from the literature show that there is no consensus on the question of what is normal width and what is stenosis or

the width is over 1.5 mm for Median IQR = 1.5 (1.3-1.8). The average value of the canal in the left ear in CG is 2.1 ± 0.2 mm, minimum 1.8 mm, maximum 2.5 mm, in 50% of patients the width is over 2.1 mm for Median IQR = 2.1 (2.0-2.2) (Table 5 and Figure 3).

According to the t-test, the difference between the average values of the left ear canal width of SG and CG is statistically significant for $p < 0.05$ (t-test = 4.74922, $p = 0.000123$). The difference between the average values expressed in mm. between left and right ear in SG is statistically insignificant for $p > 0.05$ (t-test = 0.0640018, $p = 0.949591$). The difference between the average values expressed in mm. between left and right ear in CG is statistically insignificant for $p > 0.05$ (t-test = 0.578961, $p = 0.569080$). The average value of the BCNC width in SG is 1.5 ± 0.3 mm, minimum 1.0 mm, maximum 2.3 mm, in 50% of patients the width is below 1.5 mm for Median IQR = 1.5 (1.3-1.7). The average value of the BCNC width in CG is 2.1 ± 0.3 mm, minimum 1.0 mm, maximum 2.5 mm, in 50% of patients the width is over 2.15 mm for Median IQR = 2.15 (1.9-2.3) (Table 6 and Figure 4).

According to the t-test, the difference in the mean values for the width of the BCNC between SG and CG is statistically significant for $p < 0.05$ (t-test = 6.62912, $p = 0.000000$).

hypoplasia of the bony canal of the cochlear nerve. According to various authors, several numerical criteria have been proposed for the determination of canal stenosis, BCNC (less than 1.2–1.82) [11,12]. Fatterpekar was the first who measured the width of the BCNC using CT. According to him, the average value for canal width in patients without sensorineural hearing loss is 2.13 ± 0.44 and is significantly higher than that in patients with severe, bilateral sensorineural hearing loss (1.82 ± 0.24) [5]. Stjernholm & Muren measured 117 temporal bone silicone molds, and 16 of them compared the dimensions measured in this way with the dimensions measured on the corresponding CT images of these samples. According to the results of their measurements, BCNC with a width (< 1.4 mm) is considered to be a very narrow channel and $BCNC > 3$ mm is considered to be an abnormally wide channel [3].

The results from our measurements showed that the average value of the BCNC channel width in SG is 1.5 ± 0.3 mm,

minimum 1.0 mm, maximum 2.3 mm, in 50% of patients the width is below 1.5 mm for Median IQR = 1.5 (1.3-1.7) a the average value of the channel width in CG is 2.1 ± 0.3 mm, minimum 1.0 mm, maximum 2.9 mm, in 50% of patients the width is over 2.15 mm for Median IQR = 2.15 (1.9-BCNC 2.3) (table 6 and figure 5).

According to the t-test, the mean value for BCNC width in patients with severe, bilateral sensorineural hearing loss compared to the patient with normal hearing is statistically significantly lower by $p < 0.05$ (t-test = 6.62912, $p = 0.000000$).

Study	Temporal bones Studied (N)	Technique	Slice	CNC,Width,Mean (SD), mm
Fatterpekar et al, 1999	100	CT	1mm	2.13 (0.44)
Stjernholm and Muren,2002	100	CT	1mm	1.91 (0.24)
Hender et al,20111	110	Harvested slide temporal bones	2- μ m	2.26 (0.25)
Curent study	22	CT	0.5 mm	2.1 (0.3)

Table 7. Temporal bones in patients with normal hearing.

Study	Temporal bones Studied (N)	Technique	Slice	CNC,Width,Mean (SD), mm
Fatterpekar et al, 2000	100	CT	1mm	1.82(0.24)
Abigail at all 20128	85	CT	1mm	0.98 (0.57)
CURRENT STUDY	22	CT	0.5 mm	1.5 (0.3)

Table 8. Temporal bones in patients with SNHL.

However, the authors and the literature agree on two findings: 1. Patients with sensorineural hearing loss are much more likely to have a smaller canal than those with normal hearing, and 2. Narrow BCNC detected on CT is a serious indicator of possible presence of hypoplasia or aplasia of the cochlear nerve.

The reason why this channel is narrower in patients with sensorineural hearing loss is not yet clear but it is assumed that the answer lies in embryonic development. Namely, during development, the internal auditory canal (IAC) is transformed from a mesodermal layer into cartilage tissue and eventually into a bone canal. During the same period, the cochlear nerve channel (CNC) is formed, which requires stimulation for normal development. Because the IAC is formed around the vestibular-cochlear nerve (VCN) neuronal fibers, stenosis of the IAC and CNC is probably due to a lack of sufficient stimulus for normal development due to hypo or cochlear nerve aplasia [13].

Patients with a cochlear implant who have a cochlear nerve deficiency (hypoplasia or aplasia) show significantly worse post-operative results, so these findings are particularly important for physicians evaluating children with sensorineural hearing loss who are candidates for cochlear implant.

Radio-diagnostics plays a very important role in the preoperative evaluation of patients who are candidates for cochlear implantation. It enables preoperative detection of congenital or acquired abnormalities of the inner ear and cochlear nerve, and also provides the surgeon with information on other possible variations in temporal bone anatomy that are important for the surgical approach or indicate possible difficulties during the intervention. The optimal protocol for

radio-diagnostics has not yet been defined. CT and MRI are complementary methods and both being used for this purpose. MRI is a gold standard for CN detection. CT is a historical and current method of choice in the diagnostic treatment of patients before implantation in a number of institutions around the world that deal with this cochlear implantation. However, because this method does not directly show the cochlear nerve, the narrowed BCNC on CT may be an indicator for the selection of children with sensorineural hearing loss who will need to be referred to an MRI for direct visualization of the cochlear nerve. and a definitive assessment of the presence of hypoplasia or cochlear nerve aplasia which is the only absolute contraindication to cochlear implant placement.

Conclusion

In this pilot study, the mean value of BCNC channel width in patients with severe bilateral sensorineural hearing loss is 1.5 ± 0.3 mm and is statistically significantly lower by $p < 0.05$ (t-test = 6.62912, $p = 0.000000$) calculated with an average BCNC width value (2.1 ± 0.3) mm in patients with normal hearing. The average value of 1.5 mm will be taken as the limit width and all values below this will be defined as a stenotic or stent channel. The optimal protocol for radio-diagnostics has not yet been defined. CT and MRI are complementary methods and both being used for this purpose. So when its feasible use both, but when not in children with narrow BCNC, MRI is mandatory.

The results of this study will be used to further investigate whether the outcome of cochlear implantation in deaf children is directly correlated with BCNC width These data are of great importance in the preoperative assessment of prelingually deaf children and making decision whether are suitable for a cochlear implant or some other type of implant which is really

important for the hearing and language development and their timely socialization.

References

1. De Raeve and van Hardeveld – Prevalence of cochlear implants in Europe: What do we know and what can we expect, *Journal of Hearing Science*, 2013 Vol. 3, No. 4
2. Lowe LH, Vezina LG (1997) Sensorineural hearing loss in children. *Radiographics* 17:1079–1093
3. Stjernholm C, Muren C (2002) Dimension of the cochlear nerve: a radioanatomic investigation. *Acta Otolaryngol* 122:43–48
4. Kono T (2008) Computed tomographic features of the bony canal of the cochlear nerve in pediatric patients with unilateral sensorineural hearing loss. *Radiat Med* 26:115–119
5. Fatterpekar GM, Mukherji SK, Alley J et al (2000) Hypoplasia of the bony canal for the cochlear nerve in patients with congenital sensorineural hearing loss: initial observations. *Radiology* 215:243–246
6. Komatsubara S, Haruta A, Nagano Y et al. Evaluation of cochlear nerve imaging in severe congenital sensorineural hearing loss, *ORL J Otorhinolaryngol Relat Spec*. 2007;69(3):198-202
7. Mikiko Miyasaka, Shunsuke Nosaka, Noriko Morimoto, Hidenobu Taiji & Hidekazu Masaki, CT and MR imaging for pediatric cochlear implantation: emphasis on the relationship between the cochlear nerve canal and the cochlear nerve, *Pediatric Radiology*, volume 40, pages1509–1516(2010)
8. Byung Chul Kang, Jee Yeon Lee, Yehree Kim, Jun Woo Park, Woo Seok Kang, Joong Ho Ahn, Hong Ju Park, and Jong Woo Chung, Outcome of Cochlear Implantation in Children with Narrow Bony Cochlear Nerve Canal, *Otology & Neurotology*: August 2019 - Volume 40 - Issue 7 - p e679-e685.
9. Papsin BC. Cochlear implantation in children with anomalous cochleovestibular anatomy. *Laryngoscope*, 2005; 115(1, pt2) (suppl 106): 1-26.
10. Levent Sennaroglu 1, Isil Saatci, A new classification for cochleovestibular malformations, *Laryngoscope*. 2002 Dec; 112(12):2230-41. doi: 10.1097/00005537-200212000-00019
11. Hantai Kim, MD1, Dong Young Kim, MD1, Eun Ju Ha, MD, PhD2, and Hun Yi Park, MD, PhD, Clinical Value of Measurement of Internal Auditory Canal in Pediatric Cochlear Implantation, *Annals of Otology, Rhinology & Laryngology*, 2019, Vol. 128(6S) 61S– 68S
12. Abigail Wilkins, BA; Sanjay P. Prabhu, MBBS, FRCR; Lin Huang, PhD; et al Patricia B. Ogando, MD; Margaret A. Kenna, MD, MPH, Frequent Association of Cochlear Nerve Canal Stenosis with Pediatric Sensorineural Hearing Loss, *Arch Otolaryngology Head Neck Surg*. 2012;138(4): 383-388. doi:10.1001/archoto.2012.237
13. Mcphee JR, Van De Water Tr. Epithelial-mesenchymal tissue interactions guiding otic capsule formation: the role of the otocyst. *J Embryol Exp Morphol* 1986; 97:1–24.

*Correspondence to:

Dokoska M

Departmental Clinic of Ear

Nose and Throat, Ss. Cyril and Methodius University in Skopje

Skopje, Macedonia