

Evaluation of the anti-ulcer activities of *Morus alba* extracts in experimentally-induced gastric ulcer in rats.

¹Mahmood Ameen Abdulla, ²Hapipah Mohd Ali, ^{1,3}Khaled Abdul-Aziz Ahmed, ¹Suzita Mohd Noor, ¹Salmah Ismail

¹Department of Molecular Medicine, Faculty of Medicine, University Malaya 50603 Kuala Lumpur, Malaysia

²Department of Chemistry, Faculty of Science, University Malaya 50603 Kuala Lumpur, Malaysia

³Faculty of Dentistry, Ibb University, Ibb, Yemen

Abstract

This study was aimed to elucidate the anti-ulcerogenic effects of *Morus alba* ethanolic extracts on ethanol induced gastric mucosal injury in animals. Four groups of adult male *Sprague Dawley* rats were included in the study. 10% Tween 80 was given orally to Group 1 rats as a negative control group. Group 2 and 3 animals received alcoholic extract of *Morus alba* orally at 250 mg/kg and 500 mg/kg doses, respectively. Omeprazole (20 mg/kg body weight) were given orally to Group 4 rats as a positive control. 60 minutes after their pretreatment, all rats were administered with 5 ml/kg absolute ethanol orally. One hour later, all animals were sacrificed. Grossly, Group 1 animals showed severe mucosal injury of gastric mucosa. However, a statistically significant reduction of gastric mucosal damage ($p < 0.05$) was seen in animals pretreated with either plant extracts (250 mg/kg or 500 mg/kg body weight) or Omeprazole compared to negative control animals. Rats pretreated with 500mg/kg plant extract or omeprazole have significantly ($p < 0.05$) protected gastric mucosa compared to animals pretreated with 250mg/kg plant extract. Microscopically, animals (Group 1) pretreated with 10% Tween 80 and administered absolute alcohol showed severe gastric mucosal damages, submucosal edema, and leucocytes infiltration. Animals pretreated with plant extracts or omeprazole showed marked reduction of gastric mucosal damage, reduction of edema and leucocytes infiltration of the submucosal layer. These results indicate that *M. alba* extract exhibits significant anti-ulcerogenic activity in rats.

Key Words: *Morus alba*, anti-ulcer, omeprazole, histology

Accepted January 02 2009

Introduction

Morus alba L. (mulberry) as a non-toxic natural therapeutic agent, belongs to the family of Moraceae. The whole plant of *M. alba* L. possesses multiple medicinal values [1]. The root bark, leaves and fruits of *Morus alba* have been traditionally used in Asian countries for medicinal purposes due to its anti-inflammatory [2,3], hypoglycemic [4], hypolipidemic and antioxidant roles [5,6]. Several studies have shown that *Morus alba* has neuroprotective, antiphlogistic, liver and kidney protective, hypotensive, diuretic, anticough, and analgesic effect [7-9]. Furthermore, it shows antiviral [10] and antimicrobial effects [11].

Pharmacological studies reveal that flavonoids, phenols, coumarins and terpenols are the main bioactive constituents

in *M. alba* [1]. Recent studies have revealed that flavonoids and phenolic acid show speeding cruor, antioxidant, radioprotective, anti-mutagenic and anticarcinogenic effects and that coumarins possess antibacterial, hypotensive, calmative and spasmolytic functions [12, 13]. To our knowledge, there were no reports regarding the anti-ulcerogenic effect of *M. alba* leaves. The present study aimed to elucidate the anti-ulcerogenic effect of *M. alba* leaves in experimental rats with macroscopical and histological investigation.

Materials and Methods

Omeprazole, as a reference anti-ulcer drug, belongs to a class of drugs called proton pump inhibitor which block the production of acid by the stomach. The drug was suspended in 10% Tween 80 and administered orally to ani-

mals at a concentration of 20 mg/kg body weight (5 ml/kg body weight). The leaves of *Morus alba* were collected from the Animal Department of the Faculty of Agriculture, University Kebangsaan Malaysia and identified by comparison with specimens available at the Herbarium of Rimba Ilmu, Institute of Biological Sciences, University of Malaya. The leaves were washed with distilled water and dried in incubator at 50°C for 5-7 days. The dried leaves were ground to powder using a grinder.

Preparation of *Morus alba* alcoholic extract

The dried powdered leaves were extracted by maceration in ethanol (100g/1500 ml, w/v) in a conical flask for 5 days at room temperature. Afterwards, the solvent was filtered followed by distillation under reduced pressure in EYELA rotary evaporator until excess solvent was evaporated. The extract was suspended in 10% Tween 80 (w/v) and was administered to rats at doses of 250 mg/kg and 500 mg/kg body weight.

Experimental animals

Animals weighing 200-250 g were deprived of food for 48 h, but they were allowed free access to tap water until 2 h before the experiment. During the fasting period, the animals were placed individually in cages with wide-mesh wire bottoms to prevent coprophagy. On the day of experiment, the rats were randomly divided into 4 groups with 6 animals each.

Acute toxicity test

The acute toxic class method of the Organization for Economic Cooperation and Development (OECD) was used to determine a safe dose for the extracts [14]. Thirty six animals (18 males and 18 females) were assigned equally into 3 groups labeled as vehicle (distilled water); low (2 g/kg body weight) and high (5 g/kg body weight) doses of leaf extract preparations. The animals were fasted overnight (food but not water) prior dosing. Food was withheld for a further 3 to 4 hours after dosing. Observations were done on mortality and behavioral changes of the rats following treatment for 24 hours. The acute toxicity LD₅₀ was calculated at the geometric mean of the dose that resulted in 100% lethality and that which cause no lethality at all.

Animals' treatment

Control rats (Group 1) received 10% Tween 80 (5 ml/kg) by orogastric intubations; whereas Group 2 and 3 rats received alcoholic extract of *M. alba* at concentrations of 250 mg/kg and 500 mg/kg suspended in 10% Tween 80 (5 ml/kg body weight of rats) by the same route, respectively. Group 4 animals received 20 mg/kg of Omeprazole suspended in 10% Tween 80 by orogastric intubations.

After 60 minutes, all animals were administered orally with 5 ml/kg absolute alcohol to induce gastric ulcer in all rats groups. One hour after their administration, all animals were sacrificed by over-dose of diethyl ether and their stomach were rapidly removed and immersed in 10% buffered formalin solution.

Gross gastric lesions evaluation

Each stomach was opened along the greater curvature, rinsed with tap water to remove gastric contents and the mucosa was examined under dissecting microscope grossly (1.8x) with a square-grid eyepiece (big square: length X width = 10 X 10 mm² = ulcer area) to assess the formation of ulcers area (hemorrhagic lesions). The length and width of each lesion was determined and the sum of the area of all lesions for each stomach was expressed as the ulcer area (mm²). The ulcer area (UA) was calculated as described by [15] with few modifications. The inhibition percentage was calculated by the following formula of Njar et al. [16]:

$$(\%I) = [(UA_{\text{control}} - UA_{\text{treated}}) \div UA_{\text{control}}] \times 100.$$

Histological lesions evaluation

The gastric wall specimen were fixed in 10% buffered formalin and processed by paraffin tissue processing machine. The stomach was assessed for damage by taking a 5 µm section, stained with hematoxylin and eosin.

Ethics

The experimental protocol for animal work was approved by the local ethics committee for animal experimentation in the Faculty of Medicine, University of Malaya, Ethic No. PM 28/-9/2007 MAA (R).

Statistical analysis

All values are reported as mean + S.E.M. and the statistical significance of differences among groups were assessed using one-way analysis of variance (ANOVA). A value of $P < 0.05$ was considered significant. Statistical computations were calculated using SPSS 11.5 for Windows software (SPSS Inc, Chicago, IL, USA).

Results

Acute toxicity study

Animals treated with *M. alba* extract (low and high dose) did not produce any major clinical signs of toxicity (respiratory distress, haematuria, uncoordinated muscle movement) during 24 hours observation period. No lethality was observed upon oral administration at the end of 24

Anti-ulcer activities of *Morus alba* extracts

hours of observation. It is indicated that the extract is safe and the oral lethal dose (LD₅₀) for male and female rats is above 5 g/kg body weight of rats.

Macroscopical examination

Animals pre-treated with 10% Tween 80 followed by absolute ethanol showed extensive macroscopic lesions

(Table.1 and Fig.1). Severe hemorrhagic lineage was observed in variable sizes with the hemorrhagic lesions distributed all over the glandular part of the stomachs indicating that gastric ulcer was completely formed. Pre-treatment with ethanolic extracts of *M. alba* or Omeprazole significantly reduced ($P < 0.05$) the formation of ethanol-induced gastric lesions compared to Group 2 animals (Table.1 and Fig.2).

Table 1: Effects of *Morus alba* extracts on ethanol-induced mucosal injury in rats

Animal group	No. of rats	Pre-treatment (5 ml/ kg dose)	Ulcer area (mm ²) (Mean ± S.E.M)	Inhibition (%)
1	6	10% Tween 80	1360.76 + 121.00*	-
2	6	<i>Morus alba</i> (250 mg/kg)	485.00 + 25.76**	64.34**
3	6	<i>Morus alba</i> (500 mg/kg)	245.00 + 11.03	82.00
4	6	Omeprazole (20 mg/kg)	190.17 + 9.97	86.02

All values are expressed as mean ± S.E.M. * $P < 0.001$ vs. Group 2, Group 3, and Group 4. ** $P < 0.01$ vs. Group 3 and Group 4.

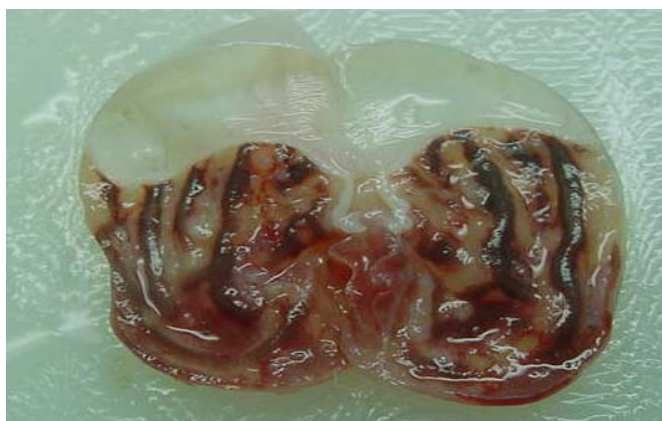


Figure 1. Extensive visible hemorrhagic necrosis of gastric mucosa caused by absolute ethanol in control animals pretreated with 10% Tween 80 (1.8x magnification).

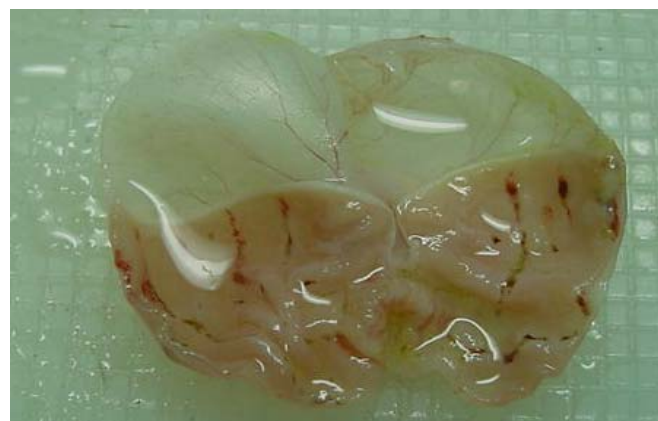


Figure 2. Mild macroscopic necrosis of gastric mucosa due to cytoprotection of *Morus alba* extract (500 mg/kg) against absolute ethanol-induced gastric ulcer (1.8x magnification).

Rats pretreated with *M. alba* (500 mg/kg body weight) or Omeprazole showed flattening of gastric mucosal folds and significant reduction in hemorrhagic lines compared with the animals administered *Morus alba* extract at a dose of 250 mg/kg body weight. There were no significant differences between rats pretreated with *M. alba* extract at a dose of 500 mg/kg body weight or rats pretreated with Omeprazole in term of cytoprotection (Table.1).

Microscopical examination

Rats pre-treated with 10% Tween 80 (Group 2) for 60 minutes followed by administration of absolute ethanol showed severe mucosal damage and submucosa was markedly thickened by edema (Fig.3). Deep hemorrhagic lesions of mucosal layer and infiltration of leucocytes were observed in the submucosal layer. As shown in Figure 4, animals pre-treated with plant extracts or Omeprazole, showed mild mucosal damage, submucosal edema, and leucocytes infiltration.

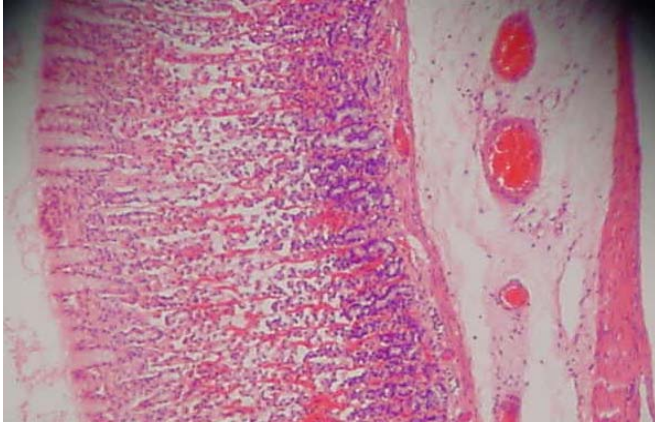


Figure 3. Histological section of the absolute ethanol-induced gastric mucosal damage in control animals (pretreated with 10% Tween 80). Severe disruption of the surface epithelium are seen and necrotic lesions penetrate deeply into mucosa with extensive edemas of submucosa and leucocyte infiltration (H&E stain, 40x magnification).

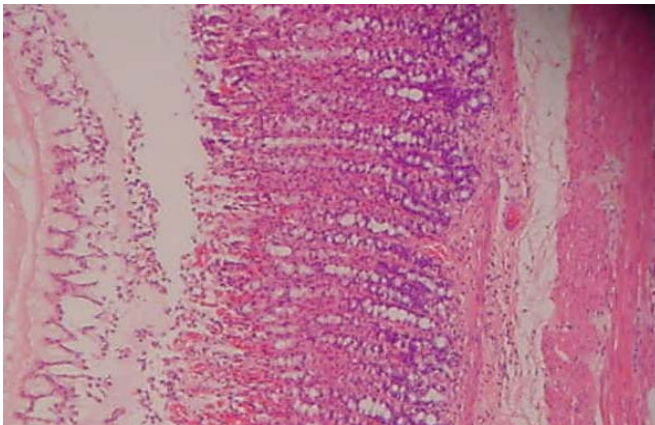


Figure 4. Histological examination of the absolute ethanol-induced gastric mucosal ulcer in animals pretreated with *M. alba* extract (500 mg/kg). Mild disruptions of surface epithelium are present but deep mucosal damage is absent. *M. alba* extract has reduced submucosal edema and leucocytes infiltration (H&E stain, 40x magnification).

Discussion

The results of the present study showed that rats pretreated with *M. alba* extract significantly reduced the gastric mucosal injury with marked reduction in the leucocytes infiltration of submucosal layer. Cytoprotection was assessed by reduction in the macroscopically and microscopically visible lesions. Similarly, Cheng and Koo [17] have showed that oral administration of plant extract before ethanol administration significantly decreases neutrophil infiltration of gastric mucosa. Absolute alcohol extensively damaged the gastric mucosa leading to increased neutrophil infiltration into the gastric mucosa.

Neutrophils are a major source of inflammatory mediators and can release potent reactive oxygen species such as superoxide, hydrogen peroxide and myeloperoxidase derived oxidants. These reactive oxygen species are highly cytotoxic and can induce tissue damage [17]. Furthermore, neutrophil accumulation in gastric mucosa has been shown to induce microcirculatory abnormalities [18]. Suppression of neutrophil infiltration during inflammation was found to enhance gastric ulcer healing [19]. The disturbances in gastric secretion, damage to gastric mucosa, alterations in permeability, gastric mucus depletion and free-radical production have been reported as the pathogenic mechanism of ethanol [20].

The anti-ulcer mechanisms of gastric mucosa may be due to strengthening action on gastric mucosal lining and the suppression of damaging effects of free radicals [17]. Other studies have shown the potent inhibitory effect other types of plants on inflammation and the anti-inflammatory property of these plants may be attributed to inhibition of nitric oxide synthesis leading to enhancement of ulcer healing [21,22]. In addition, *M. alba* extract possesses a potential anti-inflammatory activity and may prevent organ or tissue injury during acute endotoxemia or sepsis by suppressing inflammatory mediators and thus facilitates ulcer healing [2,3]. *M. alba* leaves contain anti-inflammatory and antioxidant properties [23]. The anti-inflammatory and antioxidant properties of turmeric may exert antiulcer activity through scavenging reactive oxygen species [24]. The acute toxicity profile of *M. alba* leaf extract could be considered favorable judging from the high oral LD₅₀ value obtained and the absence of adverse clinical manifestations in experimental animals after 24 hours of observation. In conclusion, the results of the present study suggest a direct protective effect of *Morus alba* extracts on gastric mucosal damage and that the gastroprotective action of this plant may be due to its anti-inflammatory and antioxidant properties. However, further studies are required to explore the mechanism of action in the gastric mucosa and submucosa.

Acknowledgment

This study was financially supported by the University of Malaya through the Science Fund grant 12-02-03-2051. The authors are grateful to the Head of the Department of Molecular Medicine, Faculty of Medicine, University of Malaya, Malaysia.

References

1. Committee of Jiangsu New Medicine College, Encyclopedia of Traditional Chineses Medicine, Shanghai Science and Technology Press, Shanghai, 1995, p. 1963.

2. Sohn HY, Son KH, Kwon CS, Kwon GS, Kang SS. Antimicrobial and cytotoxic activity of 18 prenylated flavonoids isolated from medicinal plants: *Morus alba* L., *Morus mongolica* schneider, *Broussonetia papyrifera* (L.) vent, *Sophora flavescens* ait and *Echinosophora koreensis* nakai. *Phytomedicine* 2004; 11: 666-672.
3. Choi EM, Hwang JK. Effects of *Morus alba* leaf extract on the production of nitric oxide, prostaglandin E₂ and cytokines in RAW 264.7 macrophages. *Fitoterapia* 2005; 76: 608-613.
4. Singab A, El-Beshbishy H, Yonekawa M, Nomura T, Fukai T. Hypoglycemic effect of Egyptian *Morus alba* extract: effect on diabetes and lipid peroxidation of streptozotocin-induced diabetic rats. *J Ethnopharmacol* 2005; 100: 333-338.
5. El-Beshbishy H, Singab AB, Sinkkonen J, Pihlaja K. Hypolipidemic and antioxidant effects of *Morus alba* L. (Egyptian mulberry) root bark fractions supplementation in cholesterol-fed rats. *Life Science* 2006; 78: 2724-2733.
6. Katsube T, Imawaka N, Kawano Y, Yamazaki Y, Shiwaku K, Yamane Y. Antioxidant flavonol glycosides in mulberry (*Morus alba* L.) leaves isolated based on LDL antioxidant activity. *Food Chem* 2006; 97: 25-31.
7. Fukai T, Satoh K, Nomura T, Sakagami H. Antinephritis and radical scavenging activity of prenylflavonoids. *Fitoterapia* 2003; 74: 720-724.
8. Kim H, Jeong T, Lee M, Park Y, Choi M. Lipid lowering efficacy of hesperetin metabolites in high-cholesterol fed rats. *Clin Chim Acta* 2003; 237: 129-137.
9. Yu D, Duan Y, Bao Y, Wei C, An L. Isoflavonoids from *Astagalus monghilocus* protect PC12 cells from toxicity induced by L-glutamine. *J Ethnopharmacol* 2005; 98: 89-94.
10. Du J, He Z, Jiang R, Ye W, Xu H, But P. Antiviral flavonoids from the root bark of *Morus alba* L., *Phytochemistry* 2003; 62: 135-138.
11. Fukai T, Kaitou K, Terada S. Antimicrobial activity of 2-arylbenzofurans from *Morus* species against methicillin-resistant *Staphylococcus aureus*. *Fitoterapia* 2005; 76: 708-711.
12. Kosmider B, Osiecka R. Flavonoid compounds: a review of anticancer properties and interactions with *cis*-diamminedichloroplatinum (II). *Drug Dev Res* 2004; 63: 200-211.
13. Manach C, Mazur A, Scalbert A. Polyphenols and prevention of cardio-vascular diseases. *Curr Opin Lipidol* 2005; 16: 77-84.
14. Organization for Economic Cooperation and Development (OECD) Guideline for the testing of chemicals (425). Acute oral toxicity-up-and-down procedure, 2001.
15. Kauffman GL, Grossman MI. Prostaglandin and cimetidine inhibit the formation of ulcers produced by parenteral salicylates. *Gastroenterology* 1978; 75: 1099-1102.
16. Njar VCO, Adesanwo JK, Raji Y. Methyl Angolensate: The antiulcer agent of the stem bark of *Etandrophragma angolense*. *Planta Medica* 1995; 16: 91-92.
17. Cheng CL, Koo MWL. Effect of *Centella asiatica* on ethanol induced gastric mucosal lesions in rats. *Life Sciences* 2000; 67: 2647-2653.
18. Bou-Abboud CF, Wayland H, Panlsen G, Guth PH. Microcirculatory stasis precedes tissue necrosis in ethanol-induced gastric mucosal injury in rat. *Dig Dis Sci* 1988; 33: 872-877.
19. Tsukimi Y, Nozue C, Okabe S. Effects of teminoprazole, omeprazole and sucralfate on indomethacin-induced delayed healing of kissing gastric ulcers in rats. *J Gastroenterol Hepatol* 1996; 11: 335-340.
20. Salim AS. Removing oxygen-derived free radicals stimulates healing of ethanol induced erosive gastritis in the rat. *Digestion* 1990; 47: 24-28.
21. Cheng CL, Guo JS, Luk J, Koo MWL. The healing effects of *Centella* extract and asiaticoside on acetic acid induced gastric ulcers in rats. *Life Sciences* 2004; 74: 2237-2249.
22. Guo JS, Cheng CL, Koo M.WL. Inhibitory effects of *Centella asiatica* water extract and asiaticoside on inducible nitric oxide synthase during gastric ulcer healing in rats. *Planta Medica* 2004; 70: 1150-1154.
23. Chung KO, Kim BY, Lee MH, Kim YR, Chung HY, Park JH, Moon JO. *In vitro* and *in vivo* anti-inflammatory effect of oxyresveratrol from *Morus alba* L. *J Pharm Pharmacol* 2003; 55: 1695-700.
24. Swarnakar S, Ganguly K, Kundu P, Banerjee A, Maity P, Sharma AV. Curcumin regulates expression and activity of matrix metalloproteinases 9 and 2 during prevention and healing of indomethacin-induced gastric ulcer. *J Biol Chem* 2005; 280: 9409-9415.

Correspondence:

Mahmood Ameen Abdulla
Department of Molecular Medicine,
Faculty of Medicine, University of Malaya
50603 Kuala Lumpur
Malaysia

Phone: +603 7697 6604
Fax: +603 79676600
e-mail: khaaah@gmail.com

