

## Eosinophilic granuloma of the skull vault: A case report.

Alessia Imperato<sup>1</sup>, Domenico Gerardo Iacopino<sup>2</sup>, Francesca Graziano<sup>2</sup>, Carlo Guli<sup>2</sup>, Antonella Giugno<sup>2</sup>, Luigi Basile<sup>2</sup>, Rosario Maugeri<sup>2</sup>

<sup>1</sup>Department of Neurosciences and Reproductive and Odontostomatological Sciences, Division of Neurosurgery, University of Naples Federico II, Italy.

<sup>2</sup>Department of Experimental Biomedicine and Clinical Neurosciences, School of Medicine, Neurosurgical Clinic, University of Palermo, Italy.

### Abstract

**Background:** Eosinophilic granuloma is the benign form of Langerhans cell histiocytosis, a rare proliferative disorder. Skull osteolytic lesions are quite frequently encountered.

**Case report:** We report the case of a 16 year old boy who was admitted to our Department with a painful swelling left frontal mass. A diagnosis of eosinophilic granuloma was presumed on the basis of the neuroradiological findings. Surgical removal of the lesion was achieved and the bone defect reconstructed by autologous fibrin glue and a titanium mesh. Histopathology confirmed the diagnosis.

**Conclusion:** Although uncommon, eosinophilic granuloma should be considered in the differential diagnosis in case of an osteolytic calvarial lesion.

**Keywords:** Eosinophilic granuloma, Langerhans cell, Calvarial bone.

Accepted September 14, 2016

**Abbreviations:** EG: Eosinophilic Granuloma; LCH: Langerhans Cell Histiocytosis; CT: Computed Tomography; MRI: Magnetic Resonance Imaging

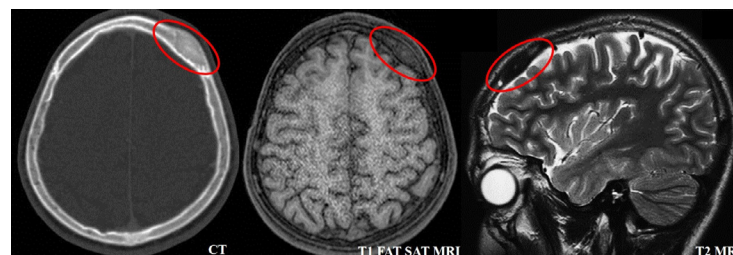
### Introduction

Eosinophilic granuloma (EG) is the mildest form of Langerhans cell histiocytosis (LCH), a rare proliferative disorder of Langerhans type histiocytes with an unknown etiology. EG predominantly affects children, adolescents and young adults. Its skeletal manifestations most often involve flat bones, with more than 50% found in the skull, spine, mandibula, ribs and pelvis [1]. Bone lesions have varied and nonspecific radiographic appearances. Eosinophilic

granuloma generally follows a benign clinical course [2]. The two main prognostic factors for the disease are patient age and extent of organ involvement. Bone lesions can be treated conservatively after biopsy to confirm the diagnosis [3]. Additional local therapy may be used for painful lesions, lesions with a risk of pathological fracture, or unacceptable dysfunction or deformity.

### Case

A 16 year old boy was referred to our Institution, complaining of several months history of frontal headache. He was alert and conscious, without neurological deficits. On general examination a tender, painful, left frontal mass was found.



**Figure 1.** Radiological aspect of an eosinophilic granuloma of the skull vault. In the red circle, the lesion is highlighted: The CT scan shows the typical lytic lesion with involvement of both inner and outer table, without sclerotic rim. On MRI, the lesion appears isointense in T1 images and slightly hypointense in T2 without dural involvement

Routine blood tests and chest X-rays were unremarkable. Head computed tomography (CT) scan showed a single, left frontal, sharply round, osteolytic lesion without marginal sclerosis. Brain magnetic resonance imaging (MRI) confirmed a T1 isointense, slightly T2 hypointense cranial vault lesion (Figure 1). A diagnostic hypothesis of eosinophilic granuloma was made. A whole body CT scan was performed to rule out multisystemic involvement. Indication for surgical approach was justified by severe headache and shared apprehension about a lytic skull lesion: complete excision was obtained, the dura mater was found intact and the bone defect was covered with titanium mesh plate and autologous fibrin glue [4-7]. The patient recovered without complications and was discharged home within few days. Histological examination confirmed the hypothesis of an eosinophil granuloma. The patient underwent clinical and radiological follow up that showed neither residual disease nor recurrence also after 1 year.

## Discussion

Langerhans Cell Histiocytosis (LCH), previously known as histiocytosis X, is a rare proliferative disorder of bone marrow-derived antigen-presenting cells, whose clinical manifestations vary from a multisystem disease with organ dysfunction to solitary eosinophilic granuloma (EG). The role of genetic or immune system in the pathogenesis seems to be less understood as compared to other diseases [8-12]. The natural history and prognosis of LCH are highly variable, depending on the patient's age and involvement of vital organs such as liver, lungs, spleen, or hematopoietic system [13]. Eosinophilic granuloma is the benign form of three clinical variants. It is characterized by single or multiple skeletal lesions, characterized by proliferation of Langerhans cells with an abundance of eosinophils, lymphocytes and neutrophils that produce prostaglandins determining medullary bone resorption. It predominantly affects children, adolescents and young adults, with a male to female ratio of 2:1. Any bone can be involved, the more common sites being skull, mandible, spine, ribs and the long bones. The lesions may be asymptomatic and discovered incidentally. More often, the patient refers a tender, painful mass during several weeks to several months before diagnosis. Systemic symptoms may also be present, including general fatigue and, more rarely, fever with leucocytosis. Laboratory findings are generally normal except for rare cases of eosinophilia [14]. On standard X-rays EG appears as a punched out lytic lesion without sclerotic rim; it may show a double contour or a bevelled edge due to greater involvement of the inner more than the outer table. On CT scan it can be better appreciated the cortical erosion and the soft tissue involvement. At MRI, T1 images typically show low signal, on T2 it can be isointense or hyperintense; contrast enhancement can be present [15]. Differential diagnosis of a solitary lytic skull lesion in a child or young adult includes epidermoid or dermoid cysts, as well as other benign and malignant skull tumours such as osteoblastoma, haemangioma or osteogenic sarcoma.

Treatment for calvarial EG has classically involved excision of the lesion or curettage, depending on the size of the

defect. Spontaneous healing of EG in other sites has been reported, but most calvarial lesions are immediately referred for excision. Oliveira et al. reported 4 cases of spontaneous disappearance of calvarial EG: the lesions increased in size initially and then became smaller and disappeared within 3–4 months [16,17]. More recently De Angulo et al. [18] described 8 cases of skull lesions that were managed conservatively: only one patient needed resection because of persistent pain and slight growth of the lesion. What have been postulated is that the chances of spontaneous remission of EG are higher in skeletally immature patients than in mature patients [19]. Conservative approach may have a fallback for lacking histological diagnosis, considering that these kinds of lesions include many benign as well as malignant conditions.

Recurrent lesions can be managed with irradiation, while multi-organ disease requires systemic chemotherapy to bone marrow transplantation [20,21].

## Conclusion

Eosinophilic granuloma is a benign disorder that affects children and young adults, particularly males. The clinical and radiographic findings are often not specific enough to determine the diagnosis. Nevertheless, CT scan and MRI play an important role in determining osseous perforation and the presence of extradural or extracranial soft-tissue mass. For symptomatic single skull lesions, surgical excision remains the main treatment option.

## References

1. Kim YJ. Rapid growing eosinophilic granuloma in skull after minor trauma. *Korean J Neurotrauma* 2015; 11: 22–25.
2. Lam S. Eosinophilic granuloma/Langerhans cell histiocytosis: Pediatric neurosurgery update. *Surg Neurol Int* 2015; 6: S435–S439.
3. Bülent EROL. Long-term follow-up of long and flat bone Eosinophilic granulomas managed only with biopsy. *Acta Orthop Traumatol Turc* 2015; 49: 144-150.
4. Graziano F, Maugeri R, Basile L, et al. Autologous fibrin sealant (Vivostat®) in the neurosurgical practice: Part II: Vertebro-spinal procedures. *Surg Neurol Int* 2016; 25: S77-82.
5. Graziano F, Certo F, Basile L, et al. Autologous fibrin sealant (Vivostat®) in the neurosurgical practice: Part I: Intracranial surgical procedure. *Surg Neurol Int.* 2015; 12: 77.
6. Giugno A, Maugeri R, D'Arpa S, et al. Complex reconstructive surgery following removal of extra-intracranial meningiomas, including the use of autologous fibrin glue and a pedicled muscle flap. *Interdisciplinary Neurosurgery* 2014; 1: 84-87.
7. Maugeri R, Basile L, Giugno A, et al. Impasse in the management of recurrent basal cell carcinoma of the skull with sagittal sinus erosion. *Interdiscip. Neurosurg* 2015; 2: 160–163.
8. Gioffredi A, Maritati F, Oliva E, et al. Eosinophilic

- granulomatosis with polyangiitis: An overview. *Front Immunol* 2014; 5: 549.
9. La Torre D, Maugeri R, Angileri FF, et al. Human leukocyte antigen frequency in human high-grade gliomas: A case-control study in Sicily. *Neurosurgery* 2009; 64: 1082-1088.
  10. Arena S, Minutoli L, Arena F, et al. Polydeoxyribonucleotide administration improves the intra-testicular vascularization in rat experimental varicocele. *Fertil Steril* 2012; 97: 165-168.
  11. Minutoli L, Arena S, Bonvissuto G, et al. Activation of adenosine A2A receptors by polydeoxyribonucleotide increases vascular endothelial growth factor and protects against testicular damage induced by experimental varicocele in rats. *Fertil Steril* 2011; 95: 1510-1513.
  12. Grasso G, Meli F, Fodale V, et al. Neuroprotective potential of erythropoietin and darbepoetin alfa in an experimental model of sciatic nerve injury. *Laboratory investigation. J Neurosurg Spine* 2007; 7: 645-651.
  13. Park SH. Eosinophilic granuloma of the skull: A retrospective analysis. *Pediatr Neurosurg* 2007; 43: 97-101.
  14. Rawlings CE 3<sup>rd</sup>. Solitary Eosinophilic granuloma of the skull. *Neurosurgery* 1984; 15: 155-161.
  15. Inci MF, Inci R, Ozkan F. Multidetector CT findings of calvarial Eosinophilic granuloma. *BMJ Case Rep* 2013.
  16. Oliveira M, Steinbok P, Wu J, et al. Spontaneous resolution of calvarial eosinophilic granuloma in children. *Pediatr Neurosurg* 2003; 38: 247-252.
  17. Alexiou GA. Cranial unifocal Langerhans cell histiocytosis in children. *J Pediatr Surg* 2009; 44: 571-574.
  18. De Angulo G. Non-operative management of solitary eosinophilic granulomas of the calvaria. *J Neurosurg Pediatrics* 2013; 12: 1-5.
  19. Plasschaert F, Craig C, Bell R, et al. Eosinophilic granuloma. A different behaviour in children than in adults. *J Bone Joint Surg Br* 2002; 84: 870-872.
  20. <https://clinicaltrials.gov/ct2/show/NCT00488605>
  21. Martinez-Lage JF. Solitary eosinophilic granuloma of the pediatric skull and spine. The role of surgery. *Childs Nerv Syst* 1991; 7: 448-451.

**Correspondence to:**

Domenico Gerardo Iacopino,  
Department of Experimental Biomedicine and Clinical  
Neurosciences,  
School of Medicine,  
Neurosurgical Clinic,  
University of Palermo,  
Via del Vespro 129, 90100, Palermo,  
Italy.  
Tel: +390916554299  
Fax: +390916552393  
E-mail: gerardo.iacopino@unipa.com