

Berberine Protects Against murine malaria-Induced Spleen Tissue Damage.

Mohamed A. Dkhil^{1,2,*}, Ahmed S. Alazzouni², Saleh Al-Quraishy¹, Ahmed Al-Shamrany¹, Mahmoud Y. Lubbad^{1,3}, Esam M. Al-Shaebi¹, Noory T. Taib¹

¹Department of Zoology, College of Science, King Saud University, Saudi Arabia

²Department of Zoology and Entomology, Faculty of Science, Helwan University, Egypt

³General Directorate of Environmental and Occupational Health, Public Health Agency, Ministry of Health, Riyadh, Saudi Arabia

Abstract

Malaria is one of the most severe public health problems worldwide. Here, we investigated the ameliorative role of berberine against *Plasmodium chabaudi*-induced spleen injury. Mice were divided into 3 groups. The first group served as a vehicle control, the second group was infected with 10^3 *P. chabaudi* infected erythrocytes and the third group was infected with *P. chabaudi* then treated with 10 mg/kg berberine for 10 days. Berberine was significantly able to lower the percentage of parasitemia. The infection induced splenomegaly and spleen injury. This was evidenced by fused splenic white pulp areas, diffuses appearance of the marginal zones, and increased number of macrophages in the red pulp. These changes in spleen led to the increased histological score. Berberine treatment caused a marked improvement in the splenic architecture and could offer protection against spleen tissue injury. Further studies are required to know the mechanism of berberine action against murine malaria.

Keywords: Berberine; malaria; spleen; mice.

Accepted February 07 2015

Introduction

Malaria is still a major health threat, however a safe and effective anti-malaria vaccine is not available [1]. This is somewhat astonishing as natural immunity can be acquired against the blood stages of the infectious agents, protozoan parasites of the genus *Plasmodium* [2].

A convenient model is the blood-stage malaria *Plasmodium chabaudi*, which shares several characteristics with the most virulent human-pathogenic species *P. falciparum* [3]. This has urged on intensive drug discovery endeavors geared towards identifying novel, potent and cheap anti-malarial drugs. However, the identification of quality leads from natural sources would significantly augment these efforts.

Berberine is an alkaloid extracted from various plants used in Traditional Chinese Medicine [4]. Previous studies have shown that berberine has a wide-ranging pharmacological and biological activities including anti-protozoal infection [5].

The spleen is widely assumed as to be the major effector site against blood-stage malaria [6,7]. The present study

was aimed to investigate the ameliorative role of berberine against *Plasmodium chabaudi*-induced spleen tissue damage.

Materials and methods

Animals

Twenty-four male Swiss albino mice were bred under specified pathogen-free conditions and fed a standard diet and water *ad libitum*. The experiments were performed only with mice at an age of 9-11 weeks and were approved by state authorities and followed Saudi Arabian rules for animal protection.

Plasmodium chabaudi infection

Blood stages of *P. chabaudi* were weekly examined in mice. Experimental animals were challenged with 10^3 *P. chabaudi*-parasitized erythrocytes. Parasitemia was evaluated in Giemsa stained blood smears, and total erythrocytes were counted in a Neubauer chamber.

Experimental design

Mice were allocated into three groups. The first group was the non-infected control group. The second and the third groups were infected with 1000 *Plasmodium cha-*

baudi-parasitized erythrocytes. The third group was orally inoculated with 10 mg/kg berberine chloride for 10 days [8]. Animals were dissected after 10 days post-infection with *P. chabaudi*.

Spleen histopathology

Mice spleens were fixed in neutral buffered formalin and then embedded in paraffin. Sections of 5 μ m thickness were stained with hematoxylin and eosin. To evaluate the splenic histological alteration, a semi-quantitative scoring system was used [9]. Segments of spleen were scored for the enlargement of white pulp areas (0, absent; 1, slight; 2, moderate; and 3, pronounced) and for the increased numbers of apoptotic cells, macrophages, necrotic cells and presence of pigments (0, absent; and 1, present). Scoring of each tissue sample represented the mean score of high microscopic power fields of five different sections.

The change in capsule thickness was calculated in 5 different fields in the spleen of each mouse.

Statistical analysis

Student's t-test was performed and $P \leq 0.05$ is considered to be statistically significant.

Results

On day 10 postinfection with *P. chabaudi*, the parasitemia was approximately 39 %. Berberine significantly decreased the parasitemia to about 15%. Moreover, splenomegaly in mice was evident at day 10 post-infected with *P. chabaudi* (Fig. 1). This was indicated by the determination of the splenic index (ratio of spleen weight to the mice weight) (Fig. 2).

Berberine was able to reduce the increased spleen index (Fig. 2).

In the histological level, spleen white pulps appeared enlarged due to cellular proliferation. The limit between white and red pulp at the histological level, started to disappear (Fig. 3).

Infection induced splenic vacuolation of some cells. Also, most of the cells were darkly stained and the sinusoidal spaces became larger. The histological lesion showed some improvements after treatment with berberine (Fig. 3, 4). Treatment of infected mice with berberine could improve the splenic architecture (Fig. 3,4).

Also, the capsule of the spleen was decreased in thickness compared to that of the control spleen (Fig. 5). Berberine was able to improve the change in spleen thickness (Fig. 5).

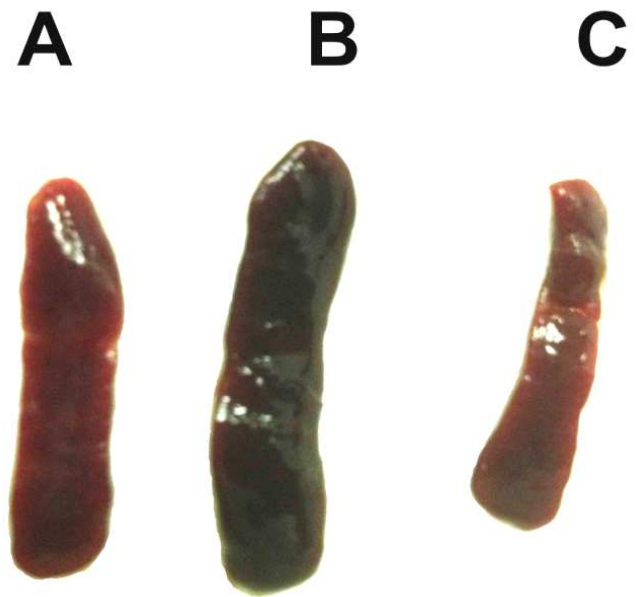


Figure 1. Change in spleen size. (A), Non-infected spleen with normal appearance. (B), Infected spleen at day 10 p.i. Spleen appears dark brown and enlarged. (C), Infected-treated mice with berberine.

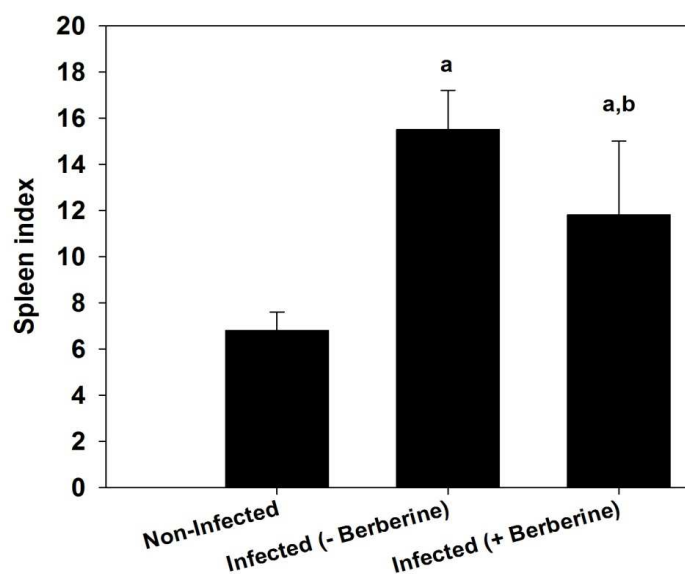


Figure 2. Increase in splenic index on day 10 post-infected with *P. chabaudi* parasitized erythrocytes.

Values are means \pm SD. a: Significant change at $P \leq 0.05$ with respect to control non-infected mice. b: Significant change at $P \leq 0.05$ between infected mice (- berberine) and infected mice (+ berberine).

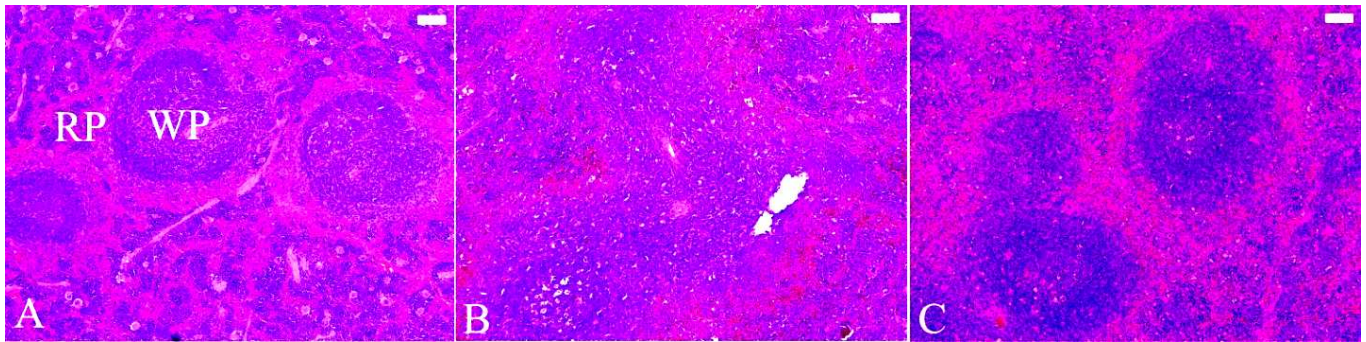


Figure 3. Berberine improved spleen histopathological changes induced by *P. chabaudi*-parasitized erythrocytes. (A), Non-infected spleen with normal architecture. (B), Infected spleen at day 10 post infection. White pulp (WP) is starting to fuse together. Spleen appears with numerous hemozoin granules and infected erythrocytes in the red pulp (RP). (C), Infected-treated mice with berberine. Spleen appeared with less lesion and improved tissue damage. Sections are stained with hematoxylin and eosin. Bar = 50 μ m.

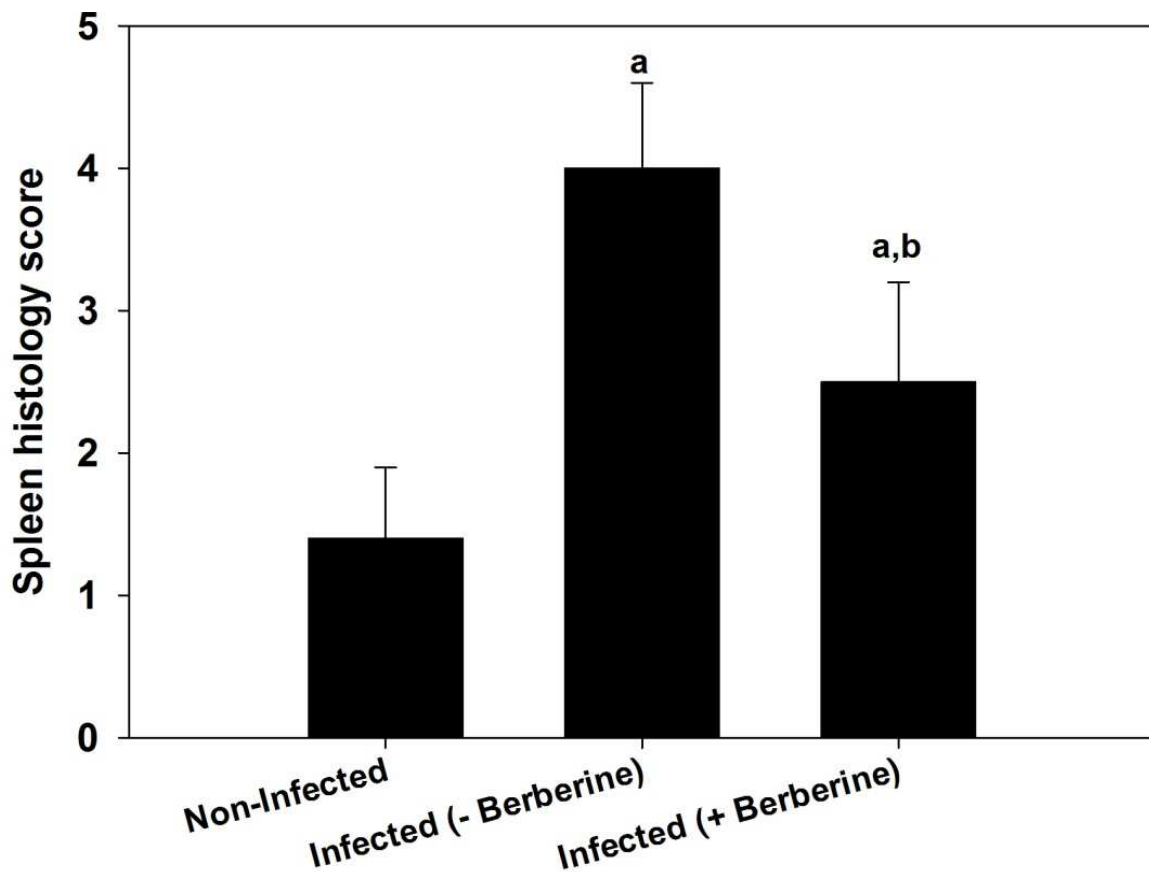


Figure 4. Berberine-induced changes in spleen histology score. Values are means \pm SD. a: Significant change at $P \leq 0.05$ with respect to control non-infected mice. b: Significant change at $P \leq 0.05$ between infected mice (- berberine) and infected mice(+ berberine).

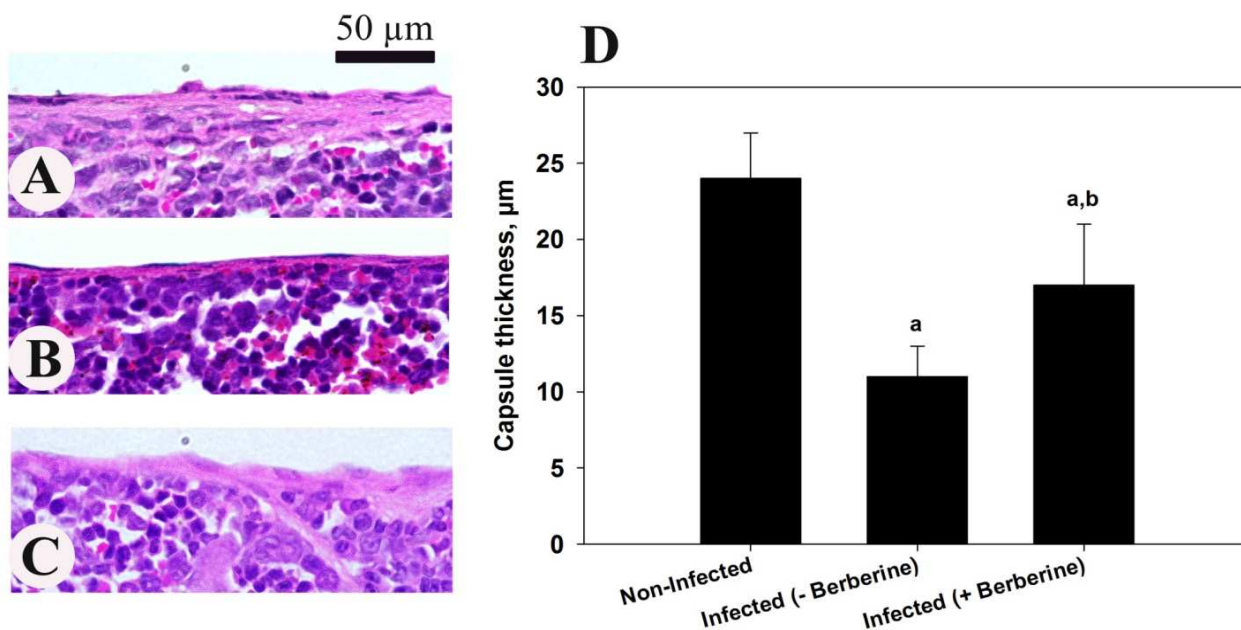


Figure 5. Berberine decreased spleen capsule thickness of mice infected with *P. chabaudi*-parasitized erythrocytes. (A), Non-infected spleen capsule with normal thickness. (B), Infected spleen capsule at day 10 post-infection. (C), Infected-treated mice with berberine. Spleen capsule appeared thicker than that of the infected spleens. (D) Change in spleen capsule thickness. Sections are stained with hematoxylin and eosin. Bar = 50 µm.

Discussion

The initial hope underlying the present study was to find a natural product with anti-malarial properties. Berberine was able to reduce the percentage of parasitemia on day 10 post-infection. The antimalarial activity of berberine and its ability to significantly decrease the number of infected erythrocytes. This clearance might be mediated by both acquired and innate immune responses [10].

Enlarged spleens, presumably be due to malaria and found in Egyptian mummies of more than 3000 years old, and the Ebers Papyrus (c. 1570 b.c.) mentioned splenomegaly, fevers and a variety of cures for such ailments [11]. The spleen is considered to be an effector against *P. chabaudi* Infection [7]. The widening of white and red pulps is due to splenomegaly where the spleen increases in size due to malaria infection. The splenomegaly due to infection with *P. chabaudi* has been reported by Dkhil [7]. Krueken et al. [6] stated that splenomegaly is due to increased number of macrophages [6].

The spleen histology is affected by malaria infection [7]. The splenic cells including T-cells and B-cells are disorganized during the infection. This led to changes in splenic architecture [7].

Berberine has significant antimicrobial activity against a variety of organisms [12] and has strong anti-malarial activities [13,14]. It has a high clearance rate of asexual

parasitemia [15]. It also inhibits telomerase activity of *P. falciparum* in a dose-dependent manner [16]. It interacts with plasmodium DNA effectively [17].

Our data indicate that berberine exhibits a significant anti-malarial activity and, protect host spleen tissue from injuries induced by *P. chabaudi*.

Acknowledgment

The authors would like to extend their sincere appreciations to the Deanship of Scientific Research at King Saud University for funding this Research group (RGP-198).

References

- Hill AV. Vaccines against malaria. *Philos Trans R Soc Lond B Biol Sci* 2011; 366: 2806-2814.
- Mehlhorn H. *Encyclopedic reference of parasitology: diseases, treatment, therapy*. Third edition. 2008.
- Stephens R, Culleton RL, Lamb TJ. The contribution of *Plasmodium chabaudi* to our understanding of malaria. *Trends Parasitol* 2012; 28: 73-78.
- Wongbutdee J. Physiological Effects of Berberine. Review article. *Thai Pharm Health Sci J* 2008; 4: 78-83.
- Malik TA, Kamili AN, Chishti MZ, et al. In vivo anticoccidial activity of berberine [18, 5,6-dihydro-9,10-dimethoxybenzo(g)-1,3-benzodioxolo(5,6-a) quinolizinium]--an isoquinoline alkaloid present in the root bark of *Berberis lycium*. *Phytomedicine* 2014; 15: 663-669.

6. Krücken J, Mehnert LI, Dkhil MA, et al. Massive destruction of malaria-parasitized red blood cells despite spleen closure. *Infect Immun* 2005; 73: 6390-6398.
7. Dkhil MA. Apoptotic changes induced in mice splenic tissue due to malaria infection. *J. Microbiol. Immunol Infect* 2009; 42:13-18.
8. Jahnke GD, Price CJ, Marr MC, et al. Developmental Toxicity Evaluation of Berberine in Rats and Mice. *Birth Defects Res* 2006; 77: 195-206.
9. Giamarellos-Bourboulis EJ, Tziortzioti V, Koutoukas P, et al. Clarithromycin is an effective immunomodulator in experimental pyelonephritis caused by pan-resistant *Klebsiella pneumoniae*. *J Antimicrob Chemother* 2006; 57: 937-944.
10. Trubowitz S, Mazek B. *Plasmodium falciparum*: phagocytosis by polymorphonuclear leukocytes. *Science* 1968; 162: 273-274.
11. Sherman IW. A brief history of malaria and discovery of the parasite's life cycle. In: *Malaria: parasite biology, pathogenesis, and protection* (ed. I.W. Sherman), American Society for Microbiology Press. Washington DC, 1998; pp. 3-10.
12. Chen C, Yu Z, Li Y, Fichna J, Storr M.. Effects of berberine in the gastrointestinal tract - a review of actions and therapeutic implications. *Am J Chin Med* 2014; 42:1053-1070.
13. Tran QL, Tezuka Y, Ueda JY, et al. In vitro antiplasmodial activity of antimalarial medicinal plants used in Vietnamese traditional medicine. *Ethnopharmacology* 2003; 86: 249-252.
14. Caraballo A, Caraballo B, Rodriguez-Acosta A. Preliminary assessment of medicinal plants used as antimalarials in the Southern of Venezuelan Amazon. *Rev Soc Bras Med Trop* 2004; 37: 186-188.
15. Sheng WD, Jiddawi MS, Hong XQ. Treatment of chloroquine-resistant malaria using pyrimethamine in combination with berberine, tetracycline or cotrimoxazole. *East Afr Med J* 1997; 74: 283-284.
16. Sriwilaijareon N, Petmitr S, Mutirangura A, Ponglikitmongkol M, Wilairat P. Stage specificity of *Plasmodium falciparum* telomerase and its inhibition by berberine. *Parasitol Int* 2002; 51: 99-103.
17. Talwalkar SS, Vaidya AB, Godse C, et al. Plasmodium DNA fluoresces with berberine: a novel approach for diagnosis of malarial parasites. *Am Clin Pathol* 2005; 124: 408-412.

Correspondence to:

Mohamed A. Dkhil
¹Department of Zoology,
College of Science,
King Saud University,
Saudi Arabia

²Department of Zoology and Entomology
Faculty of Science
Helwan University, Egypt