

Vascular Foramina of Scaphoid and its Clinical Implications

P.P Dubey, Navneet Kumar Chauhan, M.S. Siddiqui

Department of Anatomy , Chatrapati Shahuji Maharaj Medical University U.P., Lucknow. (U. P.)
Department of Anatomy, Era Medical Collage, Lucknow (U.P.), India

Abstract

The nutrient vascular foramina of scaphoid bone were observed and clinical interpretations were discussed. The 220 dry scaphoid bones of adult age group were studied. The vascular foramina distal to mid of waist were 1 to 2 in 17.72 % specimen and rest of 82.28% bones had more then 2 foramina. There was no scaphoid without vascular foramina distal to mid of waist of scaphoid. But the proximal part to mid of waist of scaphoid are without vascular foramina in 6% cases, one vascular foramina in 32.72% and more than one in 61.28% cases. These observations suggested more blood flow in the proximal part of scaphoid bone in comparison of other studies.

Key words. Scaphoid, Foramen, Carpal, Wrist, blood supply

Accepted December 13 2010

Introduction

The blood supply of carpal bone has been rich field for the workers in the 19th century. The vascular pattern put forward in correlation to gross anatomy, radiographic pattern of extraosseous and intraosseous blood vessels, observing the vascular foramina on the bones has been described. Oblatz & Halbstein [1] studied the vascular foramina visible on dried specimens of the human scaphoid and proposed a widely accepted concept of a predominantly distally based blood supply entering through the dorsal ridge. However, this concept has not been entirely supported by the results of more recent studies carried out by various investigators. The dorsal, laterovolar and distal group of feeding vessels enter in respective side of scaphoid bone [2]. The vasculature perforate the dorsal area of the scaphoid bone through numerous small foramina along the spiral groove and dorsal ridge [3].

The fracture and fraction dislocation of scaphoid is very common in wrist trauma and avascular necrosis is directly connected with vascular pattern of scaphoid.[4] In two-thirds of all cases, the scaphoid bone is most frequently fractured bone of the wrist, and it is uniformly vascularized, so that by fracture both fragments retain their blood supply. In the remaining third of all cases, only one end of the scaphoid is supplied arterially. Thus the poorly vascularized fragment frequently becomes necrotic [5]

We decided to study the vascular foramina as a parameter of blood supply of scaphoid and its possible relationship to fracture healing.

Material and Methods

The vascularization of scaphoid bone was estimated by counting of vascular foramina on dry scaphoid bone of adult age group of both sexes. The dry scaphoid bones were obtained from Department of Anatomy, Moti Lal Nehru Medical College, Allahabad (U.P.), Era Medical College, Lucknow (U.P.) and Chatrapati Shahuji Maharaj Medical University U.P. Lucknow. A total number of 220 scaphoid bones of both sides were selected for study. The non-articular along with articular surfaces of scaphoid bone were considered for observations. The foramina of scaphoid were taken as site of vessel entry. These foramina were counted on the surface of bones with the help of operating loop lens.

Observations

Dry, 220, scaphoid bones of both sides were taken for observations in present study. The scaphoid bones were not differentiated according to sex. The vascular foramina were found only on palmar and dorsal surfaces of scaphoid. The articular surfaces were devoid of any vascular entry. According to distribution of foramina, observations were grouped as under:

1. The numbers of foramina on the dorsal surface were counted on scaphoid bone. It was observed that these foramina are ranged from 1 to 10 in 14 (6.36%) specimens; foramina ranging 11 to 20 were present in 144 (65.45%) specimens and 21 to 32 foramina in 62 (28.18%) specimens. (Table 1; Figures 1,5)

- The number of vascular foramina on dorsal surface of scaphoid ranged between 4-32 whereas on palmar surface 1- 8 (Table 4) (Figures 2,4).
- It was observed that 6% specimens show no vascular foramina proximal to the mid of the waist while 32.72% specimens show one vascular foramen

proximal to the mid of waist and 61.28% (Figure-2, 3) specimens show more than one vascular foramina proximal to the mid of waist (Figure 3). Number of vascular foramina 1 to 2 distal to mid of waist 17.72% was present in specimens, and more than two in 82.28% specimens. (Tables 2,3)

Table 1. Grouping of Scaphoid according to the number of vascular foramina on dorsal surface

Group	Number of Foramina	Number of Specimen	Percentage
I	1-10	14	6.36%
II	11-20	144	65.45%
III	21-32	62	28.18%
Total		220	100%

Table 2. Grouping of Scaphoid according to number of vascular foramina proximal to the mid of waist

Group	Number of Foramina Proximal to the mid of waist	Number of Specimen	Percentage
I	0	13	6%
II	1	72	32.72%
III	>1	135	61.28%
Total		220	100%

Table 3. Grouping of Scaphoid according to the foramina present distal to mid of waist

Group	Number of Foramina distal to the mid of waist	Number of Specimen	Percentage
I	1-2	39	17.72%
II	>2	181	82.28%
Total		220	100%

Table 4. Number of Vascular Foramina on Dorsal and Palmar Surface

Surface	Maximum number of Foramina	Minimum number of Foramina	Ratio of Max./Min.
Dorsal	32	4	4:1
Palmar	8	1	4:1

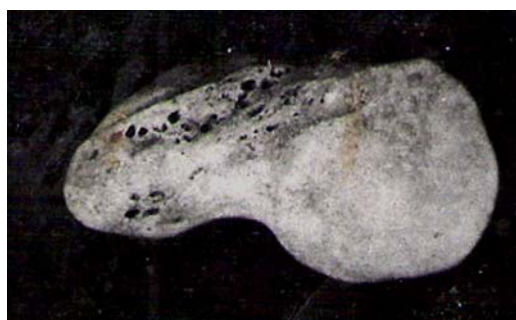

Figure 1. Vascular foramina at dorsal ridge and tubercle of scaphoid bone (dorsal view)

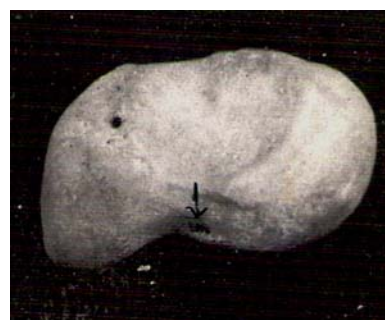

Figure 2. Vascular foramina at proximal part and one large foramen at base of tubercle of scaphoid bone (palmar view)

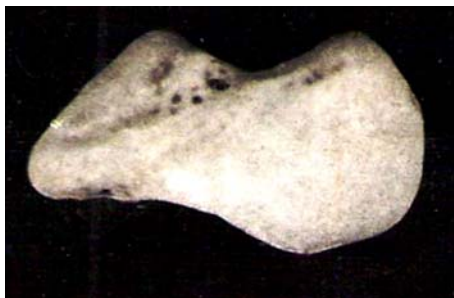

Figure.3. Vascular foramina at proximal part and mid of dorsal ridge of scaphoid bone (dorsal view)

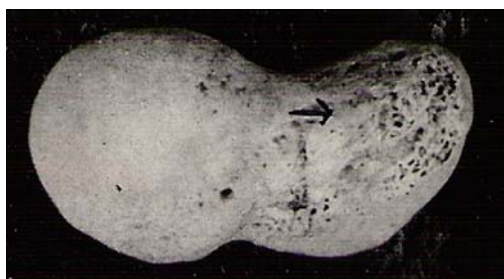


Figure 4. One vascular foramen at palmar surface and numerous foramina at tubercle of scaphoid bone (palmar view)

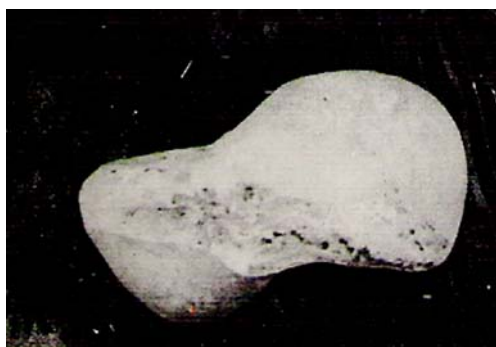

Figure.5. Vascular foramina at proximal part of dorsal ridge of scaphoid bone (dorsal view)

Discussion

In present study vascular foramina are noted in distal and proximal part on both palmar surface and dorsal surface of scaphoid. The vascular foramina distal to mid of waist are 1 to 2 in 17.72 % specimen and rest of bones having more then 2 foramina are 82.28%. There is no scaphoid without vascular foramina distal to mid of waist. But the proximal part to mid of waist of scaphoid are without vascular foramina in 6% cases, one vascular foramina in 32.72% and more than one in 61.28% cases. These foramina clearly suggest that the proximal part of scaphoid receives less blood supply. It can be predicted that 6% scaphoid are highly vulnerable and 32.72%

scaphoid are prone to avascular necrosis according our finding. Obletz & Halbstein (1938) described that 67% of individuals have 2 or more vascular foramina proximal to the waist, 20% have only one foramen proximally and 13% were found to have no proximal foramina. Thus, in one third of waist (mid) fractures, there will be diminished blood supply to the proximal fracture fragment this may produce a non-union and avascular necrosis may ensue.[1]. In present study 6% scaphoid were found without vascular foramina on proximal part. The blood supply of the scaphoid comes from radial artery. The proximal pole and 70-80% of bone receives their blood supply from vessels entering through dorsal ridge. The tuberosity and distal 20-30% of the bone are supplied by volar branches of radial artery and its superficial palmar branch [6]. The dorsal, proximal, near base of tubercle and radial part of volar surface of scaphoid is penetrated by branches of radial arteries. The numerous small vessels enter in scaphoid through the radio volar aspect [7]. These findings are similar to our finding; however Barber(1972) noted three groups of vessels, entering at various intervals along the dorsal ridge and branching to supply the tuberosity and the proximal pole [8]. He did not find any vessels entering the scaphoid through its volar surface. According to Fasal et al(1978) a branch of the arteria radialis or of the ramus dorsalis arteriae radialis enters the dorsal surface in the middle and distal third by several foramina whereas the proximal third of the scaphoid showed no vascular foramen [9]. The location and distribution of the vascular foramina visible along the dorsal ridge of a dried scaphoid would account for the occurrence and incidence of aseptic necrosis of the proximal pole of the scaphoid following fracture through the waist.[10] Our series consistently demonstrated the presence of foramina confined to the dorsal ridge of the scaphoid. These did not correspond to the division into a dorsal and laterovolar arterial supply of the proximal pole suggested by Taleisnik & Kelly (1966) [2]. The main blood vessels came from the dorsal and the radial side of wrist and passed through the whole scaphoid along the crest of scaphoid.[11]. A good blood supply of the scaphoid bone from palmar, dorsal and radial vessel groups with a variety of anastomoses provide sufficient collateral blood flow from adjacent regions. Since blood supply is available from the palmar circulation, a dorsal approach to the scaphoid bone is possible. [12]. Osteonecrosis is said to occur in 13%–50% of cases of fracture of the scaphoid, and the incidence of osteonecrosis is even higher in those with involvement of the proximal one-fifth of the scaphoid. [4]. Dawson et.al.(2001) found that the rate of nonunion of scaphoid fracture is 12% which is similar to other studies (10% to 13%) when fractures of the scaphoid were treated conservatively. [13].

Finally we can conclude that 6% scaphoid are without foramina, 32.72% scaphoid with one foramen and 61.28% scaphoid with more than one foramen on proximal part.

The dorsal surface has four times more foramina than palmar surface. These observations indicate that there is higher blood supply in proximal part of scaphoid in comparison of other studies. The surgical approach for scaphoid may be from both dorsal and palmar aspect as vascular foramina present in both surface of scaphoid.

References

1. Oblatz BE, Halbstein BM. Non-union of fractures of the carpal navicular. *J Bone Joint Surg*; 1938; 20:424-8.
2. Taleisnik J, Kelly P. The extraosseous and intraosseous blood supply of the scaphoid bone. *Journal of Bone and Joint Surgery*; 1966; 44(A), 1125-1137
3. Gelberman, PH, Menon J. The vascularity of the scaphoid bone. *J Hand Surg* 1980; 5: 508-513
4. Scott P, Steinmann and Julie E. Adams Scaphoid fractures and nonunions: diagnosis and treatment *J Orthop Sci*. 2006; July; 11(4): 424-431
5. Oehmke HJ. Blood supply and function of the scaphoid bone *Unfallchirurgie*. 1987 Jun; 13(3): 174-177.
6. Gelberman RH, Bauman TD, Menon J. The vascularity of the Lunate bone and Kienbock's Disease. *J Hand Surg* 1980; 5: 272-278.
7. Greville, S. Arterial anatomy of the carpal bones; *Acta Anatomica*. 1955; 25: 331-345.
8. Barber, H. The intraosseous arterial anatomy of the adult human; *Carpus orthopaedics*. 1972; 5: 1-19.
9. Fasol P, Munk P, Strickner M. Blood supply of the scaphoid bone of the hand; *Acta Anat (Basel)* 1978; 100(1): 27-33
10. Handley RC, Pooley J. The venous anatomy of scaphoid. *J. Anat.* 1991; 178: 155 -118.
11. Kong WY, Xu YQ, Wang YF, Chen SC, Liu ZL, Li XG; Anatomic measurement of wrist scaphoid and its clinical significance *Chin. J. Traumatol*. 2009; 12(1): 41-44.
12. Oehmke MJ, Podranski T, Klaus R, Knolle E, Weindel S, Rein S, HJ. The blood supply of the scaphoid bone. *J Hand Surg Eur* 2009; 34(3):351-357
13. Dawson JS, Martel AL, Davis TRC. Scaphoid blood flow and acute fracture healing; A dynamic MRI study with enhancement with Gadolinium; *J Bone Joint Surg [Br]* 2001; 83-B: 809-14

Correspondence to:

P.P. Dubey
Department of Anatomy
Era Medical College, Lucknow (U.P.)
India

