



## Tuberculosis presenting as epiglottitis – A diagnostic dilemma

FAHIM AHMED SHAH SUNIL. GEORGE HASAN ABDUL CADER S.K.G.NAIR REGHUNANDANAN K

Sur Hospital, South Sharqiya, region Sultanate of Oman.

### Abstract

We report a rare case of laryngeal tuberculosis in Oman Tuberculous affection of larynx is uncommon in Oman and is rarely been reported. Tuberculosis is a chronic illness, acute clinical presentation is unusual. We report the case of a thirty One year old lady, post renal transplant with tuberculous involvement of the larynx, who presented with symptoms and clinical signs of acute epiglottitis. ENT examination showed initially a severely swollen epiglottis which turned nodular in about two weeks. The patient had been on immunosuppressive medications and glucocorticoids post renal transplant. Tuberculosis still presents sporadically in countries where the overall incidence of tuberculosis is much lower as compared to developing countries. A strong index of suspicion is needed in immunocompromised patients with suboptimal response to routine medications. Diagnostic difficulty in this peculiar situation with differential diagnosis and management of laryngeal tuberculosis is discussed along with review of literature.

## **Introduction**

Tuberculosis is regarded as a communicable disease worldwide being one of the most common diseases in developing countries. After the introduction of anti-tuberculosis therapy and immunization, the incidence of tuberculosis has decreased globally.

Acute epiglottitis is a relatively uncommon disease in both children and adults. It is an acute inflammation of the epiglottis and adjoining structures. Because the mucosa of the epiglottic region is loose and vascular, its inflammation may rapidly cause edema and vascular engorgement resulting in complete upper airway obstruction and sudden death. Acute epiglottitis should be suspected in all patients with a history of sore throat and odynophagia, especially if symptoms are out of proportion to pharyngeal findings.

Adult epiglottitis is different from its pediatric counterpart in that organism identification is less common, the clinical course is more gradual, there is less seasonal variation, airway compromise is uncommon, and conservative airway management can be contemplated in selected patients.

## **Case report**

A thirty one year old lady was referred to our clinic from nephrology department with progressively worsening complaints of difficulty in swallowing liquids. She had odynophagia, throat pain, change in voice and noisy breathing of five days duration. Going through her recent past history it was noted that she had visited other clinics with complaints of throat irritation and dry cough for about a month and had been given symptomatic treatment. She had undergone a renal transplant about two years before. She also reported a weight loss of about 19 kilograms over last five months with loss of appetite and fever with sweating.

On examination there was mild stridor and drooling of saliva without any respiratory distress. Clinical examination revealed no remarkable findings except glossitis.

Indirect laryngoscopy revealed a diffuse swollen epiglottis and salivary pooling. Bilateral tender diffuse level three soft cervical nodes were palpable. X-ray soft tissue neck revealed a swollen epiglottis-the "thumb sign". X-ray chest taken one week ago when she presented to another clinic with cough showed left lower zone opacity. She was promptly admitted into high dependency care and was started on treatment for acute epiglottitis - ceftriaxone, metronidazole, nebulisations and supportive care. She improved symptomatically and was shifted from high dependency care after two days to regular ward for continuation of treatment. Her initial blood investigations including blood counts, random blood sugar, electrolytes, liver function tests, renal function tests, and thyroid function tests were within normal limits. ESR was 40 mm per first hour and C reactive protein was elevated. Flexible laryngoscopy was done after two days once the patient's vital signs stabilized and she started feeling comfortable. It revealed reduction of the diffuse supraglottic swelling and salivary pooling. No other abnormalities were detected in the laryngopharynx.

Both vocal cords were congested but mobile.

Two weeks after admission she was symptom free with regard to her throat symptoms and had improved appetite. Her neck nodes were palpable but non tender and much smaller. However she started getting daily morning spike of fever. Laryngoscopy showed that the diffuse epiglottic swelling had become rather nodular with persisting swelling of aryepiglottic folds, arytenoids and ventricular bands. Consent for laryngeal biopsy was not given.

X-ray chest was repeated three weeks after admission. It showed bilateral diffuse infiltrates suggestive of miliary tuberculosis though the opacities were slightly larger than miliary shadows. HRCT scan chest showed diffuse scattered small well defined nodules in both lungs. A few scattered centrilobular nodules and 'tree in bud' appearance was noted in apices, posterior segment of right upper lobe and apico-posterior segment of left upper lobe. There was no evidence of any cavity, bronchiectasis, hilar lymphadenopathy or pleural effusion. CT chest was suggestive of miliary tuberculosis with associated endobronchial spread of infection.

The patient was promptly started on four drug antituberculous treatment with modification of her immunosuppressive regimen. Within a week of starting treatment she was afebrile. Four to five weeks after initial presentation she made dramatic progress with good appetite and weight gain. Repeat laryngoscopy now revealed a reduced epiglottic swelling though still nodular in appearance. She is under follow up with physicians, nephrologists and ENT specialists.

## **Discussion**

In the pre antibiotic era Tuberculosis of the larynx was a common complication of advanced primary tuberculosis with cavitary lesions as the tubercular bacilli involved the larynx when the infective sputum was coughed up. Rarely does it disseminate via lymphatics or blood. The incidence was further increased in patients suffering from HIV infection due to poor host reaction.

Tuberculosis of the larynx<sup>2</sup> can occur secondarily as a complication of active or inactive pulmonary tuberculosis or primarily by direct infection of laryngeal mucosa by organisms via aerosolized particles resulting in granulomatous formation.

The most common ENT manifestation of tuberculosis is tuberculous laryngitis<sup>3</sup> which was more common in patients diagnosed to have pulmonary tuberculosis especially defaulters of previous antituberculous therapy and relapse cases. In adults laryngeal tuberculosis is invariably secondary to pulmonary tuberculosis<sup>4</sup> while in children usually there is no evidence of pulmonary disease and their chest X-rays at presentation is usually

normal. Laryngeal tuberculosis can occur irrespective of the immunization status and result of tuberculin test could be negative.

The subepithelial tubercle (granuloma) has central caseation ringed by epithelioid cells with mononuclear cells in the periphery. Fibrosis then starts at the periphery of tubercles and replaces the tubercle. A secondary infection usually causes ulceration, perichondritis, chondritis (deformity) and cricoarytenoid joint destruction. Oedema of epiglottis and arytenoids occur due to lymphatic obstruction. Epithelial hyperplasia, papillary granulomatous masses, fibrosis and stenosis complete the picture.

Diagnosis is clinched by clinical examination and investigations for tuberculosis.

Laryngoscopy reveals congestion of posterior end of vocal cords and interarytenoid area, interarytenoid heaping and crusting, swollen or "turban" epiglottis, roughening and erosion of vocal cords with saw-tooth appearance, shallow exudate covered ulcer of vocal cord – "mouse eaten" appearance. In later stage ulceration, oedema, granuloma formation with vocal cord fixation or paralysis results. Laryngeal biopsy may be required to distinguish from other granulomatous conditions and malignancy. Treatment with antituberculous medicines shows rapid response and prompt relief of symptoms. Rarely surgical intervention is required for airway obstruction

### **Conclusion**

A strong suspicion of laryngeal tuberculosis in this patient arose due to her immunocompromised state, development of spikes of fever, weight loss, development of nodular appearance of epiglottis and unsatisfactory response to treatment for acute epiglottitis.

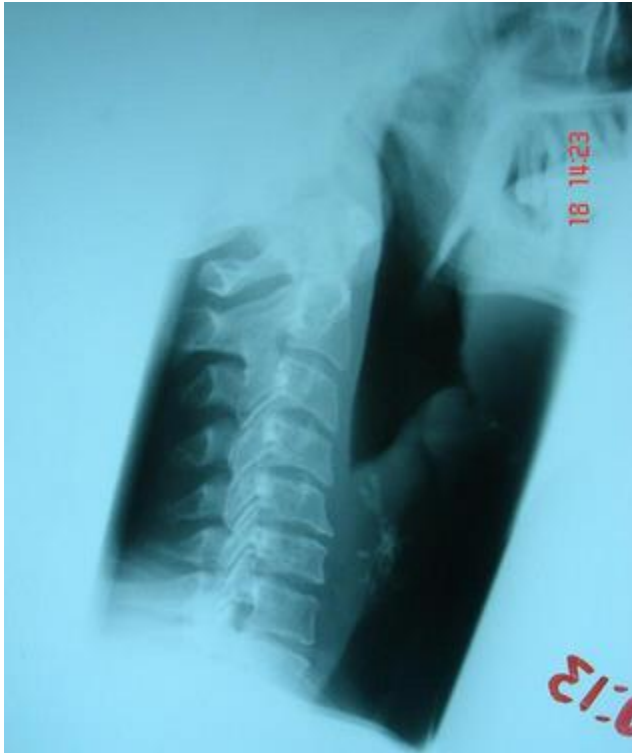We were unable to reach an earlier diagnosis because of the rarity of laryngeal tuberculosis in Oman and because of the acute presentation and partial initial symptomatic response to antibiotics. Patient's steadfast refusal of laryngeal biopsy and negative initial Xrays

and investigations for tuberculosis were additional difficulties. We are now led to think that this was primarily a case of laryngeal tuberculosis with misleading clinical picture and investigations probably because of the immunosuppressive medications and steroids that the patient was using post renal transplant. However whether the larynx or the lung was the primary focus of tuberculosis will remain a matter of conjecture like the proverbial hen and egg situation.

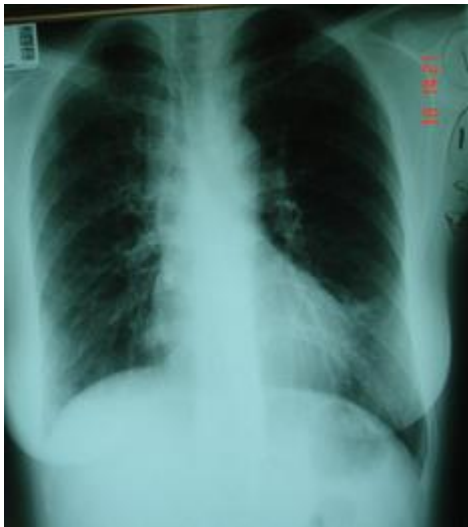
### **References**

1. Morales PJM, Padilla PM, Diaz SMA, et al. Laryngeal tuberculosis, an incidence between 1994 and 2004. *An Otorrinolaringolbero Am* 2006; 33(6):591-8.
2. Coscaron BE, Santa Cruz RS, SerradillaLJM. Tuberculousepiglotittis an atypical form of laryngeal tuberculosis. Presentation of a case and review of literature. *An Otorrinolaringolbero Am* 2005; 32(1):55-63.
3. Krecicki T, Zalessska-Krecicta M, Zatonski T, etal. Laryngeal tuberculosis. *Lancet Infect Dis* 2004(1):57.
4. S Kumar, Tuberculosis in Otorhinolaryngology. In: SK Sharma, A Mohan. *Text Book of Tuberculosis*; Reprint New Delhi: Jaypee; 2004: 285-

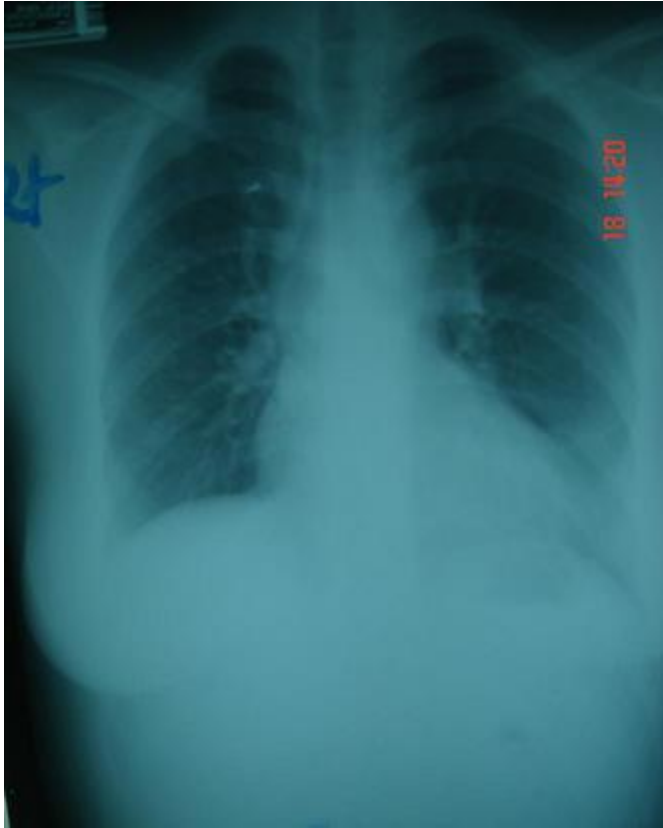
**Figures:**



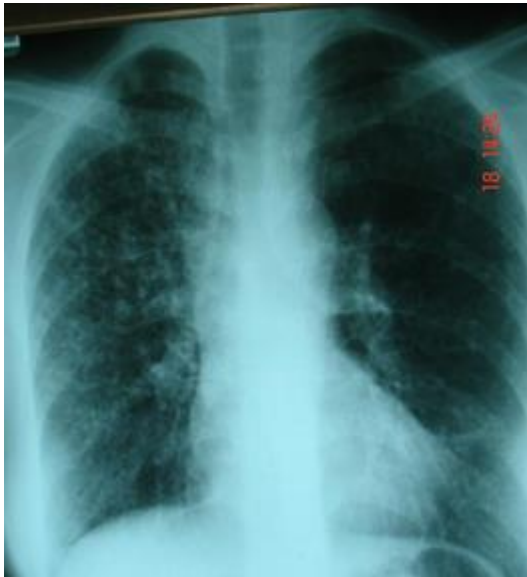Patient's X-ray soft tissue neck showing swollen epiglottis: "The thumb sign"



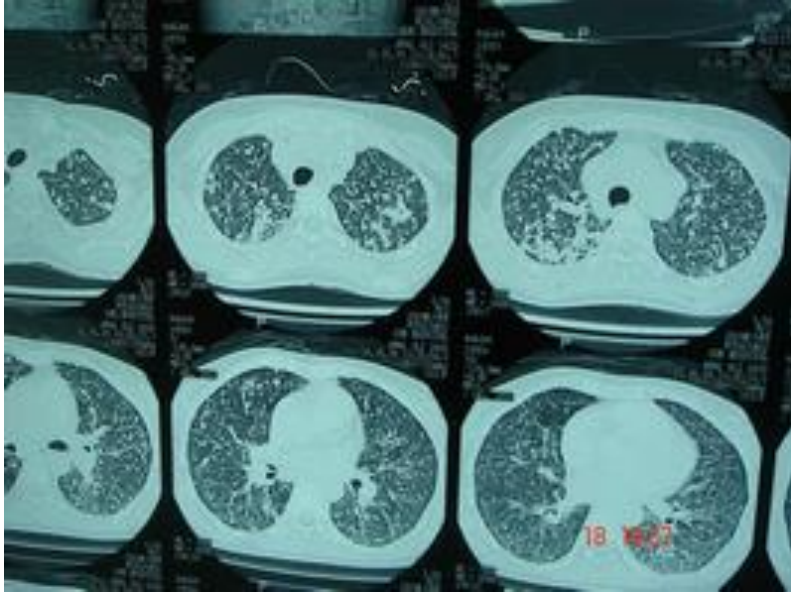
X-ray chest taken about a week before admission to ENT department



X-ray chest two weeks after admission showing diffuse reticulonodular shadows



X-ray chest 3 weeks after admission showing suspicious miliary opacities



CT scan of the thorax showing fine nodular opacities suggestive of miliary tuberculosis