



## ***Teflon nasal splints in nasal surgeries: advantages over conventional nasal packing***

*Sudhir M Naik , Ravishankar B Shashikumar T, Deekshith T , Sherry C , Pooja N , Sathya P*

*KVGMC Sullia Karnataka*

***Key word 1: teflon septal splint.***

***Key word 2: framycetin pack.***

***Key word 3: septoplasty.***

***Key word 4: endoscopic sinus surgery.***

***Key word 5: rhinoplasty.***

### **Abstract:**

***Background & Objectives:*** Nasal splints have long been used to prevent post operative nasal adhesions in septal surgery. But its efficacy in reducing adhesions and residual deviations are still controversial. Teflon is an inert material used as septal splints with sieves are used in our study as splints.

***Materials and methods:*** This is a comparative case series study done in 214 cases of septoplasties. 116 postoperative cases were packed with framycetin packs only and the other 98 cases by framycetin packs and teflon septal splints. The groups were compared for postoperative nasal adhesions, residual deviation , pain , septal perforations and subjective patient satisfaction.

*Result: The rates of adhesion and pain on VAS scale showed no significant difference in the splinted and non splinted group. Pain was more with the splints even after pack removal. Residual deviation was reduced with these teflon nasal septal splints.*

*Conclusion: Nasal septal splint does not significantly reduce the adhesions after septoplasty but are effective in reducing the residual deviations. The pain and discomfort are more with the splints. Post operative adhesions are better reduced by nasal irrigation and manual cleaning of the cavities by antibiotic ointments.*

## *Introduction:*

*Surgeries on the nasal septum are the commonest procedures in rhinology which are performed alone or in combination with endoscopic sinus surgeries, turbinectomies, turbinoplasties and rhinoplasties.<sup>1</sup> Packing the nasal cavities after surgery are not only important to control bleeding but also the pack stabilizes the cartilaginous and bony framework of the nose after surgery.<sup>2</sup> Also packs prevent complications of septal surgeries like hematoma, infection, abscess formation and perforation.<sup>3</sup>*

*These septal surgeries are always complicated by adhesions formation between the septum and the lateral wall.<sup>4</sup> The complications of adhesions are more if turbinate surgeries are done along with the septal correction.<sup>4</sup> The incidence of adhesions are high as 36% depending on the raw surfaces on the turbinates and the septum.<sup>5</sup> Nasal splints have long been used to prevent post operative nasal adhesions in septal surgery.<sup>5</sup> Nasal splints are used to reduce adhesions but their efficacy in reducing it is still controversial.<sup>6,7,8</sup> All these studies have shown that no significant decrease in post-operative adhesions were seen but an increased morbidity in terms of pain and discomfort were reported.<sup>8</sup>*

*Rhinologists have not come to any conclusions about accepted standards regarding the materials used for nasal packing and how long and the definite indications of its usage.<sup>9</sup> Some rhinologists resist using packs as low incidence of heavy bleeding are seen following their surgeries with liberal use of cautery.<sup>2</sup> Some use splints and packs and remove after 24 hours, others keep it even for 5 days.<sup>9</sup>*

*Common packing materials used are bismuth iodoform paraffin paste , framycetin ribbon, paraffin gauze, telfa, merocel, silastic sheets, oxycel, surgical gelfoam which may be smeared with different antibiotics and used.<sup>2</sup> Pneumatic balloons are also used as packs, but nasal splints and through and through mucosal septal flaps suturing are basically used to straighten and stabilize the septum.<sup>2</sup>*

*Nasal packing itself is involved in mucosal injuries as it causes disturbance in endonasal lymph and venous drainage and may cause septal perforations and blocking of the sinus draining sites.<sup>2,10</sup> Nasal obstruction leading on to sleep disturbances and decreased arterial oxygen saturation during sleep are commonly seen.<sup>10,11</sup> Other complications like displacement and aspiration of packing materials , allergy, toxic shock syndrome, eustachian tube dysfunction and paraffin-induced granuloma are also reported.<sup>12,13</sup> All patients complain of discomfort with nasal packs and cause pain and bleeding when removed, so the basic purpose of packs are questioned.<sup>2</sup>*

*In our study we have compared the efficacy of two methods of packing one with framycetin ribbon packs with Teflon septal splints and the other with only framycetin ribbon packs.*

## Materials and methods:

*The study was carried out in the department of ENT, Head and Neck surgery during the period 84 months from July 2007 to July 2014. 214 patients who underwent septoplasties, endoscopic sinus surgeries, septorhinoplasties, turbinate surgeries and other nasal surgeries were included in the study. This is a comparative case series study with nasal packs was used in all 214 patients but teflon nasal splints were used in 98 cases. There were 129 males and 85 females in the study. The lowest age was 22 year male and the oldest 67 year male. (table 1)*

*The teflon splints were sutured to the nasal septum on either sides using 3-0 chromic catgut in 98 cases. (fig 1) The splints were smeared with framycetin and were previously sterilized. The nasal packing was done in all cases with framycetin packs which were removed after 48 hours, while the splints were kept in place for 5 days. The splints were removed on the 5<sup>th</sup> day and nasal irrigation was done to remove crusts.*

*Diagnostic nasal endoscopy was done after nasal irrigation and evidence of adhesions were noted. The stability and residual deviation of the septum if present were noted. The VAS scores were recorded at 8, 16, 24 and at pack removal. The VAS scores at 3<sup>rd</sup> and 5<sup>th</sup> postoperative day was also recorded. Also subjective assessment of the patient satisfaction about nasal airway and appearance after surgery was recorded.*

*The patients were followed up after one week, one month and 3 months after discharge. All the surgeries were done by the author assisted by postgraduate resident by the classical upper and lower tunnel techniques. Huge septal deviations were morcelized and reshaped with minimal excisions. No hemitransfixion incision and sutures were taken in any of the patients.*

*In the splinting group septum on either sides were splinted with teflon splints and sutured by 3-0 chromic catgut that crossed both septal flaps and splints and later packed by framycetin ribbon packs. (fig 2-4) If the patient was in the non-packing group, the septal flaps were closed by 3-0 chromic catgut at the incision site and no separate through and through horizontal mattress sutures were taken. Patients who did not attend follow up till 3 months were excluded from the study. There were 116 patients in the non splinting group and 98 patients in the splinting group for the final comparison. All the data were compiled and analysed.*

## **Result:**

*There were 129 males and 85 females in the study. The mean age in the non splinting group was 34.16 years and the mean age in the teflon splint group was 35.33 years. Septoplasty alone was done in 26 cases, together with other surgeries like functional sinus surgeries were done in 57 cases, with antro-choanal polypectomy in 11 cases, with ethmoidal polypectomy in 16 cases, with endoscopic surgeries for sinusitis in 66 cases, with turbinectomies in 23 cases and with DCR in 15 cases. Of the 214 patients studied, 97 patients had anterior septal deviation, 71 had posterior deviation and 46 had both anterior and posterior deviation. (table 2)*

*Adhesions were seen in 4 cases in non splint group and in 3 cases in splint group. Residual deviation were seen in 14 cases in non splint group and in 7 cases in splint group. No septal perforations were seen in any cases. 89% of the non splint group reported satisfaction with the outcome and 90% in the teflon splint group. Residual deviation remained the same after 3 months but the adhesions were broken at*

*follow up cleaning done weekly. No difference in VAS scores was seen in the two groups in 48 hours post-operatively but higher scores were seen in group with splint group for 5 days. (table 3)*

*In our study residual deviation and adhesion formation were minimal in splint and non splint group. The pain and discomfort was more during the first 48 hours after surgery and completely dropped after pack removal in the non splint group and remained in the splint group till 5 days when it was removed. (table 4)*

*The nasal Teflon splints in our study helped to decrease the residual deviation but no reduction in adhesion formation seen. (fig 5-6) Good nasal irrigation and cleaning the cavities with framycetin and dexamethasone ointments are more important to reduce adhesion formation which was seen in our study.*

## *Discussion:*

*Post operative adhesions corrected septum deviating laterally are common complications after septal surgeries even in the best of hands.<sup>14</sup> Contact between two postoperative traumatized raw surfaces are major contributing factors for adhesions and postoperative residual deviations.<sup>15</sup>*

*In our study Teflon septal splints were used to reduce adhesions and to maintain the stability of the septum. Apart from nasal packs and splints post operative nasal decongestants and saline irrigation was done to reduce adhesions. Septal splints are made of Teflon and come in 3 various sizes large medium and small. They are sterilized in formalin gas chambers and are used with framycetin as lubricant. Septal splints are*

*used primarily to provide gentle compression of the muco-perichondrial flaps over a large surface area, thus preventing septal hematoma.<sup>16</sup>*

*The splints should usually span the whole length of the septum to allow uniform compression over the whole length of the septum.<sup>16</sup> If the securing suture spans only a short distance, the splints are primarily spacers and do not provide much compression.<sup>16</sup> The splints are sieved which allow it to be sutured to the nasal septum one on either side.<sup>16</sup> As the splints were custom made and sieved, suturing was easily done by 3-0 chromic catgut with a cutting needle. All the suturing was made in the anterior sieves only making splint removal easier after framycetin packs.*

*Various non custom made splinting materials are reported in literature like silicon rubber splints, x-ray film splints, teflon and polythene splints.<sup>6</sup> Even splints were made from empty IV fluid bottles and plastic milk bottles, but none has given promising results as the custom made teflon splints.<sup>6</sup> All these non teflon splints increased the morbidity from the nasal surgery in terms of post operative pain and discomfort postoperatively.<sup>6</sup> So splints were never used on a routine basis in any study in literature and were advised only in septal surgeries with turbinate resections.<sup>6</sup> Wagner et al remarked about the remote possibility of toxic shock syndrome with the use of these splints.<sup>13</sup>*

*Ardehali et al in their study on 114 patients with nasal septal splints and without, found no significant difference in the two groups.<sup>2</sup> The parameters in the study were postoperative bleeding, hematoma, perforation and synechiae and no remarks on the stability and residual deviation was seen.<sup>2</sup> Four separate trans-septum through and through horizontal mattress sutures were used and similar results were seen as with the splint and pack cases.<sup>2</sup> Also the packing cases had marginally higher infection rates compared to those without packs.<sup>2</sup> Significant*

*difference in pain recorded on VAS was noted in the study with the packing group showing more pain with pack insitu and at removal. Also the splints caused pain even after pack removal and at removal.<sup>2</sup>*

*Lemmens and Lemkens also found lower incidences of septal perforations in their study on post septoplasty patients with nasal packs and septal splints.<sup>17</sup> Schoenberg et al, in their study with different methods of nasal packing with Telfa packing, bismuth iodoform paraffin paste packing found no significant difference in complications like adhesions, septal perforations and purulent infections, but vestibulitis was seen in many cases with silastic septal splint.<sup>18</sup> They advocated packing to be reserved for cases where there is concern about persistent haemorrhage.<sup>18</sup>*

*Kaygusuz et al, reported significantly higher rates of infection in postoperative cases with packs and no significant difference in adhesion formation in patients with packs.<sup>19</sup> Manzini et al found no significant difference in incidence of mucosal adhesions and the severity of persistent residual deviation in patients with and without nasal packs.<sup>20</sup> But Guyuron et al in their study found lesser residual deviation in patients with nasal packs after surgery.<sup>21</sup> Nunez et al, found significant higher pain score averages on VAS scale in patients with postoperative nasal packs compared to those without packs.<sup>22</sup> Jensen et al, reported nocturnal hypoxia in all the patients with post operative packing particularly on the first and the second nights after the operation. This disappeared after pack removal and was not seen in the patients without packs.<sup>23</sup>*

*Malki et al, in their study on 110 patients found no difference in adhesion rates in patients with nasal splints and those without after septoplasty.<sup>24</sup> Pain and discomfort were more in the patients with splints and so is indicated only for enhancing the stability of the septum following septoplasty.<sup>24</sup> Pringle et al in their questionnaire based study*



*found the common use of splints were to prevent adhesions.<sup>25</sup> Flat, pre-shaped silicone rubber splints were by far the most frequently used type.<sup>25</sup> No significant decrease in adhesions were seen with splints and the study also reported that use of nasal toilet is an effective alternative to using nasal splints in the prevention of intranasal adhesions.<sup>25</sup>*

*Cook et al, in their study 100 cases of septoplasty found intranasal silicon rubber splints added no advantage to reduce adhesion formation. Splints were useful in stabilizing the position of the septum, patency of the airways but more pain and discomfort were seen with the splints.<sup>26</sup>*

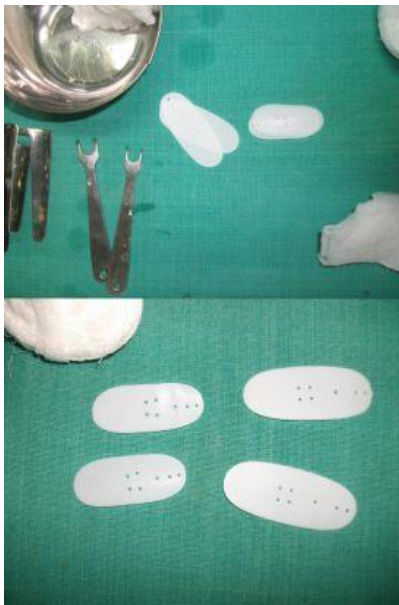
*Statistics in our study are nearly comparable to that in the above studies. So teflon septal splints are not indicated in all cases of septoplasties to reduce adhesions. Nasal irrigations with normal saline and cleaning the cavities with framycetin dexamethasone pastes are better than teflon splints to reduce adhesions. The splints are useful in maintaining stability of the nasal septum and reducing the residual deviations after surgery. Pain and discomfort are more with these splints.*

## **Conclusion:**

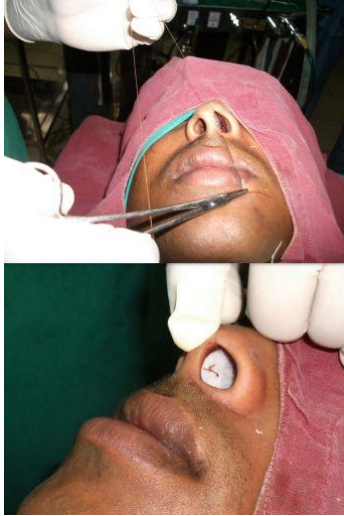*Nasal septal splints used in our study does not significantly reduces the adhesions after septoplasty but are effective in reducing the residual deviations. The pain and discomfort are more with the splints. Post operative adhesion are better reduced by nasal irrigation and manual cleaning of the cavities by antibiotic ointments.*

<b>N=214</b>	<b>Only framycetin packs, no splints (116)</b>	<b>Teflon splints used (98)</b>
<b>Males (129)</b>	<b>72</b>	<b>57</b>
<b>Females (85)</b>	<b>44</b>	<b>41</b>
<b>Average age</b>	<b>34.16 yrs</b>	<b>35.33 yrs</b>
<b>anterior septal deviation (97)</b>	<b>54</b>	<b>43</b>
<b>posterior septal deviation (71)</b>	<b>38</b>	<b>33</b>
<b>both anterior and posterior deviation (46)</b>	<b>24</b>	<b>22</b>

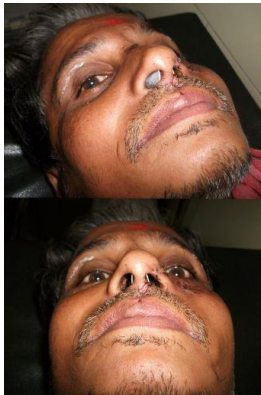**Table 1: Proportion of patients with nasal pain and discomfort.**



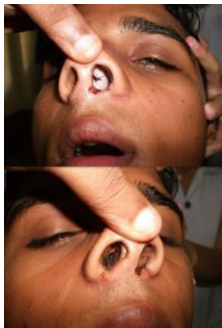**Fig 1 Sterilized Teflon splints ready for use**



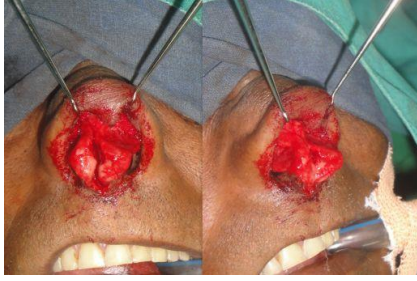***Fig 2 Teflon splints being sutured to the septum***



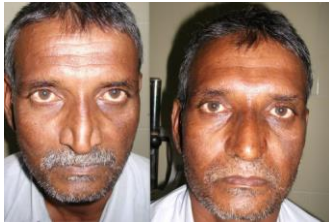***Fig 3 Teflon splints in place for septal repair after repairing naso-maxillary trauma***



***Fig 4 Teflon splints used for revision septoplasty***



***Fig 5 Lax lower alar cartilage splinted***



***Fig 6 Post operative results of rhinoplasty with Teflon nasal splinting***

## References:

1. Arvind Kumar A, Omar B, Ajay N. Double-blind randomised controlled trial comparing Merocel with Rapid Rhino nasal packs after routine nasal surgery. *Rhinology* 2003; 41: 241–243.
2. M.M. Ardehali, S. Bastaninejad: Use of nasal packs and intranasal septal splints following Septoplasty: *Int J Oral Maxillofac Surg* (2009).
3. Erkhan G, Ergin NT. Comparison of suture and nasal packing in rabbit noses. *Laryngoscope* 2004; 144: 639–645.
4. Feder, R: Partial turbinectomy. *Laryngoscope*, 94:259-260.1984
5. White, A., Murray, J.A. (1988) Intranasal adhesion formation following surgery for chronic nasal obstruction. *Clinical Otolaryngology* 13: 139- 143.
6. Campbell, J, B., Watson, M. G., Shenoj,P. M.(1987) The role of intra-nasal in the prevention of post- operative nasal adhesions. *Journal of Laryngology and Otology* 101; 1140-1143.
7. Salinger, S. and Cohen , D. M. (1955) Surgery of the difficult septum. *Archives of Otolaryngology*, 61:419-421.
8. Gilchrist, A. G. (1974) Surgery of the nasal septum and pyramid. *Journal of Laryngology and Otology*, 88: 759-771.
9. Lubianca JF, Sant'anna GD, Mauri M, Jaime Lui's Freitas Arrarte. Carlos Alberto Brinckmann. Evaluation of time of nasal packing after nasal surgery:

- a randomized trial. Otolaryngology - Head & Neck Surgery 2000: 122: 899–901.*
10. Huang IT, Podkomorska D, Murphy MN, Hoffer I. Toxic shock syndrome following septoplasty and partial turbinectomy. *J otolaryngol* 1986; 15: 310–312.
  11. Yigit O, Cinar U, Uslu B, Akgu“ I G, Topuz E, Dadas, B. The effect of nasal packing with or without an airway on arterial blood gases. *Kulak Burun Bogaz Ihtis Derg* 2002; 9: 347–350.
  12. Thompson AC, Crowther JA. Effect of nasal packing on eustachian tube function. *J Laryngol Otol* 1991; 105: 539–540.
  13. Wagner R, Toback JM. Toxic shock syndrome following septoplasty using plastic septal splint. *Laryngoscope* 1989; 96: 609–610.
  14. Pringle, Muhammad, B, (1992) The use of intranasal splints: A consultant survey. *Clinical otolaryngology* 17; 535-539.
  15. Shone GR, Clegg, RT.(1987) Nasal adhesions. *Journal of Laryngology and Otolology* 101: 555-557.
  16. George L. Murrell: Dorsal augmentation with septal cartilage: Seminars in plastic surgery/volume 22, number 2 2008.
  17. Lemmens W, Lemkens P. Septal suturing following nasal septoplasty-A valid alternative for nasal packing? *Acta otorhinolaryngol* 2001; 55: 215–221.
  18. Schoenberg MV, Robinson P, Ryan R. Nasal packing after routine nasal surgery – is it justified? *J Laryngol otol* 1993; 107: 902–905.
  19. Kaygusuz I, Kizirgil A, Karlidag T. Bacteriemia in septoplasty and septorhinoplasty. *Rhinology* 2003; 41: 76–79.
  20. Manzini M, Cuda D, Caroggio A. Nasal packing and antibiotic prophylaxis in septoplasty: a controlled study. *Acta otolaryngol Ital* 1998; 18: 88–95.
  21. Guyuron B. Is packing after septorhinoplasty necessary? A randomized study. *Plast reconstr surg* 1989; 84: 41–44.
  22. Nunez DA, Martin FW. An evaluation of post-operative packing in nasal septal surgery. *Clin otolaryngology* 1991; 16: 549–550.
  23. Jensen PF, Kristensen S, Johannesen NW. Episodic nocturnal hypoxia and nasal packs. *Clin otolaryngol* 1991; 16: 433–435.
  24. Malki D, Quine SM, Pfleiderer AG: Nasal splints, revisited; *J Laryngol Otol.* 1999 Aug;113(8):725-7.
  25. Pringle MB: The use of intra-nasal splints: a consultant survey: *Clin Otolaryngol Allied Sci.* 1992 Dec;17(6):535-9.

26. Cook JA, Murrant NJ, Evans KL, Lavelle RJ: Intranasal splints and their effects on intranasal adhesions and septal stability: *Clin Otolaryngol Allied Sci.* 1992 Feb;17(1):24-7.