

Serum contents of *matrix metalloproteinase-2* and *9* are correlated with the prognosis of papillary thyroid carcinoma after ultrasound-guided radiofrequency ablation.

Jun He, Gang Liu, Kezhong Shao, Xuezhou Shen, Limin Chen *

Department of Ultrasound Diagnosis, Wenzhou Central Hospital, Wenzhou, P.R. China

Abstract

The present study is to measure serum contents of *matrix metalloproteinase (MMP)-2* and *MMP-9* in Papillary Thyroid Carcinoma (PTC) patients before and after Radiofrequency Ablation (RFA), and to evaluate the correlation of *MMP-2* and *MMP-9* contents with prognosis. A total of 41 PTC patients who received ultrasound-guided percutaneous RFA between May 2015 and Oct 2016 were included. The number of foci were 96. Before surgery, the number, size, property, echo, boundary, shape, calcification, peripheral sound halo and blood flow distribution of thyroid nodules were examined using ultrasound. Enzyme-linked immunosorbent assay was used to measure the serum contents of *MMP-2* and *MMP-9* before and after RFA. Logistic regression analysis was performed to identify independent risk factors for the prognosis of PTC and to investigate the correlation of *MMP-2* and *MMP-9* contents with prognosis. The medians of *MMP-2* and *MMP-9* contents were used as the thresholds that discriminated low and high levels of *MMP-2* and *MMP-9*, respectively. The effect of low or high levels of *MMP-2* and *MMP-9* on prognosis was evaluated by Kaplan-Meier analysis. Ultrasound showed that RFA effectively reduced tumor foci and the surrounding blood supply. ELISA showed that serum contents of *MMP-2* and *MMP-9* in PTC patients were significantly reduced after RFA. Logistic regression analysis demonstrated that age, calcification degree, regularity of shapes, and diameter and number of foci in PTC patients were effective independent risk factors for the prognosis after RFA. In addition, serum contents of *MMP-2* and *MMP-9* were correlated with independent risk factors for the prognosis of PTC patients after RFA. Of note, PTC patients with high *MMP-2* or *MMP-9* contents had poorer prognosis than those with low *MMP-2* or *MMP-9* contents. The present study demonstrates that serum contents of *MMP-2* and *MMP-9* have clinical significance for the evaluation of PTC prognosis after RFA.

Keywords: Papillary thyroid carcinoma (PTC), Radiofrequency ablation (RFA), Ultrasound, Risk factor.

Accepted on June 30, 2017

Introduction

Papillary Thyroid Carcinoma (PTC) is a common malignant tumor of thyroid gland that accounts for about 1% of systemic malignant tumors [1]. It is characterized by high clinical incidence rate and low mortality. The diagnostic rate of thyroid minute tumors by palpation is about 4% in general population, while the diagnostic rate by ultrasound is 20%-50% [2]. The application of Contrast-Enhanced Ultrasound (CEUS) in the diagnosis of thyroid tumors is a hot spot in ultrasound medical research, and the detection ability of tissue micro-perfusion is significantly improved [3]. In the treatment of PTC, surgical resection is a conventional treatment, but the recurrence rate of residual parts after operation is high [4]. Furthermore, thyroid function is decreased, and the quality of life is seriously declined. With increasing detection rate of thyroid tumors and the development of minimally invasive surgery in recent years, Radiofrequency Ablation (RFA) has been gradually applied in clinical treatments. As a treatment that induces tissue necrosis

by local hyperthermia, RFA has a higher rate of heat production than RF and has become a new approach for local tumor therapy [5]. At present, clinical diagnosis of PTC mostly depends on clinical manifestations and pathological examination. However, the specificity and accuracy of pathological examination are usually low due to its invasiveness. Therefore, it is necessary to find suitable tumor markers and predictors in the diagnosis and preoperative evaluation of PTC. *Matrix metalloproteinase (MMP)-2* and *MMP-9* are collagenases that degrade type IV collagen in basement membrane, and have significance for tumor angiogenesis and invasion and metastasis of tumor cells [6]. At present, most studies are focused on the expression of *MMP-2* and *MMP-9* in thyroid cancer tissue, but few studies involve the determination of serum contents of *MMP-2* and *MMP-9*. In the present study, we measure changes in serum contents of *MMP-2* and *MMP-9* before and after RFA treatment, and investigate the effects of relevant factors on the prognosis of PTC.

Materials and Methods

Patients

A total of 41 patients with PTC who received ultrasound-guided percutaneous RFA at our hospital between May 2015 and Oct 2016 were included in the present study (30 females and 11 males; age range, 20-65 y; mean age, 41.5 ± 16.8 y). The number of foci was 96.

Inclusion criteria: (1) Preoperative diagnosis of PTC by fine needle aspiration cytology examination; (2) No history of neck surgery; (3) Willingness of minimally invasive treatment because of ugliness of nodules, neck compression discomfort and anxiety.

Exclusion criteria: (1) Benign foci diagnosed by fine needle aspiration cytology examination; (2) History of neck surgery; (3) Severe coagulation disorders. Fasting peripheral venous blood was collected from all patients in the morning 3 d before surgery and one week, three months, six months and one year after surgery for the determination of serum *MMP-2* and *MMP-9* contents.

In the meantime, peripheral venous blood was also collected from 56 subjects with benign thyroid nodules (39 females and 17 males; mean age, 45.8 ± 15.3) as control. All procedures were approved by the Ethics Committee of Wenzhou Central Hospital. Written informed consents were obtained from all patients or their families.

Surgery

Before surgery, the number, size, property, echo, boundary, shape, calcification, peripheral sound halo and blood flow distribution of thyroid nodules were examined. Type I thyroid nodules had abundant internal blood flow signals, type II thyroid nodules had abundant blood flow signals around the nodules, type III thyroid nodules had abundant blood flow signals both inside and around the nodules and type IV thyroid nodules had no blood flow signals either inside or around the nodules [7].

After routine skin disinfection, 2% lidocaine solution was used for local anesthesia. The patients received bolus injection of 2 ml Sonovue solution *via* ulnar vein. CEUS was performed to evaluate blood supply characteristics. According to the positions of thyroid nodules, saline and lidocaine mixture was used to separate the spaces between thyroid and carotid artery, between thyroid and trachea, between thyroid and esophagus, and behind thyroid, in order to protect these organs from being injured by heat.

Before RFA, the tip of RF needle was accurately punctured into the nodules under the guidance by ultrasound with a probe frequency of 10 MHz (MyLab90; Esaote, Genoa, Italy). Then, multi-point and multi-surface ablation started at thyroid nodules (RF output power, 5 W) until thyroid tissue layer with nodules was completely covered by strong echo of heat generation. The system (Olympus Celon System, Olympus and

Tokyo, Japan) automatically controlled ablation duration through stereo impedance feedback.

After RFA, the patients received another bolus injection of 2 ml Sonovue solution *via* ulnar vein before CEUS monitoring. Contrast agent filling and defect ranges in ablation zone were displayed. After confirming no existence of residual enhancement in ablation zone, ablation was terminated. After surgery, the skin was cooled by ice for 24 h to avoid skin burns.

Enzyme-linked immunosorbent assay (ELISA)

Peripheral blood (6 ml) was collected and kept still for 30 min at room temperature before centrifugation at 2,000 rpm for 15 min. Serum (3 ml) was aspirated for the determination of *MMP-2* and *MMP-9* contents using ELISA kits according to the manufacturer's manual (Boster, Wuhan, China). The medians of *MMP-2* and *MMP-9* contents were used as the thresholds that discriminated low and high levels of *MMP-2* and *MMP-9*, respectively. The effect of low or high levels of *MMP-2* and *MMP-9* on prognosis was then evaluated.

Follow-ups

Immediately after surgery, ablation ranges were evaluated by CEUS. If residual nodule tissues existed, ablation was performed again in time. One week and 1, 3, 6 and 12 months after surgery, the sizes and volumes of nodules were measured by ultrasound. Volume reduction ratio was calculated by $(\text{volume before surgery} - \text{volume at follow-up}) / \text{volume before surgery} \times 100\%$. In the meantime, echo and blood flow changes in ablation area were examined. Efficacy was evaluated according to the standards for RFA treatment of tumors [8].

With complete disappearance of blood flow under ultrasound, the nodules were considered to be cured if they completely disappeared. However, RFA treatment was considered effective if the volumes of nodules were reduced by more than 50%. In addition, RFA treatment was considered favourable if the volumes of nodules were reduced by 25-50%.

Multiple factor analysis

The blood flow, volume and follow-up of the foci were evaluated by color Doppler ultrasound. The prognostic factors of PTC were analyzed, including age, calcification, morphology, diameter and number.

Statistical analysis

Statistical analysis was performed using SPSS19.0 software (IBM, Armonk, NY, USA). Intergroup comparison was performed using t-test. The data were expressed as means \pm standard deviations.

Correlation factors were analyzed by logistic regression analysis. Kaplan-Meier analysis was used to analyze the tumor-free survival curve of serum levels of *MMP-2* and

Serum contents of matrix metalloproteinase-2 and 9 are correlated with the prognosis of papillary thyroid carcinoma after ultrasound-guided radiofrequency ablation

MMP-9 against prognosis. Differences with $P < 0.05$ were considered statistically significant.

Results

RFA effectively reduces tumor foci and the surrounding blood supply

To examine the number, size, property, echo, boundary, shape, calcification, peripheral sound halo and blood flow distribution of thyroid nodules, ultrasound was used. Before RFA, CEUS showed that all 96 foci had enhancement, and blood circulation

signals were observed around the foci (mostly type II). One month after RFA, no enhancement was observed inside or around 64 foci and these foci in 30 patients (73.1%) completely disappeared.

In addition, 27 foci from 8 patients (19.5%) were only partially alleviated, and 5 foci from 3 patients (7.3%) were still stable. Within three months after RFA, none of the patients had any foci that were increased over 25% in size (Table 1). These results suggest that RFA effectively reduces tumor foci and the surrounding blood supply.

Table 1. Ultrasonographic characteristics of patients with papillary thyroid carcinoma.

	Patients		Control	
	No. of cases	Percentage (%)	No. of cases	Percentage (%)
Number of foci				
Single	10	24.3	10	17.8
Two	8	19.5*	18	32.1
Multiple	23	56	28	50
Size of foci				
≤ 2 cm	27	65.8*	11	19.6
>2 cm	14	34.1	45	80.3
Calcification				
Micro calcification	19	46.3	25	44.6
Macro calcification	7	17.0*	18	32.1
Echo pattern				
Low echo	24	58.5*	11	19.6
Middle and high echo	4	9	6	10.7
Mixed echo	13	31.7*	39	69.6
Blood flow distribution				
Type I	6	14.6	8	14.2
Type II	21	51.2	10	17.8
Type III	5	12.1	31	55.3
Type IV	9	21.9*	7	12.5

Note: * $P < 0.05$ compared with control.

Serum contents of MMP-2 and MMP-9 in PTC patients are significantly reduced after RFA

To determine the serum contents of *MMP-2* and *MMP-9*, ELISA was performed. The data showed that *MMP-2* and *MMP-9* contents of PTC patients before RFA were both significantly higher than those of control group ($P < 0.05$). In addition, *MMP-9* content of PTC patients at one week after

RFA was significantly lower than that before RFA ($P < 0.05$), but *MMP-2* content of PTC patients at one week after RFA was not significantly different from that before RFA ($P > 0.05$). Of note, both *MMP-2* and *MMP-9* contents of PTC patients at one month, three months, six months and one year after RFA were significantly lower than those before RFA, respectively ($P < 0.05$ for all) (Table 2). The results indicate that serum

contents of *MMP-2* and *MMP-9* in PTC patients are significantly reduced after RFA.

Table 2. Serum contents of *MMP-2* and *MMP-9* before and after radiofrequency ablation (means \pm standard deviations).

Groups		<i>MMP-2</i> content (ng/ml)	P	<i>MMP-9</i> content (ng/ml)	P
Control		547.32 \pm 98.36		126.62 \pm 19.26	
Patients	One day before surgery	794.54 \pm 152.59	0.04	299.98 \pm 70.48	0.00
	One week after surgery	738.48 \pm 114.48	0.35	278.73 \pm 68.51	0.00
	One month after surgery	481.21 \pm 102.87	0.03	223.25 \pm 68.00	0.00
	Three months after surgery	404.36 \pm 88.53	0.00	201.65 \pm 65.31	0.00
	Six months after surgery	281.85 \pm 67.65	0.00	184.64 \pm 64.82	0.00
	One year after surgery	171.60 \pm 72.75	0.00	169.07 \pm 64.16	0.00

Age, calcification degree, regularity of shapes, and diameter and number of foci in PTC patients are effective independent risk factors for the prognosis after RFA

To study risk factors for the prognosis of patients with PTC, logistic regression analysis was carried out. The data showed that age, calcification degree, regularity of shapes and diameter and number of foci were significantly correlated with the prognosis of patients with PTC ($P < 0.05$), and were independent risk factors (Exp (B) (OR) > 1) (Table 3). The result suggests that age, calcification degree, regularity of shapes, and diameter and number of foci in PTC patients are effective independent risk factors for the prognosis after RFA.

Table 3. Logistic regression analysis of risk factors for the prognosis of patients with PTC.

Variables	B	Exp (B)	95% Exp (B)		P
			Lower limit	Upper limit	
Age	0.174	1.19	1.006	1.408	0.042

Table 4. Correlation of serum contents of *MMP-2* and *MMP-9* with independent risk factors for the prognosis of PTC patients after RFA.

Factors		<i>MMP-2</i> content	P	<i>MMP-9</i> content	P
Age	≤ 40	625.36 \pm 97.14	0.00	348.54 \pm 77.46	0.05
	> 40	726.28 \pm 105.68		416.52 \pm 84.18	
Calcification degree	Micro calcification	724.29 \pm 119.83	0.01	415.76 \pm 66.28	0
	Macro calcification	515.54 \pm 86.87		326.9 \pm 34.42	
Regularity of shapes	Regular	486.74 \pm 103.28	0.10	111.2 \pm 49.86	0.18
	Irregular	620.74 \pm 132.16		314.0 \pm 77.28	
Diameter of foci	≤ 2 cm	558.63 \pm 112.56	0.00	198.46 \pm 58.85	0.00
	> 2 cm	742.51 \pm 132.67		304.72 \pm 84.18	
Number of foci	Single	476.23 \pm 84.28		176.94 \pm 48.29	

Micro calcification	-4.874	1.008	0.000	0.494	0.022
Irregular shape	-2.694	2.068	0.005	0.99	0.049
Diameter of foci	2.001	7.393	1.623	33.676	0.01
Number of foci	1.289	3.629	0.182	72.516	0.033

Serum contents of *MMP-2* and *MMP-9* are correlated with independent risk factors for the prognosis of PTC patients after RFA

To examine the correlation of *MMP-2* and *MMP-9* contents in serum with the above independent risk factors, logistic regression analysis was employed. The data showed that serum contents of *MMP-2* and *MMP-9* were significantly different in the presence of different age, micro calcification, irregular shape, diameter of foci or number of foci ($P < 0.05$) (Table 4).

The result indicates that serum contents of *MMP-2* and *MMP-9* are correlated with independent risk factors for the prognosis of PTC patients after RFA.

Two	512.65 ± 97.38	0.00	238.74 ± 66.92	0.01
Multiple	754.13 ± 116.37		379.38 ± 101.3	

PTC patients with high MMP-2 or MMP-9 contents have poorer prognosis than those with low MMP-2 or MMP-9 contents

To investigate how preoperative serum contents of MMP-2 and MMP-9 affect survival time, Kaplan-Meier analysis was performed. The median values of MMP-2 and MMP-9 contents (814.27 ng/ml and 326.73 ng/ml, respectively) were used to distinguish low and high levels of MMP-2 and MMP-9. The data showed that MMP-2 contents from 27 patients were higher than median value, and those from 14 patients were lower than median value. In addition, MMP-9 contents from 30 patients were higher than median value, and those from 11 patients were lower than median value. Tumor-free survival curves of Kaplan-Meier analysis showed that patients with high MMP-2 or MMP-9 contents had shorter tumor-free survival time than those with low MMP-2 or MMP-9 contents (P<0.05) (Figure 1). The result suggests that PTC patients with high MMP-2 or MMP-9 contents have poorer prognosis than those with low MMP-2 or MMP-9 contents.

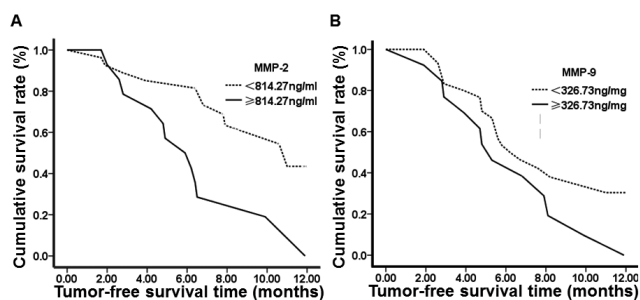


Figure 1. Tumor-free survival curves of patients with high or low preoperative contents of MMP-2 or MMP-9. The medians of MMP-2 and MMP-9 contents (814.27 ng/ml and 326.73 ng/ml, respectively) were used as the thresholds that discriminated low and high levels of MMP-2 and MMP-9, respectively. The effect of low or high levels of MMP-2 and MMP-9 on prognosis was evaluated by Kaplan-Meier analysis.

Discussion

With the popularization of high-resolution ultrasonography, the detection rate of thyroid nodules is as high as 19%-68% and 5%-15% of the nodules are malignant [9]. Although open surgery can treat almost all thyroid tumors, minimally invasive techniques have become the focus and trend of thyroid surgery. At present, minimally invasive treatments for PTC include RFA, laser treatment, high-intensity focused ultrasound therapy and microwave therapy. Of all, RFA has advantages like shorter treatment time, fewer complications, and lower cost.

MMPs are associated with inflammation, atherosclerosis, cirrhosis, connective tissue diseases and tumors. The degradation of extracellular matrix and basement membrane is required in the local invasion and metastasis of malignant

tumors. It is reported that MMP-2 and MMP-9 degrade basement membrane, and promote tumor invasion and metastasis [10]. Therefore, expression of MMP-2 and MMP-9 is a marker for malignant progression of tumors. A study shows that MMP-2 and MMP-9 levels in patients with PTC are significantly higher than those in subjects with benign thyroid nodules or healthy subjects [11]. ELISA results of the present study show that serum levels of MMP-2 and MMP-9 in PTC patients are higher than those in control group, and RFA reduces MMP-2 and MMP-9 contents in serum, suggesting that MMP-2 and MMP-9 participate in the invasion and metastasis of PTC.

RFA reduces the sizes of thyroid nodules and alleviates clinical problems associated with thyroid tumors [12]. The present study shows that RFA has eliminated 73.1% of all foci, and alleviated 19.5% of all foci. Therefore, it is suggested that RFA is an effective and safe method for the treatment of PTC. However, a longer follow-up is needed to verify the effect of RFA in thyroid therapy. Logistic regression analysis in the present study shows that age ≤ 40 y, micro calcification, irregular shape, foci diameter ≤ 2 cm and foci number ≥ 2 are independent risk factors for PTC, being consistent with the results by Yu et al. [13].

Micro calcification is caused by calcium deposition induced by necrosis of the tip of nipple or the secretion of calcium salt deposition-promoting materials by tumor itself. However, irregular shape, foci diameter ≤ 2 cm and foci number ≥ 2 are not consistent with the results by Smith et al. probably due to different locations, tissue pathological types, or ultrasonic physicians [14]. The present study also demonstrates that changes in serum contents of MMP-2 and MMP-9 in the presence of different independent risk factors are correlated with prognosis, and elevated serum contents of MMP-2 and MMP-9 suggest poor prognosis. Therefore, evaluation of serum MMP-2 and MMP-9 contents before RFA can increase the clinical value of these biomarkers.

Follow-ups show that elevated MMP-2 and MMP-9 contents after RFA may suggest progression (recurrence or metastasis) of the disease, and prognosis can be affected. Kaplan-Meier analysis in the present study shows that PTC patients with high MMP-2 and MMP-9 contents have poor therapeutic effect after RFA, suggesting that preoperative MMP-2 and MMP-9 contents have prediction value for the prognosis of PTC after RFA.

In conclusion, RFA has relatively good long-term effect in the treatment of PTC, and significantly increases the survival time of patients. As important biomarkers, serum contents of MMP-2 and MMP-9 in PTC patients may be useful in the evaluation of the prognosis after RFA.

Acknowledgement

This work was supported by Wenzhou Central Hospital. We would also like to thank Dr. Zhongliang Pan from the Department of General Surgery, Wenzhou Central Hospital, China.

Disclosures

All authors declare no financial and non-financial competing interests.

References

1. Wang Y, Wang G, Lu W. Main causes and management of reoperation for patients with thyroid cancer. *J Clin Res* 2003; 20: 848-850.
2. Levine RA. Current guidelines for the management of thyroid nodules. *Endocr Pract* 2012; 18: 596-599.
3. Anil G, Hegde A and Chong FH. Thyroid nodules: risk stratification for malignancy with ultrasound and guided biopsy. *Cancer Imaging* 2011; 11: 209-223.
4. Dong W, Zhang H. Re-operation for papillary thyroid carcinoma after radiofrequency ablation therapy: A clinical analysis of 5 cases. *Chin J Prac Surg* 2015; 35: 653-655.
5. Liu X, Huang J, Sun D. Experience of radiofrequency ablation treatment of thyroid papillary microcarcinoma under ultrasound guidance. 2015; 39: 69-70.
6. Tumer HE, Nagy Z, Esiri MM. Role of matrix metalloproteinase 9 in pituitary tumor behavior. *J Clin Endocrinol Metab* 2000; 85: 2931-2935.
7. Guo Y, Pan R, Song W. Ability of color doppler ultrasound in diagnosis of thyroid carcinoma. *Chin J Gen Pract* 2013; 11: 1454-1455.
8. Faggiano A, Ramundo V. Thyroid nodules treated with percutaneous radiofrequency thermal ablation: a comparative study. *J Clin Endocrinol Metab* 2012; 97: 4439-4445.
9. Guth S, Theune U, Aberle J. Very high prevalence of thyroid nodules detected by high frequency (13 MHz) ultrasound examination. *Eur J Clin Invest* 2009; 39: 699-706.
10. Chang JW, Kang SU, Shin YS. Non-thermal atmospheric pressure plasma inhibits thyroid papillary cancer cell invasion via cytoskeletal modulation, altered MMP-2/-9/uPA activity. *PLoS One* 2014; 9: 92198.
11. Zhou S, Li Y. Correlation between matrix metalloproteinase-2 as well as metalloproteinase-9 in serum and papillary thyroid gland carcinomas. *Hebei Med J* 2008; 30: 6-9.
12. Baek JH, Moon WJ. Radiofrequency ablation for the treatment of autonomously functioning thyroid nodules. *World J Surg* 2009; 33: 1971-1977.
13. Yu L, Shang J. Clinical analysis of 462 cases of thyroid nodules. *J Chin Pract Diag Ther* 2011; 25: 1124-1125.
14. Smith-BR, Lebda P. Risk of thyroid cancer based on thyroid ultrasound imaging characteristics: results of a population-based study. *JAMA Intern Med* 2013; 173: 1788-1796.

*Correspondence to

Limin Chen

Department of Ultrasound Diagnosis

Wenzhou Central Hospital

Wenzhou

P.R. China