

**ISSN: 2250-0359****Volume 3 Issue 3 2013**

Schwannoma of the cervical vagus nerve: A rare benign neurogenic tumor

Gokce Simsek, M.D.¹, Mehmet Sahan, M.D.², Behcet Gunsoy, M.D.³, Ataturker Arikok, M.D.⁴, Istemihan Akin, M.D.²

1- Ministry of Health Yesilyurt State Hospital , Malatya, Turkey

2- Ministry of Health, Diskapi Y.B. Training and Research Hospital, ENT Clinic, Ankara, Turkey

3- Gaziantep State Hospital, Gaziantep, Turkey

4- Ministry of Health, Diskapi Y.B. Training and Research Hospital, Pathology Clinic, Ankara, Turkey

Abstract

A schwannoma, also known as an acoustic neuroma, is a benign nerve sheath tumor composed of schwann cells, which normally produce the insulating myelin sheath covering the peripheral nerves. Schwannoma, originating from the cervical vagus nerve, is an extremely rare neoplasm that usually occurs in men between the 3rd and 6th decades of life. The most common presentation is a painless, slow-growing, lateral neck mass; this appears in a large proportion of cases. Complete surgical resection with care to protect the nerve of origin is the recommended treatment of choice. Here, we

report a case of cervical vagal schwannoma in a 55-year-old male who admitted with the complaint of a firm and painless mass lesion on the right side of the neck. The management of the case is discussed along with the relevant literature.

Keywords: Neurilemmoma; Neoplasms; Vagus nerve; Treatment

Introduction

Schwannomas, also known as neurilemmomas, neuromas, neurinomas, or paragangliomas, are uncommon nerve sheath neoplasms that may arise from any peripheral, cranial, or autonomic nerve of the body with the exception of the olfactory and optic nerves (1). Nerve sheath tumors arising from the cervical vagus nerve are extremely rare. These tumors are among the benign tumors of the neck, and are reported to occur in patients between 30 and 60 years of age; the male-to-female ratio is 1:1 (2). Most cases present with an asymptomatic neck mass. Preoperative diagnosis is generally difficult, since most cervical vagal schwannomas (CVS) do not present with neurological deficits. Paragangliomas, branchial cleft cysts, malign neck tumors, and cervical lymphadenopathies should be kept in mind in differential diagnosis (1,2). Surgical resection of the tumor is the treatment of choice in the management of these cases. Here, we report a case of CVS in a 55-year-old male patient that presented with an asymptomatic slow-growing neck mass and resistant cough that had been evident for 3 months.

Case Report

A 55-year-old male patient was admitted to our outpatient clinic with the complaints of a painless mass on the right side of the neck and a cough, which had continued for 3 months and was resistant to medical therapy. His medical history was unremarkable except for a lumbar hernia operation 10 years prior. On clinical examination, a mass was found in the right level 2 cervical region; this was 7x3 cm in diameter, smooth surfaced, mobile in the horizontal plane, firm, and painless. Upon palpating the mass, a paroxysmal cough was noticed. There was no pulsation on palpation, and no murmur was heard on auscultation of the mass. Medial displacement of peritonsillary structures was not observed in the oropharyngeal examination. All the cranial nerve examinations were normal except for right recurrent nerve paralysis, which was noted during indirect laryngoscopy. Color Doppler ultrasound of the neck revealed a 6x3x3cm, well-circumscribed, heterogeneous mass with limited vascularization of

the outer part. The carotid artery was significantly displaced due to the compression of the mass lesion.

Magnetic resonance imaging (MRI) of the neck confirmed a 7x3x3.5cm properly limited mass with high signal intensity on T1-weighted MRI and a heterogeneous, higher signal intensity on T2-weighted MRI (Figure 1). After intravenous administration of gadolinium-based contrast material, the lesion showed irregular peripheral enhancement. Carotid artery angiography was performed because of the close relationship between the mass and the carotid artery. The angiography showed a normal filling in the right common, internal, and external carotid arteries and their branches. No abnormal mass lesion was observed on angiographic investigation. Fine needle aspiration (FNA) revealed a result of nondiagnostic cytology. After the initial evaluation, the patient was prepared for surgical evaluation and resection with a presumptive diagnosis of glomus tumors, neurogenic tumors, angiofibroma, sarcoma, and lymphoma.

Under general anesthesia, an oblique cervical incision was made starting from the right mastoid apex and extending to the mentum along the inferior border of the mandibula. A yellowish mass lesion was observed that was 7x4cm in diameter, originating from the vagus nerve and medially adjacent to the common carotid artery. It was extending laterally to the internal jugular vein and sternocleidomastoid (SCM) muscle, and superiorly to the skull base (Figure 2). The mass was carefully dissected from the vagus nerve and other adjacent structures, with care taken to protect the vagal nerve's integrity. The specimen was sent for frozen section and a schwannoma originating from the vagus nerve was confirmed. No extra surgical intervention was considered and the operation was completed. Postoperative follow up of the patient was uneventful and he was discharged on the 7th postoperative day.

On histopathological examination, the tumor was found to be composed of focal hypercellular (Anthony A) areas and hypocellular areas (Anthony B) with a fibrillary appearance (Figure 3). Immunohistochemical examination of tumor cells showed strong S-100 and neuron specific enolase (NSE) positivity. Therefore, a final diagnosis of vagal nerve schwannoma was obtained.

Figure1: Sagittal view of the tumor on MRI. The arrow indicates a 7x4 cm mass lesion originating from the vagus nerve.

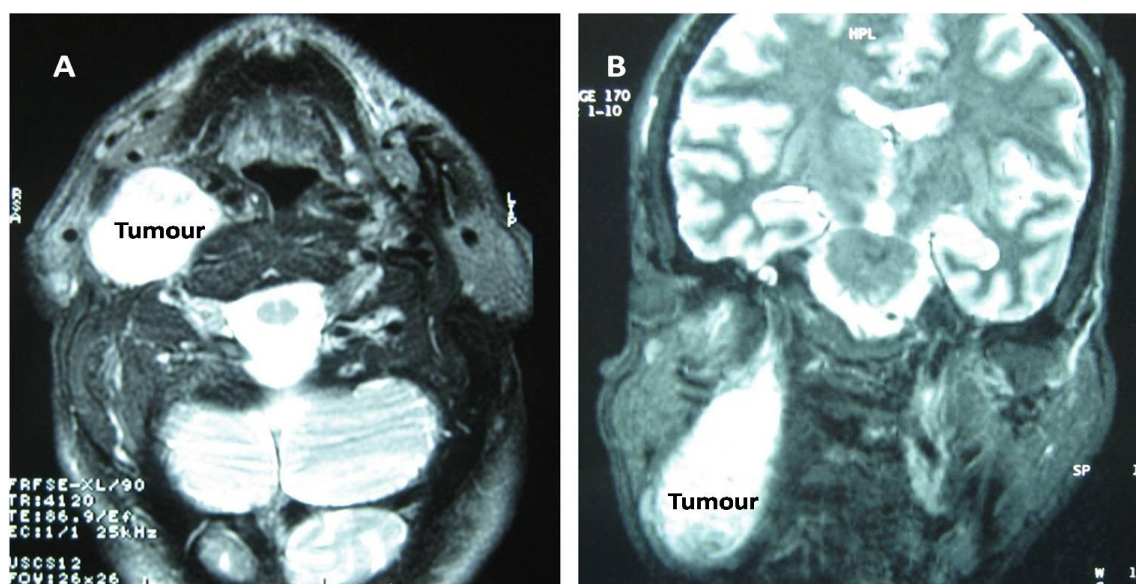


Figure 2: Intraoperative view of the tumor.

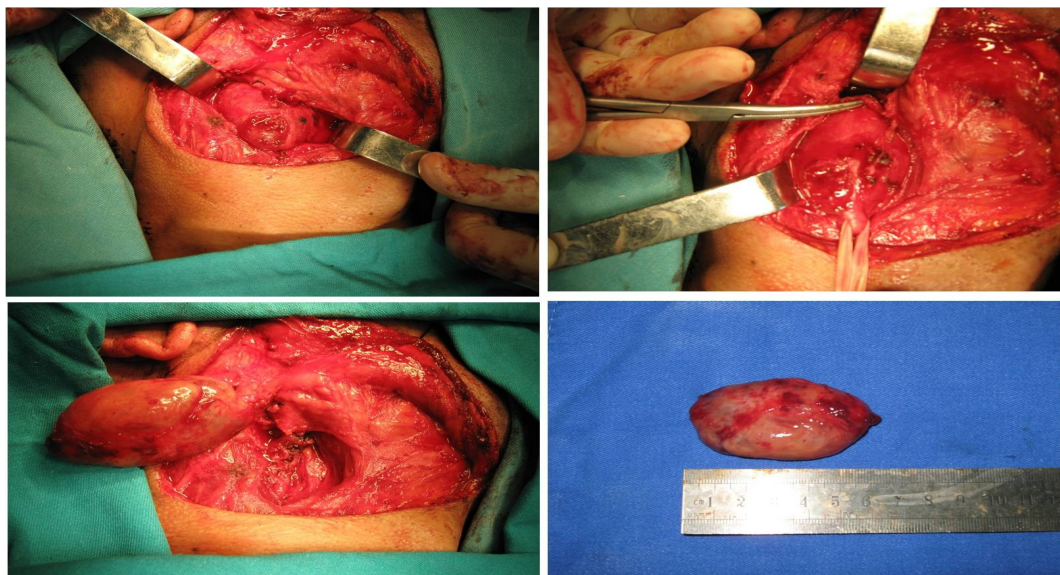
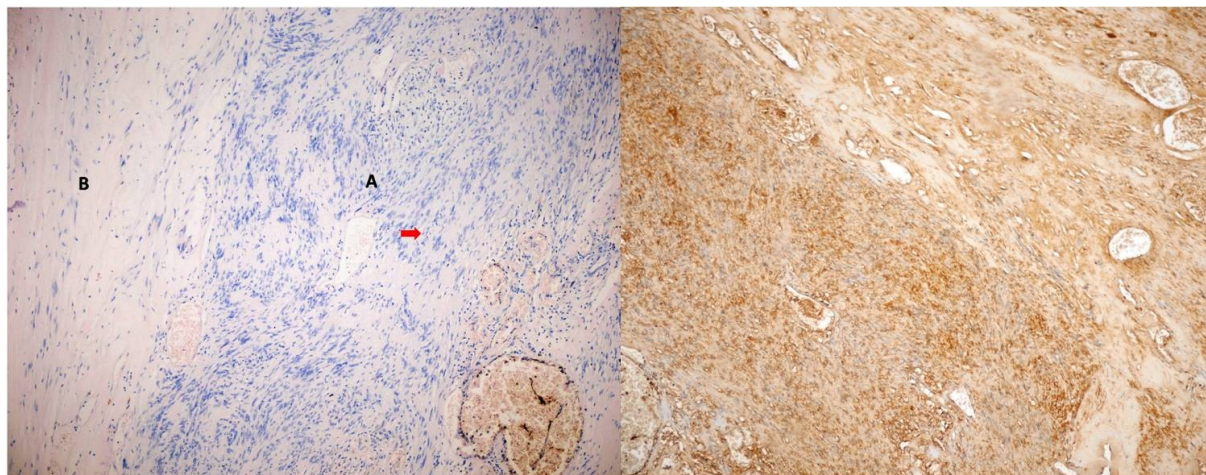


Figure 3: (Left) Histopathological appearance of the schwannoma which includes characteristic verocay bodies (arrow) along with the presence of Antony A areas (A) and Antony B areas (B) (H&E, X 100). (Right) The S-100 positivity on immunohistochemical staining of tumour cells (x200).



Discussion

Approximately 25–45% of extracranial schwannomas are present in the head and neck area; the most commonly affected regions are the temporal bone, lateral neck, and paranasal sinuses (3). Among the cranial nerves, schwannomas can arise from the glossopharyngeal, accessory, and hypoglossal nerves, while the most common type is acoustic neurinoma differentiating from the vestibulocochlear nerve (1,3). The involvement of the vagus nerve has been reported in 10% of all cases, although the prevalence may be as high as 29% depending on the study population (3,4). In fact, non-vestibular extracranial head and neck schwannomas are more common but less researched than their relatively more morbid intracranial acoustic counterpart.

In general, the tumor is more common in men aged 30–60 years; however, in their case series including 15 patients, Torosian et al. reported that two-thirds of the cases with extracranial schwannoma were female (4,5). Three-quarters of the cases presented with an asymptomatic painless neck mass that was firm and slow growing (1,3,5). In symptomatic patients, the most common complaint is hoarseness and coughing, which can be revealed during palpation of the mass. The cough is caused by stimulation of afferent vagal nerve endings due to prominent cystic degeneration of the tumor (3,6). Similarly, in the presenting case, a paroxysmal cough provoked by pressure on the mass was also noted. This clinical sign is quite specific for cervical vagal schwannomas.

A preoperative diagnosis of CVS may be difficult, and is often not made up to the time of surgery (2-4). However, diagnostic techniques in the form of FNA and imaging modalities, including computed tomography (CT) and MRI scans, have lessened the problem of misdiagnosis to some degree. The

tumor size, localization, extent, and the surrounding anatomy can be clarified with imaging techniques, thereby allowing surgical planning to be performed. As noted in the presenting case, schwannomas have specific MRI properties, including specific signs (split fat sign, fascicular sign, target sign) and signal patterns (i.e., isointense T1 signal relative to skeletal muscle; increased and slightly heterogeneous T2 signal) (7). Biswas et al. have reported their 10 years of experience regarding extracranial head and neck schwannomas, and in their report, only 6% of patients can be diagnosed preoperatively on the basis of clinical findings, CT and MRI scans, and FNA (8). In the present case, FNA was carried out but the result was inconclusive. Similarly, Kang et al. reported that the cytological diagnosis of schwannoma was only definitive in 20% of cases, based on the observation of characteristic Verocay bodies and spindle cells (3). On histological examination, the tumor exhibits two main patterns: Anthony A and Anthony B. The Anthony A areas are composed of compact spindle cells with indistinct cytoplasmic borders; in contrast, Anthony B areas are regions of looser schwann cell proliferation (7,8). A mixed picture of both areas exists in a large proportion of cases.

The management of schwannomas is problematic. The definitive treatment is complete resection of the tumor, but this approach conflicts with the surgical instinct to preserve the nerve of origin (4,5). Kang et al. reported that more than half of surgically treated cases exhibited postoperative neural deficits that were primarily caused by iatrogenic injury to either the nerve of origin or adjacent neural endings (3). It has been reported that surgical resection of vagal schwannomas is associated with vocal cord palsy and hoarseness (4). In our case, however, after total excision of the tumor, the preoperative symptoms, including hoarseness and paroxysmal provoked coughing, were somewhat alleviated. During operation, an attentive surgical technique with gentle and careful dissection of the fascicles of the nerve and extreme caution to protect the adjacent structures is essential to avoid unwanted postoperative neural compromise. The malignant potential of extracranial schwannomas and the risk of recurrence after surgical resection are unclear (1,2), although in most studies investigating extracranial schwannomas, recurrence or malign transformation of the tumor have not been reported (3,8). At 3-year follow-up of the present case, there was no evidence of recurrence.

In conclusion, as benign and slow growing tumors of the head and neck, schwannomas are rare and potentially morbid lesions. The preoperative diagnosis is mainly based on clinical suspicion and assisted imaging techniques, including ultrasound, CT, and MRI scans. Complete resection of the

tumor is the treatment of choice. However, a careful surgical technique is mandatory for tumor clearance and to reduce postoperative complications.

References

- 1- Colreavy MP, Lacy PD, Hughes J, Bouchier-Hayes D, Brennan P, O'Dwyer AJ, et al. Head and neck schwannomas—a 10 year review. *J Laryngol Otol* 2000;114:119-24.
- 2- Langner E, Del Negro A, Akashi HK, Araújo PP, Tincani AJ, Martins AS. Schwannomas in the head and neck: retrospective analysis of 21 patients and review of the literature. *Sao Paulo Med J.* 2007 5;125(4):220-2.
- 3- Kang GC, Soo KC, Lim DT. Extracranial non-vestibular head and neck schwannomas: a ten-year experience. *Ann Acad Med Singapore.* 2007;36(4):233-8.
- 4- Leu YS, Chang KC. Extracranial head and neck schwannomas: a review of 8 years experience. *Acta Otolaryngol* 2002;122:435-7.
- 5- Torossian JM, Beziat JL, Abou Chebel N, Devouassoux-Shisheboran M, Fischer G. Extracranial cephalic schwannomas: a series of 15 patients. *J Craniofac Surg* 1999;10:389-94.
- 6- Morrissey MS, Sellars SL. Vagal nerve schwannoma—a new diagnostic sign. *Postgrad Med J.* 1990 ; 66(771):42-3.

7- Beaman FD, Kransdorf MJ, Menke DM. Schwannoma: radiologicpathologic correlation. *Radiographics* 2004;24:1477-81.

8- Biswas D, Marnane CN, Mal R, Baldwin D. Extracranial head and neck schwannomas--a 10-year review. *Auris Nasus Larynx*. 2007;34(3):353-9.