

# Retinal sensitivity improves in the long term after internal limiting membrane peeling in vitro-macular surgery.

Agnes Glacet-Bernard\*

Department of Ophthalmology, Intercommunal Hospital Center and Henri Mondor Hospital, Paris-Est Creteil University (UPEC, Paris XII University), Creteil, France

Accepted on 20 May, 2021

## Introduction

The Creteil team followed up eleven patients who underwent Epiretinal Membrane (ERM) and Internal Limiting Membrane (ILM) removal for 18 months using microperimetry (MP-3 Microperimeter®, Nidek, Japan), which allows very accurate measurement of retinal sensitivity in the macular region before and after surgery.

## Methods

Patients with vitreomacular interface disease requiring vitrectomy underwent multimodal retinal imaging, including visual acuity assessment, fundus color photograph, infrared, autofluorescence, Spectral-Domain Optical Coherence Tomography, Optical Coherence Tomography-Angiography and microperimetry (MP-3 Microperimeter®, Nidek, Japan). They were examined at baseline (M0), 6 months (M6) and 18 months (M18) after surgery. Retinal sensitivity was subdivided into three concentric polygons: Large, Medium, Small [1-3].

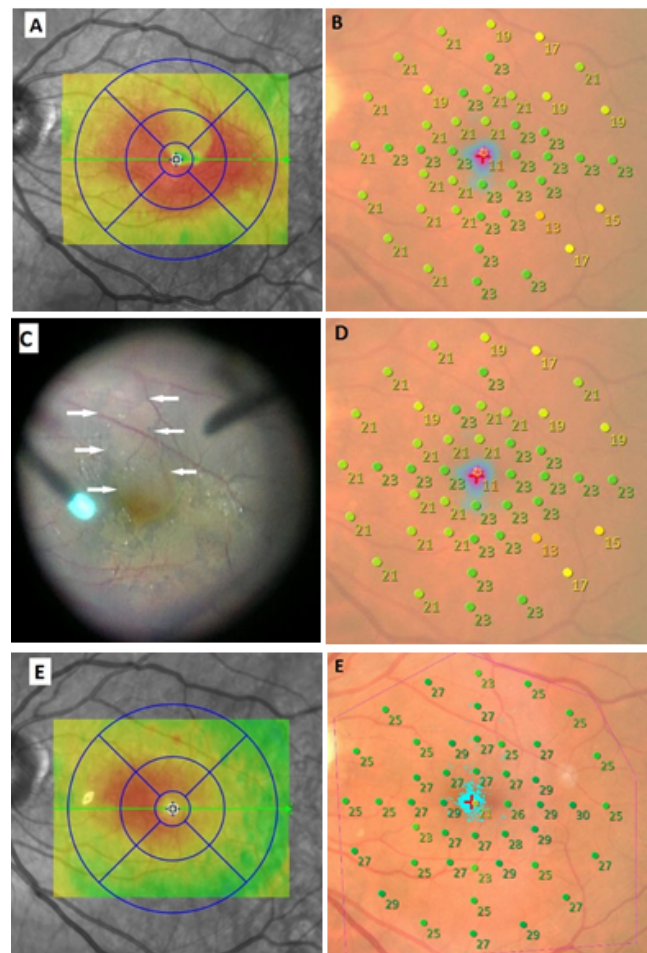
## Results and Discussion

Eleven eyes of 11 patients were analyzed, including 10 Epiretinal Membranes (ERMs) and 1 macular hole. Mean age was 68 years old. Best-Corrected Visual Acuity (BCVA) improved in all patients from 0.51 logarithm of the minimal angle of resolution (logMAR) to 0.067 with a statistically significant difference ( $p=0.0074$ ). Retinal sensitivity improved between M0 and M6 in all polygons and continued to improve between M6 and M18 for polygons Medium (M) and Small (S) with no statistical significance. At M18, BCVA and retinal sensitivity were similar in the operated eye compared with the fellow eye for all patients. Dissociated optic nerve fiber layer appearance was observed in 75% patients at M18. It was not correlated with either retinal sensitivity or BCVA or microscotomas. No recurrence of ERM or macular hole occurred during follow-up.

One year after the first surgery, BCVA was 20/63 with persistence of metamorphopsia.

SD-OCT showed a thickening of the macular region with a « double wings » shape. Intraoperative findings showed the presence of ERM in front of the persistent Brilliant Blue®-colored ILM; a small part of the ILM had been spontaneously removed with the ERM during the first surgical procedure in the supero-macular zone (arrows), but ILM was still present at the fovea, responsible for visual loss and decrease in retinal sensitivity. The area of the spontaneous removal of the ILM corresponded to the area of

normal retinal thickness on the preoperative SD-OCT. Six months after the peeling of the ILM, both BCVA and retinal sensitivity improved to 20/32 and 26.2. At M18, BCVA and retinal sensitivity continued to improve respectively to 20/25 and 26.4 dB with no ERM recurrence (Figure 1).



**Figure 1.** ERM surgery in a 56-year-old male who had previous surgery without internal limiting membrane removal.

This case is interesting because it shows that the presence of a pathological ILM following the first surgery is responsible for a decrease in vision and retinal sensitivity. Secondary peeling of the ILM results in normalization of retinal acuity and retinal sensitivity. Peeling of the ILM does not seem to have a deleterious effect in itself [3-6].

## Conclusion

After surgery, the retinal sensitivity assessed by microperimetry gradually improved until the 18<sup>th</sup> month, and at the end was not

different from the values of the fellow eye. These results seemed to confirm that ILM peeling can be an effective and safe technique to treat patients with vitreomacular interface disease.

## References

1. Blautain B, Glacet-Bernard A, Blanco-Garavito R, et al. Long-term follow-up of retinal sensitivity assessed by microperimetry in patients with internal limiting membrane peeling. *Eur J Ophthalmol*. 2021;1120672121997300.
2. Kwok AKh, Lai TY, Yuen KS. Epiretinal membrane surgery with or without internal limiting membrane peeling. *Clin Exp Ophthalmol*. 2005;33:379-85.
3. Feldman A, Zerbib J, Glacet-Bernard A, et al. Clinical Evaluation of the Use of Infracyanine Green Staining for Internal Limiting Membrane Peeling in Epimacular Membrane Surgery. *Eur J Ophthalmol*. 2008;18:972-9.
4. Tadayoni R, Svorenova I, Erginay A, et al. Decreased retinal sensitivity after internal limiting membrane peeling for macular hole surgery. *Br J Ophthalmol*. 2012;96:1513-6.
5. Park SH, Kim YJ, Lee SJ. Incidence of and risk factors for dissociated optic nerve fiber layer after epiretinal membrane surgery. *Retina*. 2016;36:1469-73.
6. Kim YJ, Lee KS, Joe SG, et al. Incidence and quantitative analysis of dissociated optic nerve fiber layer appearance: real loss of retinal nerve fiber layer? *Eur J Ophthalmol*. 2018;28:317-323.

## \*Correspondence to

Dr. Agnes Glacet-Bernard

Department of Ophthalmology

Intercommunal Hospital Center and Henri Mondor Hospital,  
Paris-Est Creteil University,

Creteil, France

E-mail: [agnes.glacet@chicreteil.fr](mailto:agnes.glacet@chicreteil.fr)