



## Recurrent Laryngeal Nerve: Anatomical perspective

Lalruatkimi K

Balasubramanian Thiagarajan

Stanley Medical College

### Abstract:

The recurrent laryngeal nerve can be a real challenge to the surgeon operating in its area. This article highlights the normal anatomy, anatomical variants and ways to identify the nerve as the consequences of its injury can have a life changing impact on both the patient and the surgeon. It should be borne in mind that the anatomy of recurrent laryngeal nerve differs between both sides. These anatomical differences between the course of the nerve on both sides could be attributed to the embryological development which varies between sides.

### Introduction:

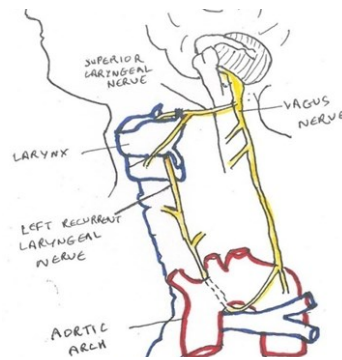
The risk of injury to the recurrent laryngeal nerve is related to the level of knowledge acquired about the anatomy and the experience of the surgeon. The larynx protects the lower respiratory tract, generates voice, provides a controlled airway, and generation of a high intrathoracic pressure for coughing and lifting. Lahey was an advocate for identification of the RLN by introducing the routine dissection and demonstration of the RLN during thyroid surgery<sup>1</sup>. A unilateral RLN paralysis may pass undetected as about one-third of the patients are asymptomatic. Others may have some change in voice but no problem of aspiration or airway obstruction.

In a bilateral abductor paralysis, both vocal cords lie in median or paramedian position due to unopposed action of the cricothyroid muscle. Here the voice is good but may lead to dyspnea or stridor which needs further management.<sup>2</sup> The left RLN is more liable to injury than the right because of its longer course than the right. The incidence of a unilateral vocal cord paralysis is more than a bilateral paralysis.<sup>3</sup> As the rates of laryngeal and thyroid surgery increases as attributed by technological advances and increase in incidence of laryngeal carcinoma the need to put more emphasis on the recurrent laryngeal nerve arises. Preoperative assessment of vocal cord status will help to determine the extent of injury to the nerve postoperatively, if any.<sup>4</sup>

**Anatomy:**

The physician Galen first documented the existence of the RLN and he was also the first to demonstrate that the larynx generates voice. The RLN is variable in size ranging from 1.5-4 mm in diameter. It can be identified by its whitish appearance, characteristic longitudinal vessel running along its length and its flattened, rounded surface. In up to 39% of cases the nerve divides into two (and occasionally up to 6) terminal branches, one of it called the A

brief detail into the embryology: The nerve of the sixth pharyngeal arch becomes RLN. The primitive RLN enters the 6th visceral arch on each side below the 6th aortic arch artery. On the left side, the arch artery retain its position as the ductus arteriosus so the nerve is found below the ligamentum arteriosum after birth. On the right side, the 6th and 5th arch artery disappear leaving below the 4th arch artery and becomes the subclavian artery.<sup>6</sup>



Diagrammatic representation of left recurrent laryngeal nerve

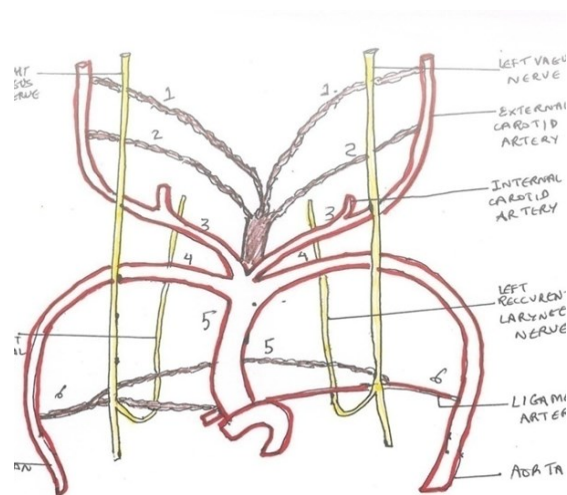


Fig :The relationship between development of the branchial arches and recurrent laryngeal nerves. The number indicates the number of the branchial arch.

This developmental pattern explains why on the left side the nerve leaves the vagus at the level of aortic arch, winds below the arch whereas the right RLN arises from the main trunk of vagus in front of the subclavian artery before passing superiorly to lie in the tracheoesophageal groove (where it forms the third side of Behr's triangle, the other two sides of the triangle are formed by the common carotid and inferior thyroid arteries). The nerve may be behind or within the Ligament of Berry. Then the RLN passes deep to the lower border of inferior constrictor muscle and immediately behind the cricothyroid joint and finally enters into the larynx. The approximate length of the left RLN is 12 cms and about 6 cms only on the right side.<sup>7</sup>

It divides into motor and sensory branches. The motor branch has fibres derived from the cranial root of the accessory nerve which supply all the intrinsic muscle of the larynx, except the cricothyroid. The sensory branch supplies the laryngeal mucosa below the level of the vocal folds and also carries afferent fibres from stretch receptors in the larynx.

In the neck region, it carries sensory, secretory and motor fibres to the cervical segments of the esophagus and the trachea.

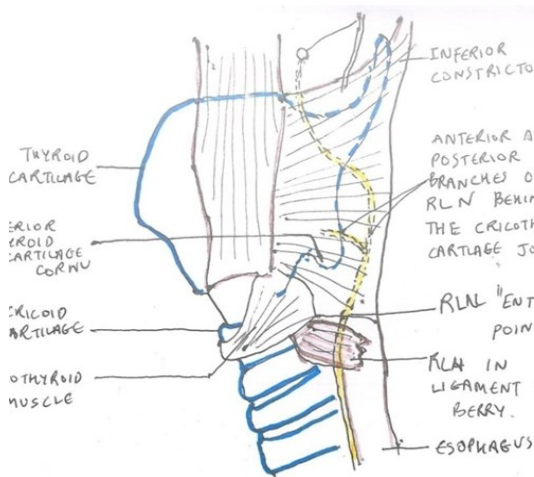


Figure showing relationship of recurrent laryngeal nerve with that of Berry's ligament

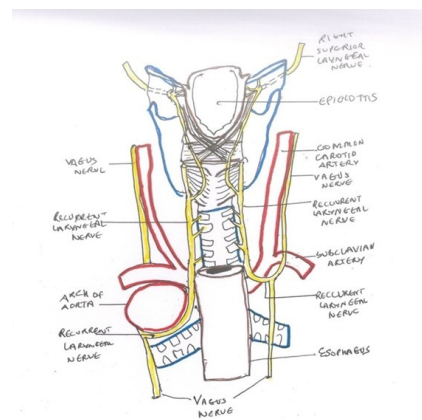


Fig: showing the posterior view of the larynx showing the distribution of the RLN

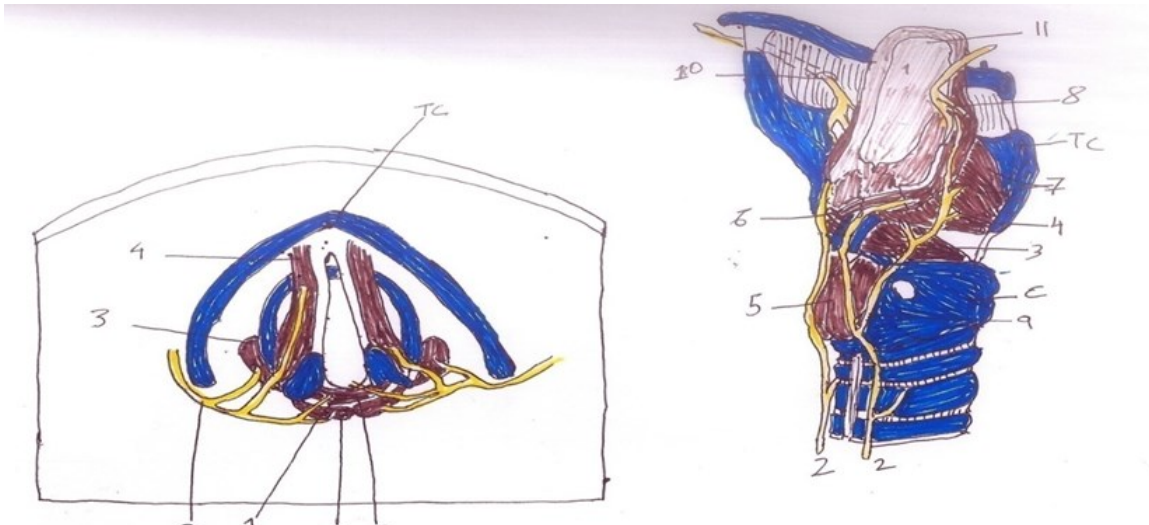


Fig: Intrinsic laryngeal musculature and innervations schematic. 1. Location of interarytenoid neural plexus 2. RLN 3. Lateral cricoarytenoid muscle 4. Thyroarytenoid muscle glottis 5. Posterior cricoarytenoid muscle. 6. Interarytenoid muscle 7. Thyroepiglottic muscle supraglottic 8. Anastomosis of vagus 9. RLN 10. Superior Laryngeal nerve 11. Epiglottis A-Arytenoid ; T-Thyroid cartilage C-Cricoid cartilage

Because of its extensive course, the left RLN is more liable to injury than the right and is especially vulnerable to pressure from aortic aneurysm, thoracic surgery and intrathoracic masses. It is also easily injured during thyroid surgery due to its viable relationship with the inferior thyroid artery i.e. it may lie behind, between or superficial to it. It may lie lateral, medial or within the suspensory ligament of Berry just before it enters the larynx, therefore care must be taken during thyroid dissection.<sup>9</sup>

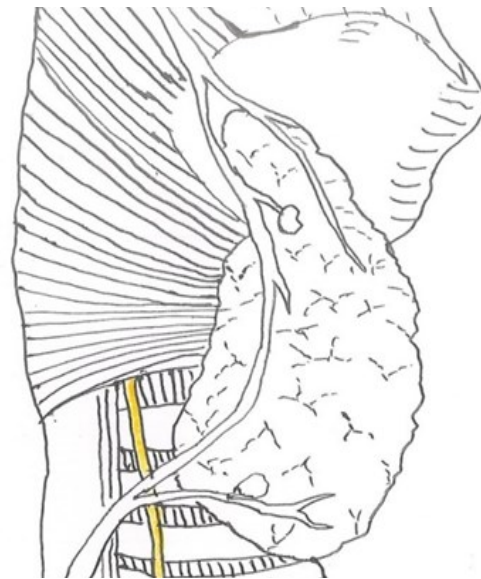


Fig: showing a common relationship between superior and inferior thyroid arteries, parathyroid glands

## Anatomical Variations:

Extra-laryngeal branches, distorted RLN, intertwining between branches of the nerve and inferior thyroid artery and non-recurrent laryngeal nerve can be a potential cause of nerve injury due to visual misidentification especially in thyroid operation .

A rare anomaly includes the non-recurrent laryngeal nerve , branching off the vagus around the level of the cricoid cartilage. Typically, such a configuration is accompanied by variation in the arrangement of the major arteries in the chest; most commonly, the right subclavian artery arises from the left side of the aorta and crosses behind the esophagus.<sup>10</sup> A left non-recurrent inferior laryngeal nerve is even more uncommon, requiring the aortic arch to be on the right side, accompanied by an arterial variant which prevents the nerve from being drawn into the chest by the left subclavian.

In about four people out of five, there is a connecting branch between the inferior laryngeal nerve, a branch of the RLN, and the internal laryngeal nerve, a branch of the superior laryngeal nerve. This is commonly called the anastomosis of Galen.<sup>11</sup>

Points to remember in identification of the nerves:

1. Know the anatomy and its anatomical variants of the RLN.
2. Identify landmarks for the RLN 's entry point: [a] approximately 1cm below caudal to the thyroid cartilage's inferior horn, which can be easily palpated. Or [b] just lateral to the anterior arch of the cricoid which marks the lower edge of the cricoid cartilage .<sup>12</sup>
3. It is important to provide good surgical field for identifying the nerve by maintaining hemostasis.<sup>13</sup>
4. The Ligament of Berry: The dense and vascular nature of the ligament of Berry, the multiple branches of the RLN that can be present at this level, the potential for a bend or genu of the nerve at its laryngeal entry point and the close relationship of thyroid tissue to this ligament all make this area the most difficult region of nerve dissection during thyroidectomy.
5. Adopt a particular approach: Locate the nerve where it enter the larynx, superior-inferior direction or locate the nerve in tracheoesophageal groove and trace it in the superior direction, inferior-superior direction.
6. During thyroidectomy, never cut any band of tissue in the distribution of the RLN that is not transparent without neural stimulation.

7. Making use of devices: Vagal stimulation provides a positive EMG signal so that neural mapping and search for the nerve can be achieved. Others include Operating loupes with at least 4 times magnification or intraoperative nerve monitoring (IONM).

#### Conclusion:

It is important for a surgeon operating in the head and neck region to be well-versed about every detail of the recurrent laryngeal nerve and be aware of the postoperative complications due to injury so as to avoid significant morbidity and medicolegal issues that may arise out of it.

## References:

1. Randolph GW. Surgery anatomy and monitoring of the recurrent laryngeal nerve; Surgery of the Thyroid and Parathyroid glands, 2nd edition, 2013, p.306
2. Johnson JT, Rosen CA, Treatment of Vocal Fold Paralysis: Bailey's Head and Neck Surgery, Otolaryngology, 5th edition, 2014, p.1005-19
3. Johnson JT, Rosen CA, Pediatric voice : Bailey's Head and Neck Surgery, Otolaryngology, 5th edition, 2014, p.1377
4. Randolph GW. Surgery anatomy and monitoring of the recurrent laryngeal nerve; Surgery of the Thyroid and Parathyroid glands, 2nd edition, 2013, p.307
5. Kaplan EL, et al. History of the recurrent laryngeal nerve : from Galen to Lahey. World J Surg. 2009.
6. Gleeson MJ, Clarke RC, Anatomy of the larynx and tracheobronchial tree ; Scott-Brown's Otorhinolaryngology, Head and Neck Surgery, 7th edition, 2008, p.2130-1
7. Drtbalu's Otolaryngology Online, Applied anatomy of recurrent laryngeal nerve
8. Rosen CA, Simpson CB. Operative techniques in laryngology , New York, NY; Springer, 2008
9. Gleeson MJ, Clarke RC; The thyroid gland: anatomy and physiology , Scott-Brown's Otorhinolaryngology, Head and Neck Surgery, 7th edition, 2008, p.317.
10. Mahmudlou R, Aghasi MR, Sepehrvand N; Identifying the Non-recurrent Laryngeal Nerve: Preventing a Major Risk of Morbidity During Thyroidectomy; Int J Prev Med, 2013 Feb; 4(2)237-240
11. Samudo JR, Marañillo E , Leon X, Mirapeix Rm, Orus C, QUER M; An Anatomical Study of Anastomosis Between the Laryngeal Nerve , Laryngoscope, 1999, Jun. 109(6):983-7
12. Randolph GW, Surgical anatomy of the Recurrent Laryngeal Nerve, Randolph GW.ed. Surgery of the Thyroid and Parathyroid Glands 2nd edition, 2013, p.318
13. Thiagarajan B, Ramamoorthy G. Preventing Nerve Damage During Thyroid Surgery. WebmedCentral, Otolaryngology 2012;3(4)