



## **Prevalence of Laryngeal Cartilage Calcifications in Mangalore population; a Radiographic Study**

<sup>1</sup> Nandita Shenoy, <sup>1</sup>Junaid Ahmed, <sup>2</sup>Sumanth K N, <sup>1</sup>Srikant N S, <sup>1</sup>Santosh Rai, <sup>3</sup> Muralidhar Yadiyal

<sup>1</sup> Manipal college of Dental sciences, Mangalore <sup>2</sup> Melaka Manipal Dental College, Melaka

<sup>3</sup> Kasturba Medical College, Mangalore

### **Introduction:**

Soft tissue calcifications in the orofacial region are uncommon and are usually asymptomatic in nature. Some of the common calcifications found are Carotid artery calcifications (CAC), Triticeous cartilage, and Superior cornu of the thyroid cartilage, Tonsilloliths and lymph nodes calcifications. Disordered ossification or calcification of ligaments or cartilages may compress neurovascular structures, may be able to cause serious implications in any surgical intervention in the region, may lead to false neurological differential diagnosis or may be benign in nature without any clinical significance. Ossification and calcification of the laryngeal cartilages have been widely investigated since the original study by Chievitz in 1882<sup>1</sup>. The thyroid, cricoid, and greater part of the arytenoid cartilages consist of hyaline cartilage that undergoes calcification and ossification as part of the ageing process. The thyroid cartilage tends to be visible on the cephalometric and lateral neck radiograph when

the ossification starts within the lamina or either of the cornua. The cricoids and arytenoid cartilages also become apparent when the ossification begins within their laminae. Radiographs of the head and neck are used to study the growth and development of skeletal structures can be used for identification of these calcifications<sup>2</sup>. A good understanding of the anatomy and the knowledge of variations in the laryngeal cartilage ossification is important for all clinicians especially while interpreting head and neck radiographs of patients who exhibit anatomical or functional deviations from the normal.

The lateral cephalometric radiographs are advised more commonly by an orthodontist to look for occlusion and lateral profile of the patient pre and post orthodontic treatment. They also demonstrate the posterosuperior part of the lamina, and the superior cornu of the thyroid cartilage. Laryngeal and related cartilages like the cricoid and triticeal cartilages may also be visualised in the cephalometric radiograph once ossified.

The aim of this study was to assess the prevalence of Laryngeal cartilage calcification among patients attending dental OPD at Mangalore, Dakshina Kannada.

### **Materials and Methods**

A retrospective study was conducted using lateral cephalometric radiographs from the archives of the Department of Oral Medicine and Radiology and Department of Orthodontics, Manipal College of Dental Sciences; Mangalore for seven years dating from 2005 to 2012. These lateral cephalometric radiographs were obtained on Kodak T-Mat G/RA film (Eastman Kodak Company, Rochester, NY) with a standard cassette containing an intensifying screen and these radiographs were taken in the Planmeca Promax machine and were manually processed in a processing tank under standard conditions. All lateral cephs were viewed in a dark room using an X-ray viewer, and interpreted. A maxillofacial radiologist, experienced in

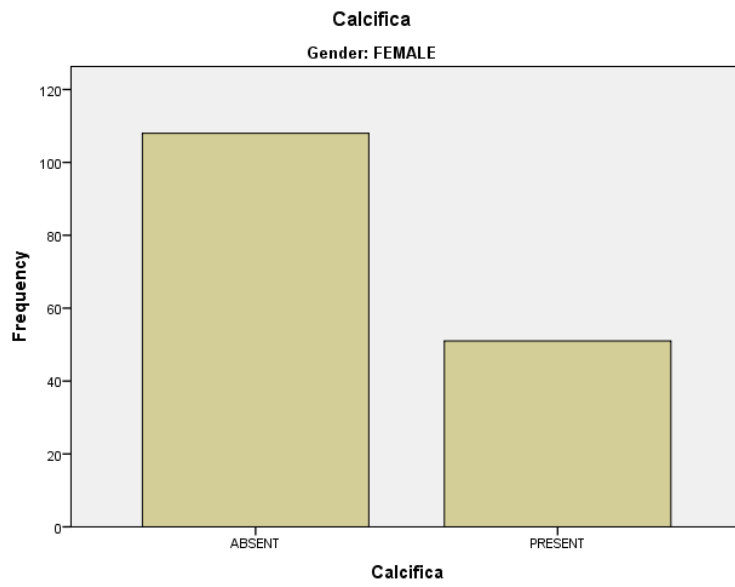
musculoskeletal imaging independently evaluated the images. Consensus on the anatomic locations and general principles of identification of ossification in the head and neck region was achieved between the two radiologists.

Observations were documented in a proforma, which included patient's demographic details, presence or absence of calcification, site and number of calcifications. The frequency distribution was calculated by using the computer program SPSS 17.

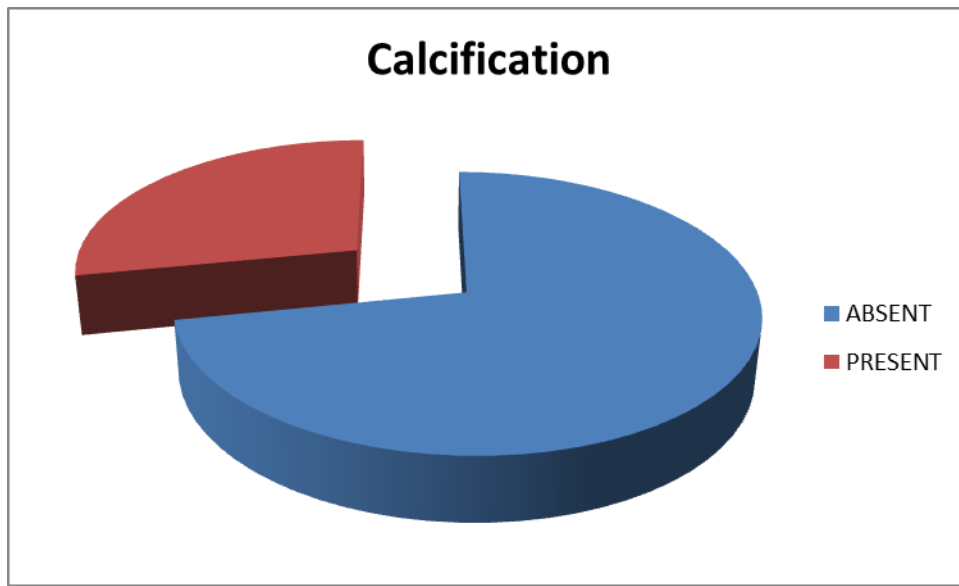
## **Results**

This study included the radiographs of 252 patients (92 male and 160 female; Figure 1) ranging in age from 18 to 59 years. Various degrees of thyroid and cricoid cartilage ossification were found among both males and females beyond the third decade. The frequency of Laryngeal calcification differed between the genders. The frequency of ossification was varied in our study population as it was present only in 28% of the population (Figure 2). The level of calcification also differed in their number and position (Figure 3,4). Calcifications were more in the fifth level of Laryngeal bone and the number of calcifications varied from two to six in number. Ossification of the thyroid and cricoid cartilages varied from linear shadows to dense laminar calcifications in patients who were in their third decade and beyond. Ossification of thyroid and cricoid cartilages gradually increased with age in both the sexes.

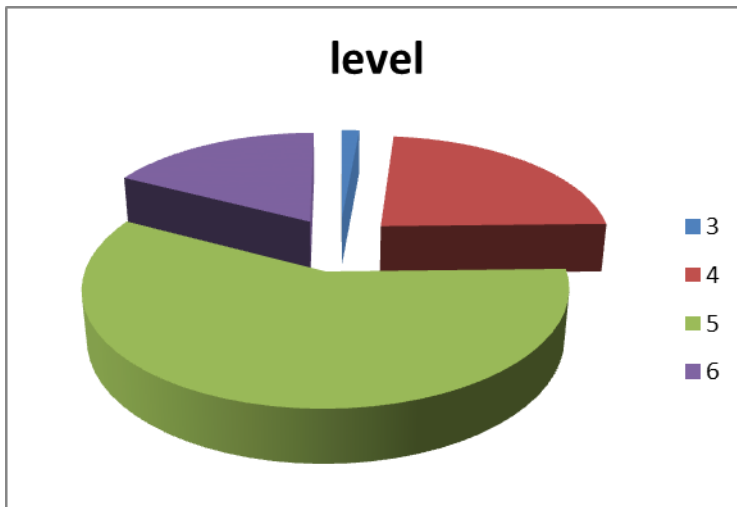
**Figure 1**



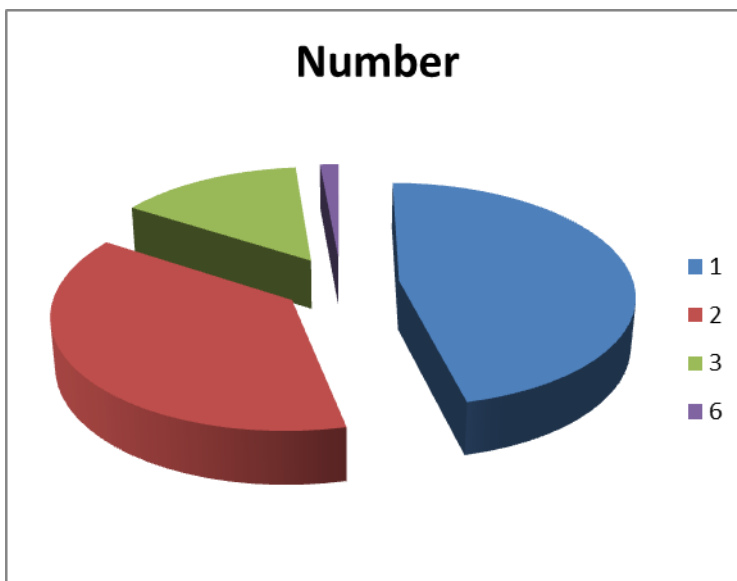
**Figure 2**



**Figure 3**



**Figure 4**



**Discussion**

The laryngeal skeleton is made up of several components that are composed initially of hyaline cartilage. With aging, the corniculate and cuneiform cartilages, the epiglottis, and the apices of arytenoids gets transformed into elastic cartilage<sup>3</sup>. The thyroid, cricoid, triticeal, and the greater part of the arytenoid cartilage remain hyaline and may undergo calcification and become evident on a radiograph. Even though these get ossified after the age 20, early ossifications are not rare<sup>4</sup>. Vlcek<sup>5</sup> showed that estimation of an individual's age can in some cases be done by taking advantage of the degree of progression of thyroid calcification so

long as the cartilage has remained preserved. This method has been used in forensic medicine to estimate the age of unknown skeletal remains. Hatley et al<sup>6</sup> in their study gave a detailed description of the stages of ossification of thyroid cartilage. They mentioned that ossification begins in the inferior portion of the posterior third of the lamina and in the inferior horn. The variability of ossification of the laryngeal cartilage makes prediction of a pathologic condition from plain films unreliable as ossified cartilages create a diagnostic problem for the radiologist looking for foreign bodies<sup>3</sup> even though ossification of the laryngeal cartilages is usually symmetrical..

Similar studies<sup>7,8</sup> done in the past have reported that ossifications are first seen in the thyroid, followed by cricoid and the arytenoids. In both males and females, the ossification began at the age of 18 to 20 years in the posterior part of the thyroid cartilage, same as our study.

There is a general trend of increase in the ossification of laryngeal cartilages as the age advances. Terminal differentiation and mineralization of human thyroid cartilage usually occurs after the end of adolescence<sup>9</sup>. If a tendency for thyroid or cricoid ossification is noticed at a very early age, the patient should be examined for signs of underlying systemic disease or metastases. Ossified thyroid cartilages may compress the neuro vascular structures around it. Ossified thyroid cartilages may compress the recurrent laryngeal nerve, bilateral nerve damage can result in breathing difficulties and aphonia (the inability to speak)<sup>10</sup>. As calcified normal structures, particularly the laryngeal cartilages can mimic abnormal radio-opaque foreign bodies, it is important for the radiologist to be able to recognise the normal variant in the form of a benign calcification from a foreign body seen on a lateral cephalogram.

The presence of the ossified cartilages noted in this study is not a common findings, which may not be detected unless symptomatic, the clinical significance is usually difficult to interpret. The anatomical knowledge of early ossified thyroid cartilages very important for surgeons as it may increase the success of surgical approaches to the region. The radiologist should be vigilant while interpreting the lateral cephalometric radiographs for growth and development. Thus, ossification should be considered a physiologic variation in the absence of clinical symptoms. They should be considered along with the other frequently occurring ossifications within the head and neck structures like the stylohyoid ligaments.

## **References**

1. J. Galline, K. Marsot-Dupuch, P. Bigel, and P. Lasjaunias: Bilateral Dystrophic Ossification of the Thyroid Cartilage Appearing as Symmetrical Laryngeal Masses AJNR Am J Neuroradiol 2005; 26(3), 1339–1341
2. Muralidhar Mupparapu, Anitha Vuppalapati, Ossification of Laryngeal Cartilages on Lateral Cephalometric Radiographs. Angle Orthodontist, 2005; Vol 75, No 2, 196-201
3. Snell RS. Clinical Anatomy for Medical Students. 6th ed. Baltimore, Md: Williams & Wilkins; 2000:744–748.
4. Gray H. Anatomy of the Human Body. Philadelphia, Pa: Lea & Febiger; 1918. Available at: <http://www.bartleby.com/107/236.html>. Accessed: Dec 26, 2013
5. Vlcek E. Estimation of age from skeletal material based on the degree of thyroid cartilage ossification. Soud Lek. 1980;25:6–11.
6. Hatley W, Gordon E, Samuel E. The pattern of ossification in the laryngeal cartilages: a radiological study. Br J Radiol. 1965;38: 585–591.
7. Kirsch T, Claassen H. Matrix vesicles mediate mineralization of human thyroid cartilage. Calc Tissue Int. 2000;66:292–29
8. Fukatsu H, Makino N, Kodama Y, Ikeda M, Ishigaki T, Sakuma S. Evaluation of thyroid calcification using computed radiography with image plate. Eur J Radiol. 1989;9:22–28.
9. Rubin MM, Krost BS. Calcification of the thyroid cartilage mistaken for an aspirated tooth. J Oral Maxillofacial Surg 1991;49:745-6.
10. Potts Jr JT. Diseases of the parathyroid gland and other hyper and hypocalcemic disorders. In: Fauci AS, Braunwald E, Isselbacher KJ, et al, eds. Harrison's Principles of Internal Medicine. Vol 2. 14th Ed. New York: McGraw Hill 1998, 2227–36.