



**PREDILECTION OF SITE IN CHRONIC RHINOSINUSITIS: TOMOGRAPHIC
FINDINGS IN 100 PATIENTS**

**Jyothi A C¹, Shrikrishna B H² , Sanjay G³, Sandeep Samson G⁴, Sameena kokab⁵,
Sreekantha⁶.**

1,2-Associate Professors, Department of ENT, Navodaya Medical College, Raichur, Karnataka.

3,4-Senior Residents, Department of ENT, Navodaya Medical College, Raichur, Karnataka.

5- Assistant Professor, Department of Ophthalmology, Navodaya Medical
College, Raichur, Karnataka.

6- Associate Professor, Department of Biochemistry, Navodaya Medical
College, Raichur, Karnataka.

ABSTRACT

OBJECTIVE:To study the pattern of mucosal involvement in chronic rhinosinusitis using computed tomography of 100 patients.

DESIGN:A prospective study of mucosal involvement of paranasal sinus region was done on 100 computed tomography scans of patients with chronic rhinosinusitis.

RESULTS: The most common site of involvement was osteomeatal complex followed by maxillary antrum. This was followed by anterior ethmoids, posterior ethmoid, frontal sinus and sphenoid sinus, in that order.

CONCLUSION:Osteomeatal complex is the most common site to get involved in chronic rhinosinusitis. The blockade in the osteomeatal complex subsequently leads to impaired drainage and inflammation in maxillary, ethmoid and frontal sinuses. Removal of disease in Osteomeatal complex region is the basic principle of Functional Endoscopic Sinus Surgery which is best appreciated on CT scan.

KEY WORDS:Rhinosinusitis; tomography; maxillary sinus; ethmoid sinus; frontal sinus.

INTRODUCTION:

Rhinosinusitis is a common problem that leads to a significant amount of health care expenditure due to direct costs of doctor visits and antibiotics as well as indirect costs related to reduced productivity and a decreased quality of life(1,2). In 1996, the American Academy of Otolaryngology-Head and Neck Surgery standardized the terminology for paranasal infections(3). The term rhinosinusitis was believed more appropriate than sinusitis because rhinitis typically precedes sinusitis, purulent sinusitis without rhinitis is rare, the mucosa of the nose and sinuses are contiguous, and symptoms of nasal obstruction and discharge are prominent in sinusitis(4). The diagnosis of rhinosinusitis usually is based on symptoms indicating maxillary or frontal sinus involvement. This may occur secondary to, and is frequently a result of, ethmoid disease. Obstruction of the sinus ostia is the usual precursor of sinusitis(5,6).

Rhinosinusitis is divided into four categories based on the temporal course and the signs and symptoms of the disease: (1) acute rhinosinusitis is sudden in onset; it lasts from 1 day to 4 weeks and there is complete resolution of the symptoms; (2) recurrent acute rhinosinusitis requires four or more episodes of acute rhinosinusitis, lasting at least 7 days each, in any 1-year period; (3) sub acute rhinosinusitis is continuous with acute rhinosinusitis and lasts from 4 to 12 weeks; and (4) chronic rhinosinusitis requires that signs or symptoms persist for 12 weeks or longer and may be punctuated by acute infectious episodes(7).

It has been shown that mucosal thickening less than 4 mm in chronic rhinosinusitis is not normally of clinical importance, even though these patients may still have symptoms(8). Hence, in our study, we have taken CT scan with 4 mm or more mucosal thickening as positive for chronic rhinosinusitis. The present study was done to know the predilection of site in chronic

rhinosinusitis. This information will help in dealing the disease by endoscopic sinus surgeon by focusing on those particular areas.

MATERIALS AND METHODS:

This study was carried out at the Department of ENT and Head Neck Surgery, Navodaya Medical College, Raichur. One hundred patients with clinical features of chronic rhinosinusitis not responding to medical management were subjected to Computed Tomography (CT) of the paranasal sinus region. This is a prospective study, conducted over a period of 6 months from 1st January 2012 to 31st June 2012. The CT scans were selected depending on the following Inclusion/Exclusion criteria:

Inclusion Criteria:

1. Adult patients
2. Irrespective of socio-economic status.
3. Clinical diagnosis of Chronic Rhinosinusitis.
4. Total Lund MacKay score of 4 or more.

Exclusion Criteria:

1. History of previous sinus surgery.
2. History of benign tumours of sinonasal mucosa.
3. History of facial trauma.

All CT scans were obtained with GE Pro-Speed Plus 4 Slice Multidetector CT machine. After obtaining the scout projection, the area of scanning was defined to include the region from roof of frontal sinus up to the hard palate. Axial sections were performed with the patient in supine position and the plane of data acquisition parallel to hard palate. The sections were taken with slice thickness of 5 mm. Images were reconstructed at 4 mm intervals i.e. image overlap of 1 mm. Scanning parameters included 105 mA, 130 kV and tube rotation time of 1.5 seconds.

Coronal sections were performed with the patients in prone position with extended neck and the plane perpendicular to axial plane. The scan parameters were same as in axial plane. Extended cephalic / caudal sections were done in a few patients to see extension of the disease process.

Patients' CT scans were evaluated and staged according to the Lund Mackay system of scoring. (Each paranasal sinus [anterior ethmoid, posterior ethmoid, maxillary, frontal, and sphenoid sinus for each side] was given a score of 0 for no opacification, 1 for partial opacification, or 2 for total opacification.) The osteomeatal complex was assigned a score of 0 for patent or 2 for obstructed. The Lund score ranged from 0 to 24. In our study, we have included only those patients whose total Lund MacKay score was 4 or more.

ETHICAL CONSIDERATIONS:

The study got clearance by the Institutional Ethical Committee before its commencement. Also, a written informed consent was taken from all the patients before participating in the study.

RESULTS:

The patients were between 18 to 54 years of age (average age was 30.9 years). There were 53 males (53 %) and 47 females (47%). The CT scans analysis is shown in Table 1. The Lund scoring of the CT scans is shown in Table 2. Osteomeatal complex was the most common site involved in the study (Fig 1). It was involved in a total of 54 cases (54%). The second most common site was maxillary antrum (Fig 2). It was involved in a total of 50 cases (50%). The next common sites to get involved were anterior ethmoids (40%), posterior ethmoids (22%), frontal sinus (18%) and sphenoid sinus (13%).

Of the 54 cases with osteomeatal complex involvement, all the cases had a Lund score of 2. Of the 50 cases with maxillary sinus involvement, 34 cases were having Lund score of 1 and 16 cases were having Lund score of 2. Of the 40 cases with anterior ethmoid sinus involvement, 19 cases showed Lund score of 1 and 21 cases showed Lund score of 2. Of the 22 cases with posterior sinus involvement, 14 cases had Lund score of 1 and 8 cases had Lund score of 2. Of the 18 cases with frontal sinus involvement, 12 cases had Lund score of 1 and 6 cases had Lund score of 2. Of the 13 cases with sphenoid sinus involvement, 10 cases showed Lund score of 1 and 3 cases showed a Lund score of 2.

DISCUSSION:

The term rhinosinusitis refers to inflammation of the contiguous tissues of the upper respiratory tract, where insult to the nasal mucosa also affects adjacent sinus tissue. Sinus pain may distinguish sinusitis from rhinitis, although it is agreed that 12 weeks of sinus inflammation is required for a diagnosis of CRS(9).

The four pairs of sinuses (maxillary, frontal, ethmoidal, and sphenoidal) are partially enclosed cavities open to the nasal passages through small holes (ostea or meatus). The warm, moist sinus environment they create is speculated to aid olfaction, increase vocal resonance, reduce the bony weight of the skull, and protect intracranial structures from trauma(10). The ciliated epithelium, in coordination with mucus production, continually removes waste from the sinuses. However, when the ostea are blocked, drainage is impeded and pressure increases, causing pain. With reduced sinus drainage comes an increased risk of microbial overgrowth within the mucus layer and in sinus tissue(11).

The osteomeatal complex is differently defined by several authors. In the present study, the concept developed by Stammberger & Kennedy(12) was adopted, defining osteomeatal complex as a functional unit of the anterior ethmoid complex representing the final common pathway for drainage and ventilation of the frontal, maxillary and anterior ethmoid cells.

Standard radiography is inadequate for the clinical evaluation of sinusitis because it does not evaluate the anterior ethmoid air cells, the upper two thirds of the nasal cavity, or the infundibular, middle meatus, or frontal recess air passages(5). CT is the optimal radiographic study to assess the paranasal sinuses for evidence of disease. The mucosa of the normal, noninfected sinus approximates the bone so closely that it cannot be visualized on CT. Therefore,

any soft tissue seen within a sinus is abnormal(13). CT may demonstrate mucosal thickening, sclerosis, clouding, or air-fluid levels. Imaging must be performed in the coronal plane to adequately demonstrate the ethmoid complex. It can reveal the extent of mucosal disease in the osteomeatal complex. The test-retest reliability of CT in the assessment of chronic rhinosinusitis was high and stable in a prospective series of patients scheduled for endoscopic sinus surgery(14). The prevalence of reversible sinus abnormalities on CT in patients who have the common cold is high(15). This suggests that CT should be taken after subsidence of an acute episode if infection to exclude false positive cases.

The mucosa of the sinus approximates the bone so closely that it cannot be visualized on CT. Therefore, any soft tissue bulge seen in the sinus is abnormal(13). It has also been shown that mucosal thickening less than 4 mm in chronic rhinosinusitis is not normally of clinical importance, even though these patients may still have symptoms(8). Hence, in our study, we have taken CT scan with 4 mm or more mucosal thickening as positive for chronic rhinosinusitis.

Total Lund scores of 0 or 1 are unlikely to represent true chronic rhinosinusitis, whereas total Lund scores of 4 or greater are highly likely to represent true chronic rhinosinusitis. Lund scores of 2 to 3 are ambiguous, and further clinical evaluation or follow-up is warranted(16). In our study, we have included only those patients whose total Lund MacKay score was 4 or more.

In a similar study by K Dua et al., the anterior ethmoids and osteomeatal unit were the most commonly involved (88%). This was followed by posterior ethmoids, maxillary antra, frontal sinuses and the sphenoids which were minimally involved(17).

In our study, osteomeatal complex was the most common site to be affected (54%). Zinreich et al(6) found middle meatus opacification in 72% of the patients with chronic sinusitis, and, of these 65% had maxillary sinus mucoperiosteal sinus thickening. Yousem et al found that

when the middle meatus was opacified, the maxillary and ethmoid sinuses showed inflammatory changes in 84% and 82% respectively. Another study by the same group found frontal or maxillary sinus disease in 84% patients who had OMC opacification(18). Thus these findings support the contention that obstruction of the narrow drainage pathways will lead to subsequent sinus inflammation.

In our study, the incidence of sinus involvement was maxillary antrum (50%), anterior ethmoids (40%), posterior ethmoids (22%), frontal sinus (18%) and sphenoid sinus (13%) in descending order. Zinreich(19) published maxillary sinus involvement in 65%, posterior ethmoids in 40%, frontal in 34% and sphenoid sinus involvement in 29%. Bolger(20) reported maxillary sinus involvement in 77.7%, posterior ethmoids in 38.6%, frontal sinus in 36.6% and sphenoid sinus in 25.4%. Smith and Brindley(21) found maxillary sinus involvement in 55.5%, posterior ethmoids in 46.5%, frontal sinus disease in 30% and sphenoid sinus in 20%. Maru(22) reported maxillary sinus involvement in 70.4%, posterior ethmoids in 52.4%, frontal in 48.3% and sphenoids in 40.8%.

CONCLUSION:

Osteomeatal complex is the most common site to get involved in chronic rhinosinusitis. The blockade in the osteomeatal complex subsequently leads to impaired drainage and inflammation in maxillary, ethmoid, frontal and spheno-ethmoidal region. This study has re-emphasized the concept that Osteomeatal complex is the key factor in the causation of chronic sinusitis. Removal of disease in Osteomeatal complex region is the basic principle of Functional Endoscopic Sinus Surgery which is best appreciated on CT Scan.

REFERENCES:

1. Lanza DC, Kennedy DW. Adult rhinorhinosinusitis defined. *Otolaryngol Head Neck Surg* 1997; 117: p1-7.
2. Bhattacharyya N. The economic burden and symptom manifestations of chronic rhinorhinosinusitis. *Am J Rhinol* 2003; 17: 27-32.
3. Benninger MS, Anon J, Mabry RL. The medical management of rhinosinusitis 1997; 117:p41– 9.
4. Slavin RG. Nasal polyps and sinusitis. *JAMA* 1997; 278:1849–54.
5. Zinreich SJ. Paranasal sinus imaging. *Otolaryngol Head Neck Surg* 1990; 103:863–9.
6. Zinreich SJ, Kennedy DW, Rosenbaum AE, Gayler BW, Kumar AJ, Stammberger H. Paranasal sinuses: CT imaging requirements for endoscopic surgery. *Radiology* 1987; 163:769–75.
7. Stephen D. Silberstein. Headaches due to nasal and paranasal sinus disease. *Neurol Clin N Am* 2004; 22:1-19.
8. Rak KM, Newell JD, Yakes WF, Damiano MA, Iwethke JM (1991) Paranasal sinuses on MRI images of the brain: Significance of mucosal thickening. *Amer J Radiol* 156: 381-384.
9. Rubin MA, Gonzales R, Sande MA. Infections of the upper respiratory tract. In: Kasper DL, Braunbald E, Fuaci AS, et al, eds. *Harrison's Principles of Internal Medicine*. 16th ed. New York, NY: McGraw-Hill; 2005:p185-201.

10. Hallett R, Naguwa SM. Severe rhinosinusitis. *Clin Rev Allergy Immunol* 2003; 25:177-190.
11. Steve Helms, Alan L Miller. Natural treatment of chronic rhinosinusitis. *Alternative medicine review* 2006; 11(3): 196-207.
12. Stammberger HR, Kennedy DW. Paranasal sinuses: anatomic terminology and nomenclature. The Anatomic Terminology Group. *Ann Otol Rhinol Laryngol Suppl.* 1995; 167:7–16.
13. Schatz CJ, Becker TS. Normal CT anatomy of the paranasal sinuses. *Radiol Clin North Am* 1984; 22:107–18.
14. Bhattacharyya N. Test-retest reliability of computed tomography in the assessment of chronic rhinosinusitis. *Laryngoscope* 1999; 109:1055–8.
15. Gwaltney JM, Phillips CD, Miller RD, et al. Computed tomographic study of the common cold. *N Engl J Med* 1994; 330:25–30.
16. Bhattacharyya N, Fried MP. The accuracy of computed tomography in the diagnosis of chronic rhinosinusitis. *Laryngoscope* 2003; 113:125–9.
17. K Dua, H Chopra, A S Khurana, M Munjal. CT Scan Variations in Chronic Sinusitis. *Ind J Radiol Imag* 2005; 15(3):315-320.
18. Yousem DM. Imaging of the sinonasal inflammatory disease. *Radiology* 1993; 188: 303-314.

19. Zinreich SJ, Abidin M, Kennedy DW. Cross-sectional imaging of the nasal cavity and paranasal sinuses. *Oper Techniq Otolaryngol Head Neck Surg* 1990; 2: 94-98.
20. Bolger EW, Butzin CA, Parsons DS. Paranasal sinus bony anatomic variations and mucosal abnormalities -CT analysis for endoscopic sinus surgery. *Laryngoscope* 1991; 101: 56-64.
21. Smith LF, Brindley PC, Galveston H. Indications, evaluation, complications and results of functional endoscopic sinus surgery in 200 patients. *Otolaryngol-Head Neck Surg.* 1993; 108:688-696.
22. Maru YK, Gupta V. Anatomic variations of the bone in sinonasal CT. *Indian Journal of Otolaryngol and Head Neck Surgery* 2001; 53:123-128.

LEGEND TO TABLES

TABLE 1: CT SCAN DETECTION OF MUCOSAL ABNORMALITIES IN CHRONIC RHINOSINUSITIS

TABLE 2: LUND SCORING OF CHRONIC RHINOSINUSITIS

TABLE 1: CT SCAN DETECTION OF MUCOSAL ABNORMALITIES IN CHRONIC RHINOSINUSITIS

MUCOSAL ABNORMALITIES	UNILATERAL		BILATERAL		TOTAL	%age
	PATIENTS	%age	PATIENTS	%age		
OSTEOMEATAL COMPLEX	26	26	28	28	54	54
MAXILLARY ANTRA	22	22	28	28	50	50
ANTERIOR ETHMOIDS	21	21	19	19	40	40
POSTERIOR ETHMOIDS	7	7	15	15	22	22
FRONTAL SINUSES	10	10	08	08	18	18
SPHENOID SINUSES	08	08	05	05	13	13

TABLE 2: LUND SCORING OF CHRONIC RHINOSINUSITIS

SITE	LUND SCORE					
	0	%	1	%	2	%
MAXILLARY	48	48	34	34	18	18
ANTERIOR ETHMOIDS	60	60	19	19	21	21
POSTERIOR ETHMOIDS	78	78	14	14	8	8
FRONTAL	82	82	12	12	6	6
SPHENOID	87	87	10	10	03	03
OSTEOMEATAL COMPLEX	48	48			52	52

FIG 1: CT SCAN SHOWING CHRONIC BILATERAL PANSINUSITIS SECONDARY TO BILATERAL OSTEOMEATAL COMPLEX OBSTRUCTION

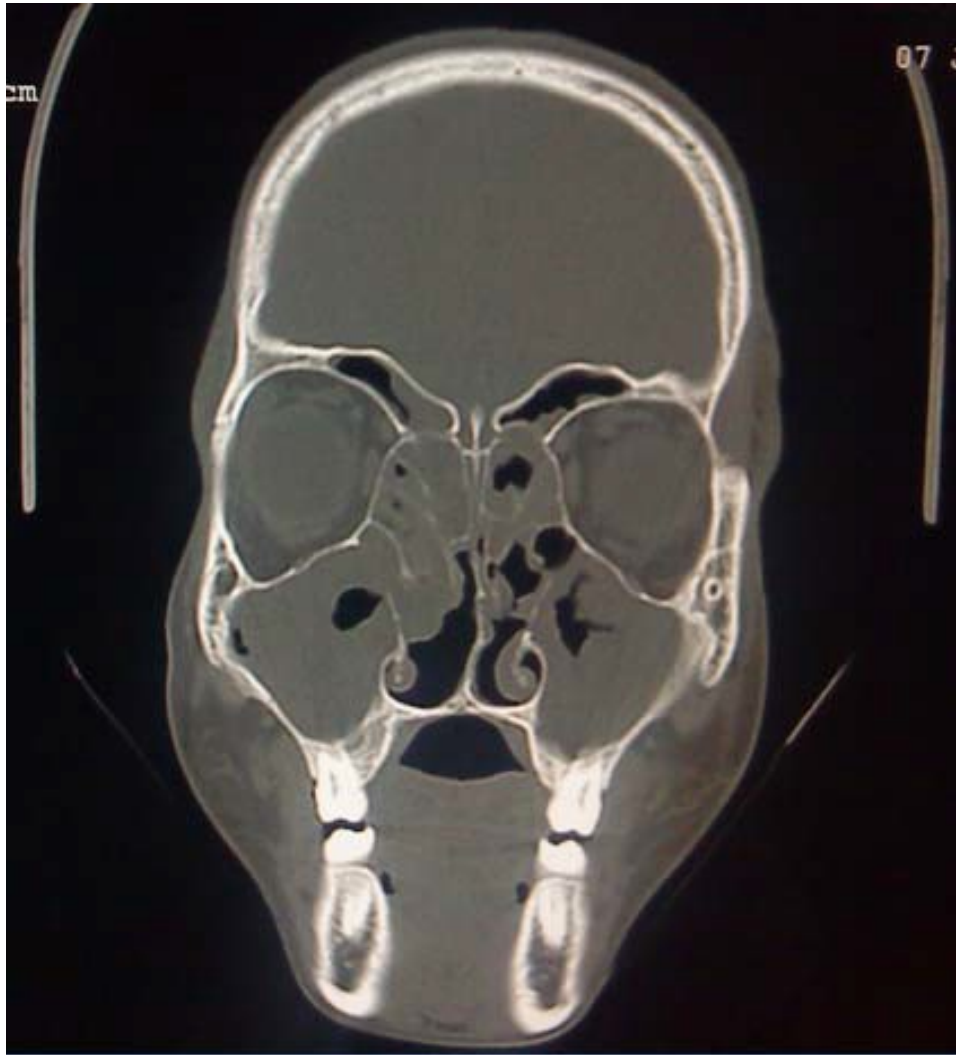


FIG 2: CT SCAN SHOWING BILATERAL MAXILLARY SINUSITIS SECONDARY TO BILATERAL OSTEOMEATAL COMPLEX BLOCKADE

