



Paediatric refractory rhinosinusitis secondary to hypertrophied adenoids: management and review of literature.

Goutham M K Ravishankara S Sudhir M Naik Sathya P Mohan Appaji Shankar Narayanan
Bhat Ravi Karumbiah Rudresh Hirmath

KVG Medical College Sullia Karnataka

Abstract:

Background /Objectives: Hypertrophied adenoids are the most common cause of refractory sinusitis in paediatric age. We study 42 cases of patients of chronic adenoiditis with adenoid facies and refractory chronic rhinosinusitis managed by endoscopic assisted adenoidectomy (EAA) and conventional adenoidectomy (CA).

Materials and method: 42 cases of chronic refractory sinusitis with adenoid facies secondary to hypertrophied adenoids were randomized into 2 groups during the study period of 12 months from August 2012 to July 2013. Group A (n=21) underwent endoscope assisted adenoidectomy and Group B(n=21) underwent conventional adenoidectomy.

Result: Endoscopic assisted adenoidectomy proves to be more effective in managing adenoid facies and chronic refractory rhinosinusitis with adenoid hyperplasia.

Conclusion: Visualization of the adenoid mass using endoscope helps complete removal of the diseased adenoids. Endoscopic assisted adenoidectomy is treatment of choice in adenoid facies and chronic refractory rhinosinusitis with adenoid hyperplasia and more effective than conventional adenoidectomy.

Key word 1: adenoidectomy

Key word 2: refractory rhinosinusitis.

Key word 3: mouth breathing.

Key word 4: adenoid facies.

Introduction:

Hypertrophied adenoid is to be suspected in refractory rhinosinusitis in paediatric age group. Adenoidectomy is the treatment of choice in such cases. It is a common procedure performed in the otolaryngological practice. It is a safe and effective procedure, regardless of the methods employed.¹ Many different instruments and techniques have been utilized throughout the history of the procedure. The procedure is performed to treat chronic adenoiditis which are not responding to medical line of treatment.¹ It is indicated in enlarged adenoids causing obstructive sleep apnoea, recurrent serous otitis media, chronic resistant rhinosinusitis, adenoid facies and chronic suppurative otitis media.^{1,2}

Visualizing the adenoids in the OPD is not possible in all children because the paediatric patient may not co-operate during postnasal mirror or endoscopic examination. Lateral radiographs of adenoids are routinely investigated before an adenoidectomy. We have previously used the adenoid curette technique transorally guided by digital palpation of the adenoids following soft palate retraction.

Several adenoidectomy methods have been well described in the literature. Adenoid curette guided by an indirect transoral mirror and a headlight is a simple and quick procedure that has already been in use for a long time. Endoscopic assisted adenoidectomy has more advantages than blind palpation and curettage and indirect transoral mirror assisted curettage. Recently a curved suction electrical coagulator and the curved microdebrider shaver guided by nasal endoscope have successfully been used.

Nasal endoscopy allows easy size assessment of the adenoid and improves the accuracy of the adenoidectomy via a transoral curette. This method is particularly important for younger paediatric patients with smaller oral cavities, because the size assessment of the adenoids by conventional palpation and mirror examination is challenging and the placement of the adenoid curette guided by the indirect mirror is difficult.

Materials and Methods:

This is a prospective randomized study of 42 cases of chronic refractory rhinosinusitis managed in our medical college hospital between August 2012 to July 2013. The patients were randomized into 2 groups. Group A (n=21) underwent endoscope assisted adenoidectomy (EAA) and Group B (n=21) underwent conventional adenoidectomy (CA). Routine investigations were done in all the patients. X-ray of the neck and the nasopharynx lateral view was taken. Post-nasal examination could be done in only 14 patients. X-ray lateral view showed adenoid mass in all cases.

All the patients underwent adenoidectomy under general anaesthesia with orotracheal intubation with South Pole tube. 37 patients underwent tonsillectomy in the same setting. In Group A (n=21), the nose was decongested by ribbon gauze soaked with 0.05% oxymetazoline solution inserted for 5 minutes. Patient is positioned supine with neck in extension. A Boyle- Davis mouth gag was inserted to open the mouth widely. The surgeon stood on the side of the table and the nasal cavities and nasopharynx was examined with a zero-degree 2.7 mm nasal endoscope (fig 1). The soft palate was pulled anteriorly using an infant feeding tube. A suitably sized St Clair Thompson's adenoid curette was passed transorally into the nasopharynx. Under nasal endoscopic guidance, the blade of the adenoid curette was placed just above the superior border of the adenoid (fig 2). The lateral ends of the blade should just be away from the Eustachian tube area on both sides. The adenoid was curetted with a sustained force as in conventional curettage and complete clearance of tissue was achieved (fig 3). Transoral packing gauze was used for 3 to 5 minutes to control any bleeding. In cases where adenotonsillectomy were performed, adenoidectomy was performed first. This is to avoid fogging of the endoscope with bleeding from tonsillectomy site. In Group B (n=21), patients underwent conventional adenoidectomy in Rose's position. Post operative follow up was done for 6-12 months.

Result: There were 24 (57.2%) males and 18 (42.8%) females in the study. Of the 42 cases, 19 (45.23%) had features of adenoid facies. Mouth breathing and bad oral hygiene were seen in all cases. Hyponasal voice and snoring was seen in 28 (46.66%) patients. 12 (28.5%) patients complained of abnormal upper dentition. 9 (21.4%) patients had bilateral chronic suppurative otitis media and 5 (11.9%) had unilateral chronic suppurative otitis media. 37 (88%) patients had chronic tonsillitis along with adenoiditis.

Group A had 13 (61.9%) males & 8 (38.1%) females. Group B had 11 (52.4%) males & 10 (47.6%) females. The mean age in Group A was 8.25 ± 2.25 years & in Group B was 7.75 ± 2.50 years. The mean operative time was more in Group A compared to Group B which was statistically significant ($p < 0.05$). There was no significant difference ($p > 0.05$) in intra operative blood loss in both groups. The accuracy and completeness (depth) of removal were significantly ($p < 0.05$) higher in endoscopic method (Group A- 90.5%, Group B 47.6%). The post operative pain showed similar values in both groups. There were no significant complications in both groups (table 1).

Surgeon satisfaction & symptomatic relief was also better in EAA. Symptoms of mouth breathing the attacks of URTI decreased drastically. All cases that had chronic suppurative otitis media did not have any future episodes of discharging ears. Mouth breathing and snoring subsided in all patients.

Discussion:

Adenoidectomy is one of the most commonly performed pediatric procedures in the otolaryngology.¹ The indications for surgery being obstructive sleep apnea and chronic adenotonsillitis with refractory chronic rhinosinusitis.² The other indications being chronic otitis media (often combined with bilateral myringotomy and grommet) and adenoid facies.³

Rhinosinusitis continues to be a prominent problem in pediatric population with most patients failing conservative medical management.³ Adenoidectomy has shown improvement in chronic rhinosinusitis symptoms such as rhinorrhoea, cough, post-nasal drip and halitosis.⁵ In the pediatric population, adenoid hyperplasia is associated with nasal obstruction, rhinosinusitis, obstructive sleep apnea, and recurrent otitis media.^{6,7,8} The beneficial effects of adenoidectomy in decreasing the number and duration of episodes of otitis media have been well established in randomized trials.^{9,10} Similarly a significant decrease in the number of episodes of pediatric rhinosinusitis after adenoidectomy has been described.¹¹

Adenoidectomy may benefit the middle ear by removing a source of infection from the nasopharynx and has been shown to be helpful in children over 4 years of age with chronic otitis media with effusion.^{10,12,13} In contrast, the evidence of the efficacy of adenoidectomy in preventing recurrent episodes of acute otitis media is conflicting.¹¹ Chronic nasal obstruction and mouth breathing lead to characteristic facial appearance called adenoid facies.¹² Features of adenoid facies include an elongated face with dull expression, open mouth, prominent and crowded upper teeth and hitched up upper lip.¹³ Nose gives a pinched –in appearance due to disuse atrophy of alae nasi.¹⁴ Hard palate in these cases is highly arched as moulding action of the tongue on the palate is lost.¹⁴

The results of this analysis strongly suggest that adenoidectomy should be considered as first line therapy for medically refractory pediatric rhinosinusitis.⁵ It is a simple, low risk procedure that can easily be performed on an daycare basis with minimal required post-operative follow-up visits.⁵ The current clinical indicators for adenoidectomy as recommended by the AAO-HNS in 2000 are: a) 4 or more episodes of recurrent purulent rhinorrhoea in prior 12 months in a child <12. One episode documented by intranasal examination or diagnostic imaging. (b) Persisting symptoms of adenoiditis after 2 courses of antibiotic therapy. One course of antibiotics should be with a beta-lactamase stable antibiotic for at least 2 weeks. (c) Sleep disturbance with nasal airway obstruction persisting for at least 3 months. (d) Hyponasal or nasal speech. (e) Otitis media with effusion >3 months or second set of tubes (f) Dental malocclusion or orofacial growth disturbance documented by orthodontist. (g) Cardiopulmonary complications including cor pulmonale, pulmonary hypertension, right ventricular hypertrophy associated with upper airway obstruction. (h) Otitis media with effusion over age 4.²

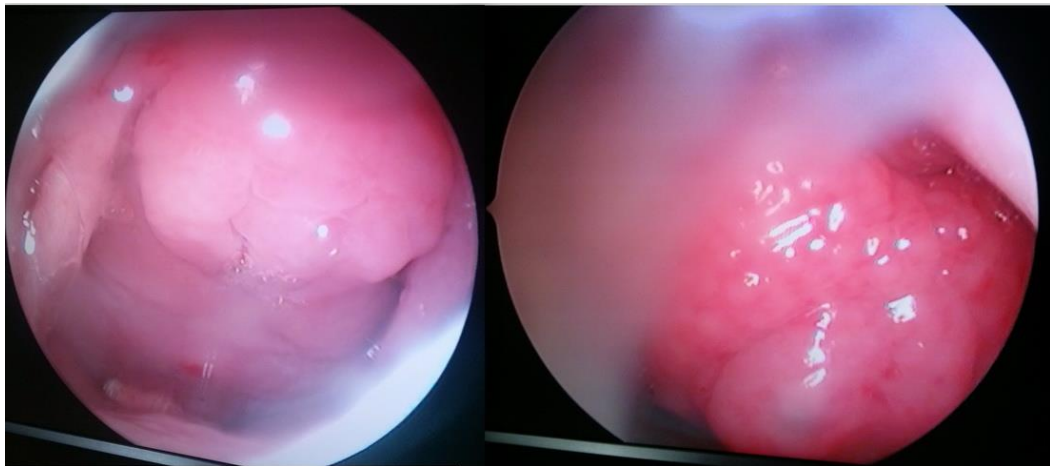
CA results residual tissue in the posterior superior choanae of the nose and nasopharynx.¹⁵ The problems of residual tissue remaining can be solved by the use of a nasal endoscope, which allows accurate placement of the adenoid curette at the superior border of the adenoids.¹⁵ This positioning allows the complete transoral removal of the main bulk of the adenoid under vision and also removal of the lateral tissue of the adenoids without damaging the eustachian tube prominence.¹⁵ The duration of surgery in endoscopic assisted methods is marginally more.^{15,18} The duration of procedure is noted to reduce with experience. The EAA technique is minimally invasive, adds less than 5- 10 minutes to the procedure, and is not associated with excessive bleeding.¹⁵

Recurrence of symptoms after adenoidectomy are most probably due to regrowth of residual lymphoid tissues left as a result of blind removal with conventional technique.¹⁵ Also it is reported in

literature that adenoids rarely regrow after adenoidectomy to cause nasal obstruction.¹⁷ None of the patients operated by endoscopic assisted adenoidectomy came with recurrence of the adenoid tissue over a period of 6-12 months. Endoscopic assisted adenoidectomy should be considered first line management of chronic refractory pediatric rhinosinusitis and chronic adenoiditis with mouth breathing and snoring. It is also surgical method of choice for treatment of adenoid facies.

Conclusion:

Endoscopic assisted technique allows more complete removal of adenoid tissue without a significant increase in the operative time, blood loss or association with any postoperative complications. Endoscopic assisted adenoidectomy is an adjunct to performing a more complete adenoidectomy, thereby reducing the chances of developing recurrent adenoid obstructive symptoms and reducing the bacterial reservoir in the nasopharynx. The procedure costs are nearly equal as the endoscope is readily available in operation theatres.



View of adenoids during nasal endoscopy

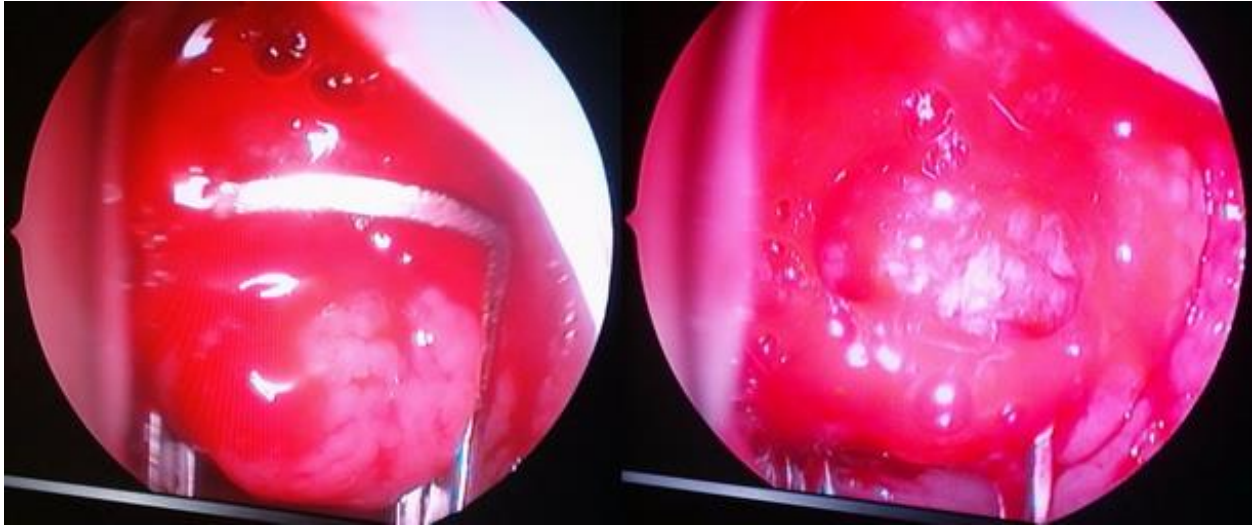
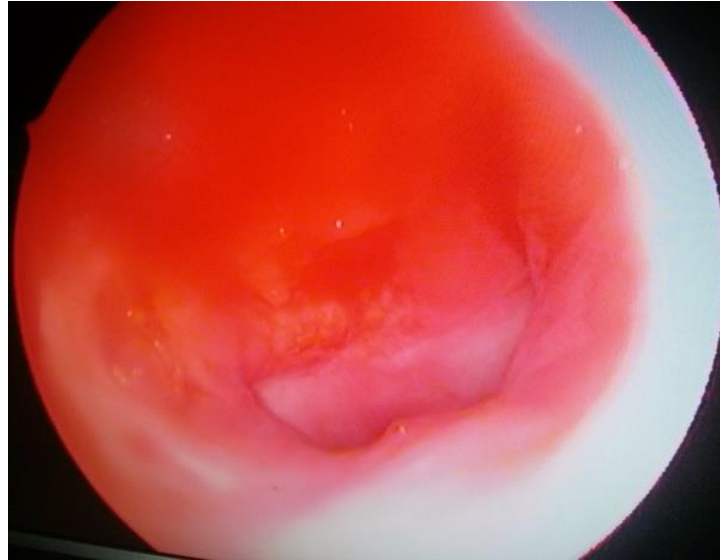


Figure showing adenoid being curetted



Picture showing nasopharynx after complete removal of adenoid

References:

1. Renuka A Bradoo, Rahul R Modi, Anagha A Joshi, vikas Wahane. Comparison of endoscopic assisted adenoidectomy with conventional method. *An International journal. Clinical rhinology*. 2011; 4(2): 75-8.
2. Khalid Al-Abdulhadi, Rihab Al-Wotayan, Pooja Chodankar: Common throat infections: a review: *Bulletin of the Kuwait Institute for Medical Specialization*. 2007; 6: 63-67.
3. Scott E. Brietzke, Matthew T. Brigger. Adenoidectomy outcomes in pediatric rhinosinusitis: A meta-analysis. *International Journal of Pediatric Otorhinolaryngology*. 2008; 72: 1541-45.
4. C. Poje, L. Brodsky, Tonsillitis, Tonsillectomy, Adenoidectomy. *Head and Neck Surgery-Otolaryngology*. 3rd ed. 2001; 81:979-1006.
5. T. Watanabe, T. Fujiyoshi, K. Tomonaga, Mogi G. Adenoids and otitis media with effusion in children. *Adv Otorhinolaryngol*.1992; 47: 290-6.
6. J.M. Bernstein, H.F. Faden, D.M. Dryja, Wactawski-Wende J. Micro-ecology of the nasopharyngeal bacterial flora in otitis-prone and non-otitis prone children. *ActaOtolaryngol*. 1993; 113(1) 88-92.
7. J.L. Paradise, C.D. Bluestone, D.K. Colborn, BS Bernard, CG Smith, HE Rockette , M Kurs-Lasky. Adenoidectomy and adenotonsillectomy for recurrent acute otitis media: parallel randomized clinical trials in children not previously treated with tympanostomy tubes. *JAMA*.1999; 282(10): 945-53.
8. G.A. Gates, C.A. Avery, T.J. Prihoda, J.C. Cooper Jr. Effectiveness of adenoidectomy and tympanostomy tubes in the treatment of otitis media with effusion. *N Engl J Med*. 1987; 317(23): 1444-51.
9. J.L. Paradise, C.D. Bluestone, K.D. Rogers. Efficacy of adenoidectomy for recurrent otitis media in children previously treated with tympanostomy tube placement.1990; *JAMA*. 263(15): 2066-73.
10. Sade J, Luntz M. Adenoidectomy in otitis media—a review. *Ann OtolRhinolLaryngol* 1991;100: 226-31.
11. Maw AR, Herod F. Otoloscopic, impedance and audiometric findings in glue ear treated by adenoidectomy and tonsillectomy. *Lancet*. 1986; 1(8495):1399-402.
12. Ravindhra G. Elluru . Adenoid Facies and Nasal Airway Obstruction. *Arch Otolaryngol Head Neck Surg*. 2005; 131(10): 919-20.
13. Cannon CR, Replogle WH, Schenk MP. Endoscopic – assisted adenoidectomy. *Otolaryngol Head Neck surg*. 1999; 121(6): 740-4.
14. K. S. Emerick and M. J. Cunningham. Tubal tonsil hypertrophy: a cause of recurrent symptoms after adenoidectomy. *Archives of Otolaryngology—Head and Neck Surgery*. 2006; 132(2):153-6.
15. F J Buchinsky, MA Lowry and G Isaacson. Do adenoids regrow after excision? *Otolaryngol Head Neck Surg*. 2000; 123(5): 576-81.
16. Amr El-Badrawy and Mosaad Abdel-Aziz. Transoral Endoscopic Adenoidectomy. *International Journal of Otolaryngology*.2009;Article ID 949315, 4 pages doi:10.1155/2009/949315
17. Koltai PJ, Kalathia AS, Stanislaw P & Heras HA (1997). Power-assisted adenoidectomy. *Arch Otolaryngol Head Neck Surg*.1997; 123(7): 685-8.
18. R Datta, VP Singh, Deshpal. Conventional Versus Endoscopic Powered Adenoidectomy: A Comparative Study. *MJAFI*. 2009; 65 :308-312
19. Feng Y, Yin S .Comparison of the powered-assisted adenoidectomy with adenoid curette adenoidectomy. *Lin Chuang Er Bi Yan Hou Ke Za Zhi*.2006; 20(2):54-7.

20. Ezzat WF. Role of endoscopic nasal examination in reduction of nasopharyngeal adenoid recurrence rates. *Int J Pediatr Otorhinolaryngol.* 2010 Apr; 74(4):404-6. doi: 10.1016/j.ijporl.2010.01.016. Epub 2010 Feb 16.
21. Prakash NS, Mallikarjunappa AM, Habie Thomas Samuel. Endoscopic assisted adenoidectomy versus conventional curettage adenoidectomy- a comparative study. *National Journal of Otorhinolaryngology and Head & Neck Surgery.*2013; Vol. 1(10) No. 2: 10-12
22. S S Somani, CS Naik, S V Bangad. Endoscopic Adenoidectomy with Microdebrider. *Indian J Otolaryngol Head Neck Surg.* 2010; 62(4):427–431; DOI 10.1007/s12070-011-0118
23. Ihsan Allawi Hussein Saad AL-Juboori. Conventional Versus Endoscopic-Assisted Adenoidectomy: A Comparative Study. *Medical Journal of Babylon.*2012; 9(3): 570-82