



Volume 2 No 1 2012

Maxillary sinus antrostomy Pitfalls

Dr T Balasubramanian

Abstract:

Endoscopic sinus surgery which is the commonly performed nasal surgery has its own problems if not performed properly. Success of maxillary sinus antrostomy depends on including the natural ostium to the antrostomy. For this to happen the natural ostium should be identified during the surgical procedure. Common cause of failure in endoscopic sinus surgery is the failure to address the uncinate process. In all cases it should be removed completely before proceeding further.

Introduction:

The concept of middle meatal antrostomy was based on the path breaking research by Stamberger who demonstrated that mucociliary clearance mechanism¹ ensured that mucosal drainage from maxillary sinus antrum occurred via its natural ostium. Endoscopic middle meatal antrostomy happens to be the commonly performed² sinus surgery these days. This apparently simple surgical procedure is not that simple and failure to perform a proper maxillary sinus antrostomy is the frequent cause of failures in endoscopic sinus surgery. Incomplete removal of uncinate process has been cited to be the commonest cause for surgical failures³. The absence of reliable landmarks for identification of natural ostium of maxillary sinus makes this procedure difficult. Ethmoidal sinus / sphenoid sinuses have reliable surgical landmarks in the form of skull base and lamina papyracea⁴.

Factors responsible for Failure:

1. Incomplete removal of uncinate process
2. Failure to include natural ostium into the antrostomy
3. Involvement of uncinate process in the inflammatory pathology

Failure to include natural ostium into the antrostomy will lead to recirculation of mucous between the natural ostium and the maxillary sinus antrostomy performed.

It is the involvement of uncinete process in the disease process that causes failure of Balloon sinuplasty in these patients¹.

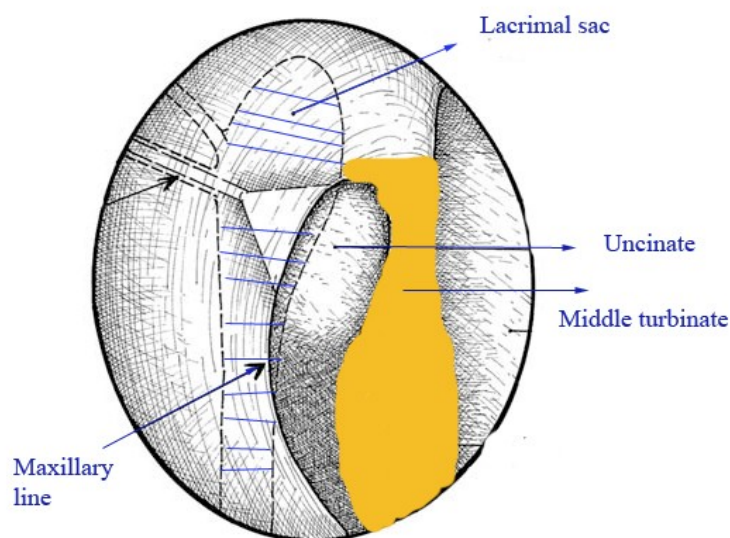
Complete uncinectomy should ideally be performed in these patients. This will ensure not only adequate sized maxillary sinus antrostomy is performed but will also help in including the natural ostium with the antrostomy.

Anatomically uncinete process is attached to the bony covering of nasolacrimal duct. Bony covering over nasolacrimal duct is very dense. This change in the bony thickness between the uncinete process and the nasolacrimal duct ensures that a complete uncinectomy can be performed with minimal trauma to naso lacrimal duct if this anatomical fact is kept in view. According to Bolger a certain amount of minimal trauma occurs commonly during uncinectomy.

Landmark for uncinete process:

The maxillary line is considered to be an ideal surgical landmark if sickle knife is used to excise the uncinete process from its anterior attachment. Maxillary line is a mucosal prominence arising from the anterior attachment of middle turbinate along the lateral nasal wall vertically up to the upper border of inferior turbinate¹. This line approximates with that of the junction between uncinete process and maxilla. Uncinete process is usually incised behind this line.

After complete uncinectomy the natural ostium could be seen just under the inferior edge of the cut uncinete process. 30° telescope can be used at this juncture to identify the natural ostium of maxillary sinus. In patients with anteriorly placed natural ostium a ball probe can be used to gently probe the posterior fontanelle area. This would cause air bubble to arise from the natural ostium thus enabling its identification.



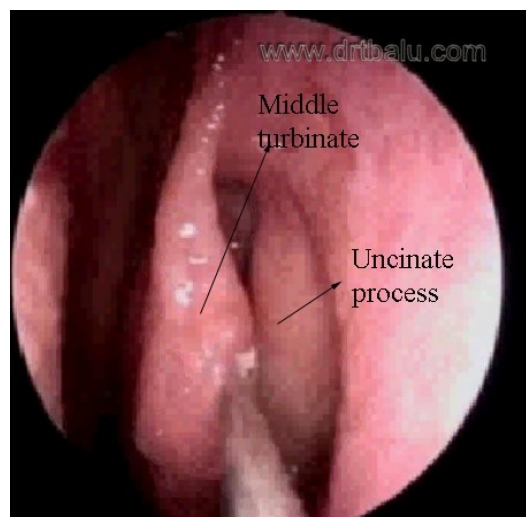
Diagrammatic representation of maxillary line and its relationships⁵

While performing endoscopic sinus surgery it is important to differentiate natural ostium from accessory ostium⁶.

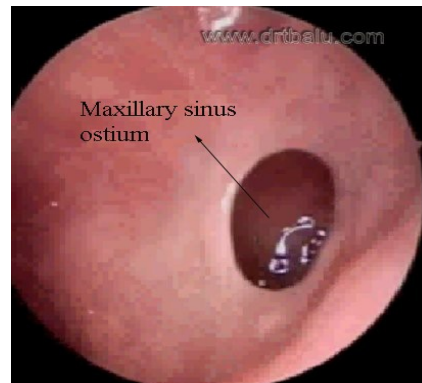
Presence of infraorbital cell (Haller) will cause inferior displacement of natural ostium making it difficult to identify during routine endoscopic sinus surgery procedures.

Difference between natural and accessory ostium

Natural ostium	Accessory ostium
Present anteriorly not visible under routine direct nasal endoscopic examination	Present posteriorly and can be easily visualized during routine nasal endoscopic examination
Oval in shape	Spherical in shape
Oriented transversely	Oriented anteroposteriorly



Picture showing endoscopic view of uncinate process



Picture showing natural ostium oriented transversely

Conclusion:

Osteitic reaction that takes place in the uncinat process leads to narrowing of natural ostium of maxillary sinus. Hence it is prudent to remove the entire uncinat process while performing endoscopic sinus surgery.

References:

1. Kennedy DW, Zinreich SJ, Shaalan H, Kuhn F, Naclerio R, Loch E. Endoscopic middle meatal antrostomy: theory, technique, and patency. *Laryngoscope* 1987;97(8 Pt 3 Suppl 43):1-9.
2. Endoscopic sinus surgery in Geriatric patients Rong-sang Jiang *ENT Journal* April 2001
3. <http://www.drtdbalu.com/fess.html>
4. Endoscopic Maxillary Antrostomy: Not Just A Simple Procedure David Kennedy etal *The Laryngoscope* CV 2011 The American Laryngological, Rhinological and Otological Society, Inc.
5. http://www.drtdbalu.com/Endo_dcr.html
6. <http://www.drtdbalu.co.in/dne.html>