

Low intensity pulsed ultrasound (Lipus) as a non-surgical cost effective method of managing atrophic non-union.

Samena Chaudhry^{1*}, Rohan Rajan², Sarah Rubin³, Yvonne Mary Papamerkouriou⁴

¹Department of Paediatric Orthopaedics, Royal Derby Hospital, Uttoxeter Road, Derby, UK

²Consultant Orthopaedic Surgeon, Lead Clinician in Paediatric Orthopaedics, Royal Derby Hospital, University of Derby, Uttoxeter Road, Derby DE22 3NE

³East Midlands Deanery Queens Medical Centre, Derby Road, Nottingham, UK

⁴Department of Paediatric Orthopaedics, Karamandaneio Childrens Hospital, Patras, Greece

Abstract

Introduction: Non-unions are difficult to treat and have a high financial impact. Low intensity pulsed ultrasound (LIPUS) is one method of enhancing healing in non unions without the risks and complications of a surgical procedure. Our aim was to review the outcomes of LIPUS use in a group of patients with atrophic non union.

Methods: Patients diagnosed with atrophic non union during the recruitment period were prospectively followed up for up to 2 years with clinical and radiological assessments. Union was diagnosed when the patient was pain free on clinical examination and cortices demonstrated bony bridging with no pain.

Results: Of the 15 patients (10 female, 5 male) reviewed, mean time of non union prior to treatment was 12.7 months. 1 patient was lost to follow up. Union in 93% of patients occurred within 6 months. Compliance with use of the device was 80%. 1 patient did not achieve healing of a mid shaft humeral fracture at 2 years but remained pain free.

Discussion: Our results highlight the important role LIPUS may have in patients with atrophic non union, especially for patients deemed unsuitable to undergo complex surgical procedures.

Keywords: Non union, Atrophic, Low Intensity pulsed ultrasound (Lipus).

Accepted on March 08, 2019

Introduction

A fracture without any expectation of spontaneous healing can be defined as a non union and occurs in 5-10 percent of patients [1]. Non unions are often found in association with unstable fractures, vascular insufficiency, infection and other patient factors including smoking, advanced age, malnutrition, medications and other comorbidities e.g.: diabetes [1,2].

When an osteogenic environment and adequate stability is provided, a nonunion can unite. But such conditions are generally achieved by operative means, including some form of bone fixation to provide adequate stability, decortication of bone ends, and application of bone graft material to enhance healing capacity. Surgery for established non-unions is technically difficult especially in more challenging situations e.g., leg length discrepancy, malalignment or gross instability and carries risk of complications. The very patients who often struggle with a non union may also be at high risk of failing the surgical procedure proposed [3,4].

One method found to enhance bone healing in non unions is low intensity pulsed ultrasound (LIPUS) [5,6]. Other non invasive treatment options include extra-corporeal shock wave therapy, electrical and pulsed electromagnetic fields (PEMF) [7-9].

LIPUS waves cause nano-motion at the fracture site. The mechanical signal is converted to a biochemical signal inside

the cells and is ultimately transmitted through signaling molecules to drive cyclo-oxygenase 2 (COX2) production in the cell. This cascade involves integrins and the formation of focal adhesions. Prostaglandin E2 (PGE2) production increases COX2 stimulation which then results in the expression of osteogenic genes [3-5].

LIPUS has been shown to enhance bone repair processes through many mechanisms, including stimulating calcification, and increasing the activity of osteoclast with enhanced endochondral ossification [6]. LIPUS has also been shown to increase key growth factors involved in the process of angiogenesis at the fracture site e.g., Vascular endothelial growth factor-A levels in osteoblasts. Production of fibroblast growth factor and interleukin-8 in osteoblasts is also increased [10,11].

All LIPUS systems use a transducer to deliver LIPUS over the fracture site for 20 mins every 24 hours.

The EXOGEN ultrasound bone healing system by Bioventus delivers low-intensity pulsed ultrasound waves and is licensed for healing non-union fractures and accelerating the time to healing of fresh fractures [12,13].

It is claimed to promote bone healing by stimulating the removal of old bone, increasing the production of new bone and increasing the rate at which fibrous matrix at a fracture site is converted to mineralised bone [14].

LIPUS has been calculated to be less expensive than having surgery for a non union. Kanakaris et al. [15] found in their systematic review that in the “best case scenario” it cost £15566, £17200 and £16330 for humeral, femoral, and tibial non-unions. Compared to this, EXOGEN™ 4000+ for non-uniting fractures costs £2562.50 for 191 × 20 minute treatments [15].

Despite the methodological limitations, there are many studies demonstrating statistical improvement in fracture union time to support LIPUS in non union. The UK’s National Institute for Health and Clinical Excellence (NICE) published guidance in 2010 and concluded that this procedure can improve fracture healing rates in delayed or non unions [16].

A change in the perception of LIPUS therapy followed the publication of a large multicenter, blind, placebo-controlled randomised trial in which 501 reamed and nailed tibial fractures treated with LIPUS showed no effect [17].

The study was published in the BMJ together with an editorial explaining there was no role for LIPUS and a strong recommendation against its use in any fractures as it had no impact on time to return to work, time to full weight bearing, pain, the number of subsequent operations, or time to radiographic healing [18].

However, despite the robust design of the trial, a major criticism has been the low compliance (43%) as this significantly under powers the study. Moreover, the patient cohort was a young population with fresh fractures already having undergone previous surgical treatment.

Following the publication of this trial and associated systematic review with the rapid clinical recommendation advising against it’s usefulness in fracture management, one might foresee a change in practice and even reluctance to using LIPUS in patients who might benefit from this therapy especially in cases of non union. Our aim was to review the outcomes of LIPUS in the management of atrophic non unions at The Royal Derby hospital.

Methods

The Exogen 250 produced by Bioventus was used in this study. This system emits low-frequency ultrasound at 1.5 MHz with a 1 kHz repetition module. The LIPUS delivery device records patient compliance with therapy. The permanently connected transducer is secured directly over the fracture site by applying coupling gel to the transducer head and it over the fracture site by a fixture on a strap. If the patient’s limb is immobilised in a cast, a hole is cut to allow access of the transducer to the skin. The device is programmed to deliver ultrasound in 20-minute sessions which the patient can self administer at home (Figure 1).

The patients were recruited over an 8 month period in 2016. Patients aged over 18 were selected if a diagnosis of atrophic non-union had been established. This was confirmed both clinically and radiologically and confirmed independently by four consultant orthopaedic surgeons. Patients who had undergone previous surgery or had other co-morbidities were not excluded. Patients were re-assessed clinically and radiologically (with a

combination of plain radiographs and/or computer tomography) for evidence of union during and after LIPUS therapy for up to 1 year. Unions on X-ray were assessed by the number of cortices bridged by callus. More than 3 cortices bridged by callus and loss of a fracture line as well as clinical examination were used to confirm fracture union. All cases were atrophic non-unions.

Results

There were 15 patients (10 female 5 male) with a mean age of 47 (range 24-77 years). 1 patient was lost to long term follow up. 2 patients had significant co-morbidities including diabetes, Charcot’s disease, sarcoidosis and osteoporosis and 2 had previous osteomyelitis at the treatment site.

All patients except one went on to achieve union. The mean duration of non union prior to Exogen therapy was 12.68 months and mean time to union with Exogen therapy 4.7 months. Smoking status was not reliably recorded. Compliance with the LIPUS device use was recorded at >90%.

Our results in Figures 2 and 3 demonstrate a variety in fracture types, fracture stabilisation methods and patient risk factors for non-union. The mean non-union duration was non-union 12.7 months prior to recruitment. The mean time to union with LIPUS was 4.7 months (Figure 4).

One patient who did not achieve union had a midshaft humeral non-union of 2 years duration following an open reduction and

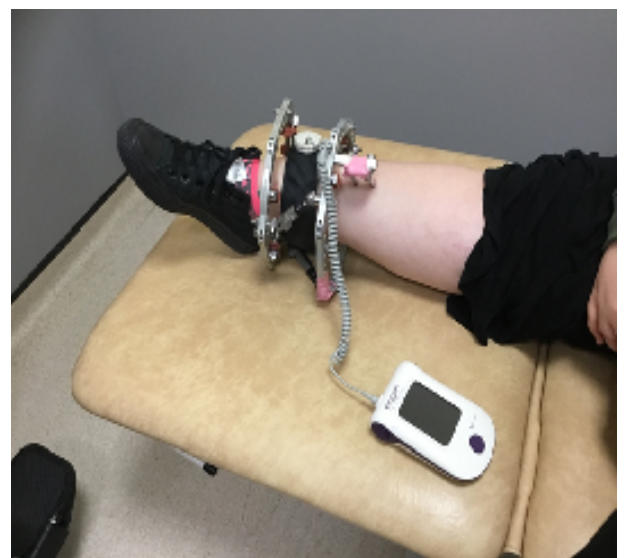

Figure 1. The LIPUS device applied to the lower leg.

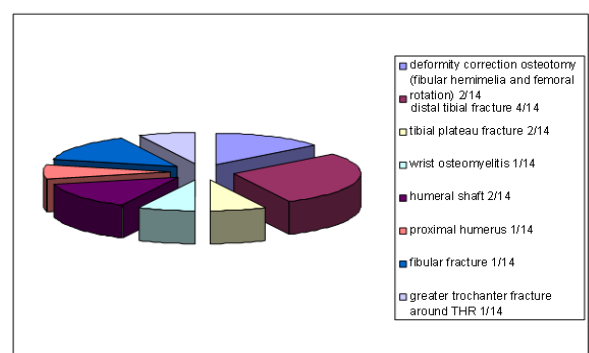


Figure 2. Fracture location.

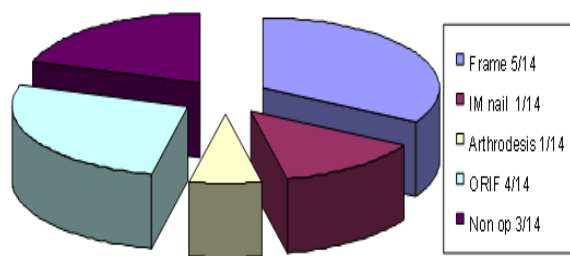


Figure 3. Fracture management.

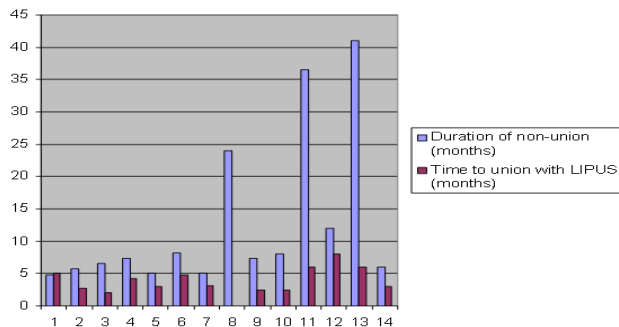


Figure 4. Time to union.

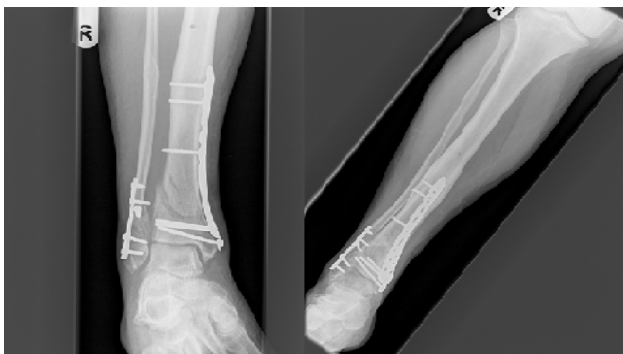

Figure 5. X-rays pre and post LIPUS.

internal fixation (Figure 5). As she had no pain or symptoms, no further treatment was required.

Discussion

Many systematic reviews have assessed the effect of LIPUS on bone healing in non unions. They all state that most of the trials are at high risk of bias, high loss to follow up, lack of blinding and potential publication bias. Hardly any have reported on patient specific outcomes such as quality of life.

The meta-analysis by Seger et al. [19] included 5 studies focused on scaphoid non unions and analysed healing index and average time to union. Type of non union was not recorded but 78.6% of 166 cases were reported to show healing following LIPUS, with an average time to union of 4.2 months [19].

The review by Leighton et al. [3] examining 1441 non unions included 13 studies, one of which was a randomised control trial [20]. The quality of the studies was assessed using the Methodological Index for Non- Randomised Studies. Interestingly, despite excluding poor quality studies, a heal rate of 80% was still found. Their results suggest that nonunions presenting within 3 to 6 months of fracture are candidates for LIPUS treatment.

This review also found that the chances of healing were twice as large in hypertrophic non-unions compared with atrophic non-unions when a subgroup of 8 studies with a total of 542 patients were examined and more successful when ultrasound was applied 3-6 months after the last revision surgery of in patients with a nonunion.

Roussignol published an 88% success rate LIPUS treatment in patients with tibial or femoral non union where 51/58 of the cases were atrophic type non unions [21]. Schofer et al. [22] reported on a multicenter, randomised double blind trial of LIPUS in 101 patients with delayed union of the tibia. Patients were randomised to LIPUS (n=51) or to an inactive sham device (n=50), to be administered 20 minutes a day for 16 weeks. The intention- to- treat analysis showed that LIPUS improved mean bone mineral density by 34% compared with sham treatment but type of non union was not recorded. 65% of patients in the LIPUS group versus 46% of the patients in the sham group healed (p=0.07). Rutten et al. [23] reported on a blinded RCT evaluating 20 subjects with tibial fracture nonunion and found a statistically significant reduction in time to radiographic healing. 54/71 patients had an atrophic non union. However, the 45% loss to follow-up rate raised some concerns about potential bias of these findings.

Ricardo et al. [24] published a blinded RCT evaluating 21 subjects with scaphoid nonunion and found a statistically significant reduction in time to radiographic healing (-40.4%; 95% CI, 48.7% to -30.8%) with LIPUS.

Biglari et al. [25] conducted a prospective, single- institution, observational study on 61 non-unions in long bones of the lower extremity treated with LIPUS. 39.3% were hypertrophic. Only a small number of patients with nonunions who underwent LIPUS therapy experienced successful treatment (32.8%).

The authors state that their patient group included a large number of difficult non unions many of whom had at least three different operations before trying LIPUS. A potential explanation for their results.

However, the systematic review which is felt to provide the most recent robust analysis of the existing evidence especially for fresh fractures did not find any supporting statistically significant differences to support LIPUS. They included 26 RCTs that used low-intensity pulsed ultrasound (LIPUS) [26].

Data from the TRUST trial comprised greater than one-third of the total number of included patients across the studies analysed. However not only could they not assess the effectiveness of LIPUS on non union rates in the TRUST trial as most fractures had healed. 3 of the trials included had patients with nonunion. Those studies were also found to be at high risk of bias.

The BMJ Rapid Recommendation from 2017 stated “There was high quality evidence showing a lack of benefit in accelerating healing for fresh fractures; thus it is unlikely that LIPUS would improve outcomes in patients with non-union” [18].

However, the role of LIPUS in preventing nonunions in fractures and as treatment of non unions known to have high nonunion rates or on treating established nonunions were not looked into. Better quality studies looking at those patient groups specifically are required.

93% of patients went on to achieve union in our study. This compares with other published studies with larger cohorts of patients where success rates were found to be lower. In our experience, even non-unions of an extremely long duration in the region of (3.5 years) united with the use of LIPUS within 6 months.

Our data selection was small with a large variation in both the patient factors and fracture personalities with probable high heterogeneity. However, despite the various reviews of studies for patients undergoing LIPUS therapy this study highlights the potential role for LIPUS in atrophic non union -an area which only a few small studies have looked into [27].

Conclusion

Our results demonstrate that LIPUS treatment can be an alternative to surgery for established atrophic nonunion. Given that spontaneous healing of established atrophic nonunions is not expected, LIPUS may be most useful in patients for whom surgery is high risk and (as other studies have suggested), particularly in those groups of patients, including elderly patients at risk of delirium, dementia, extensive soft-tissue trauma, mechanical ventilation, metabolic acidosis, and multiple organ failure, or coma. With an overall average success rate for LIPUS > 90% this compares extremely well, to the success of surgical treatment of non unions.

Acknowledgement

We would like to thank Bioventus for their assistance and support in this work.

References

1. Buza JA, Einhorn T. Bone healing. *Clin Cases Miner Bone Metab.* 2016;13(2):101-5.
2. Bhandari M, Fong K, Sprague S, et al. Variability in the definition and perceived causes of delayed unions and non-unions. *J Bone Joint Surg Am.* 2012;94(15):1091-6.
3. Leighton R, Watson T, Giannoudis P, et al. Healing of fracture non-unions treated with low-intensity pulsed ultrasound (LIPUS): A systematic review and meta-analysis. *Injury Int J Care Injured.* 2017;48:1339-47.
4. Moghaddam A, Ermisch C, Schmidmaier G. Non-union current treatment concept. *Shafa Ortho J.* 2016;3(1):4546.
5. Nolte P, Vander-Krans A, Patka P, et al. Low-intensity pulsed ultrasound in the treatment of nonunions. *J Trauma.* 2001;51:693-702.
6. Harrison A, Lin S, Pounder N, et al. Mode and mechanism of low intensity pulsed ultrasound in fracture repair. *Ultrasonics.* 2016;70:45-52.
7. Kooistra BW, Jain A, Hanson BP. Electrical stimulation: Non-unions. *Indian J Orthop.* 2009;43:149-55.
8. Mollon B, Da-Silva V, Busse J, et al. Electrical stimulation for long-bone fracture-healing: A meta-analysis of randomized controlled trials. *J Bone Joint Surg Am.* 2008;90:2322-30.
9. Aaron R, Ciombor D, Simon B. Treatment of non-unions with electric and electromagnetic fields. *Clin Orthop Relat Res.* 2004;419:21-29.
10. Wang FS, Kuo YR, Wang CJ, et al. Nitric oxide mediates ultrasound-induced hypoxia-inducible factor-1 α activation and vascular endothelial growth factor: A expression in human osteoblasts. *Bone.* 2004;35:114-23.
11. Leung KS, Cheung WH, Zhang C. Low intensity pulsed ultrasound stimulates osteogenic activity of human periosteal cells. *Clin Orthop Relat Res.* 2004;418:253-9.
12. Mundi R, Petis S, Kaloty R, et al. Low-intensity pulsed ultrasound: Fracture healing. *Indian Journal of Orthopaedics.* 2009;43(2):132-40.
13. Della-Rocca GJ. The science of ultrasound therapy for fracture healing. *Indian Journal of Orthopaedics.* 2009;43(2):121-6.
14. Zura R, Della-Rocca GJ, Mehta S, et al. Treatment of chronic (>1 year) fracture nonunion: Heal rate in a cohort of 767 patients treated with low-intensity pulsed ultrasound (LIPUS). *Injury.* 2015;46(10):2036-41.
15. Kanakaris NK, Giannoudis P. The health economics of the treatment of long-bone non-unions. *International Journal of the Care of the Injured.* 2007;38:77-84.
16. National Institute for health and Care Excellence. EXOGEN ultrasound bone healing system for long bone fractures with non-union or delayed healing. [MTG12] London: National Institute for health and Care Excellence. 2013.
17. Busse JW, Bhandari M, Einhorn TA, et al. Re-evaluation of low intensity pulsed ultrasound in treatment of tibial fractures (TRUST): Randomized clinical trial. *BMJ.* 2016;355:5351.
18. Poolman-Rudolf W, Thomas A, Siemieniuk-Reed AC, et al. Low intensity pulsed ultrasound (LIPUS) for bone healing: A clinical practice guideline. 2017;p:356.
19. Seger EW, Jauregui JJ, Horton SA, et al. Low-intensity pulsed ultrasound for nonoperative treatment of scaphoid nonunions: A meta-analysis. *Hand (NY).* 2010.
20. Leighton R, Watson JT, Giannoudis P, et al. Healing of fracture nonunions treated with low-intensity pulsed ultrasound (LIPUS): A systematic review and meta-analysis. *Injury.* 2017;48(7):1339-47.
21. Roussignol X, Currey C, Duparc F, et al. Indications and results for the Exogen™ ultrasound system in the management of non-union: A 59-case pilot study. *Orthopaedics and Traumatology Surgery and Research.* 2012;98(2):206-13.
22. Schofer MD, Block JE, Aigner J, et al. Improved healing response in delayed unions of the tibia with low-intensity pulsed ultrasound: Results of a randomized sham- controlled trial. *BMC Musculoskelet Disord.* 2010;pp:11-229.
23. Rutten S, Klein-Nulend J, Guit GL, et al. Low intensity pulsed ultrasound stimulation of delayed unions of the osteotomized fibula: A prospective randomized double-blind trial. Low-intensity pulsed ultrasound treatment in delayed bone healing [thesis] Amsterdam, the Netherlands: Vrije Universiteit Amsterdam. 2016.
24. Ricardo M. The effect of ultrasound on the healing of

- muscle-pediculated bone graft in scaphoid nonunion. *Int Orthop.* 2006;30(2):123-27.
25. Biglari B, Yildirim TM, Swing T, et al. Failed treatment of long bone non-unions with low intensity pulsed ultrasound. *Arch Orthop Trauma Surg.* 2016;136(8):1121-34.
26. Schandelmaier S, Kaushal A, Lytvyn L, et al. Low intensity pulsed ultrasound for bone healing: Systematic review of randomized controlled trials. *BMJ.* 2017;356:656.
27. Watanabe Y, Arai Y, Takenaka N, et al. Three key factors affecting treatment results of low-intensity pulsed ultrasound for delayed unions and non-unions: Instability, gap size, and atrophic nonunion. *J Orthop Sci.* 2013;18(5):803-10.

***Correspondence to:**

Samena Chaudhry, Senior Clinical Fellow,
Department of Paediatric Orthopaedics,
Royal Derby Hospital,
Uttoxeter Road,
Derby DE22 3NE, UK
Tel: +44 (0)1992 721 172
E-mail: samenachaudhry@hotmail.com