



Laryngocele A Review

.Balasubramanian Thiagarajan

Stanley Medical College

Abstract:

Laryngocele is a rare condition characterized by benign dilatation of laryngeal saccule. It may be asymptomatic in a majority of patients, but could present with neck swelling, hoarseness, cough and stridor. Clinically three types of Laryngocele have been documented i.e. Internal, External and Combined. Old published literature suggests that this condition is common in glass blowers. This article attempts to review published literature in the scenario of author's experience with 3 cases.

Introduction:

This condition was first described by Virchow in 1867¹. It was Virchow who coined the term Laryngocele. The first clinical description of Laryngocele was by Larry Surgeon of Napoleon's army in Egypt in 1829. He described it as a compressible pouch related to thyrohyoid membrane. Majority of laryngoceles are asymptomatic and can be managed conservatively². Surgery is reserved only for symptomatic cases.

Review of literature shows the incidence of laryngocele to be 1 per 2.5 million populations per year³. There are no accurate figures available as far as India is concerned. It is more common in males. Male female ratio is 5:1 with a peak incidence during 5th and 6th decades.

Laryngoceles are known to be intimately associated with laryngeal saccule. In true terms laryngeal saccule is an appendix of the laryngeal ventricle located between false cord and inner surface of thyroid cartilage. Laryngoceles could possibly result from abnormally large saccule that extends above the level of thyroid cartilage⁴. These structures communicate with the laryngeal lumen and are filled with air. These laryngoceles could be congenital and acquired.

Developmentally the saccule develops as an outpouching of the laryngeal cavity during the second month of intrauterine life. It is relatively large at birth, but continues to regress in size. The saccule is lined by pseudostratified ciliated columnar epithelium. It also contains numerous mucous glands in the submucosal areolar tissue. These glandular secretions keep the vocal cord moist and lubricated hence saccule is known as the oil can of the larynx.

Clinical features of laryngocele include:

Mostly laryngoceles are incidentally discovered during routine laryngeal examination. Symptoms if present may include:

1. Hoarseness of voice
2. Cough
3. Foreign body sensation in the throat
4. External / Combined laryngoceles may present with a neck mass close to the thyrohyoid membrane.
5. Large internal laryngoceles / combined laryngoceles may cause airway obstruction ⁷.

Types of laryngoceles include:

- Internal laryngocele
- External laryngocele
- Combined laryngocele

This is according to their relationship with the thyrohyoid membrane ⁵.

Internal laryngocele:

Internal laryngocele: is confined to the interior of the laryngeal cavity. It extends into the paraglottic region of the false vocal cord and aryepiglottic fold.

External laryngocele:

This type of laryngocele extends and dissects superiorly through the thyrohyoid membrane. It is intimately associated with superior laryngeal nerve. It is called external laryngocele because it frequently presents itself as lateral neck mass.

Combined Laryngocele:

In this type both internal and external components of laryngocele exist together.

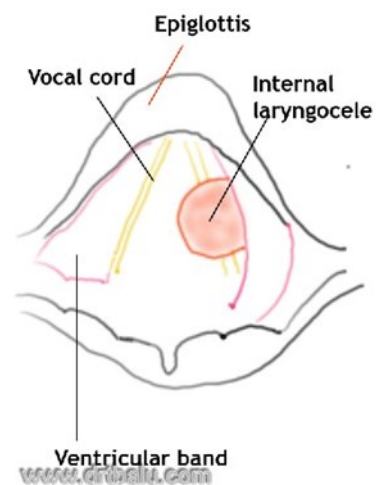


Image showing internal laryngocele

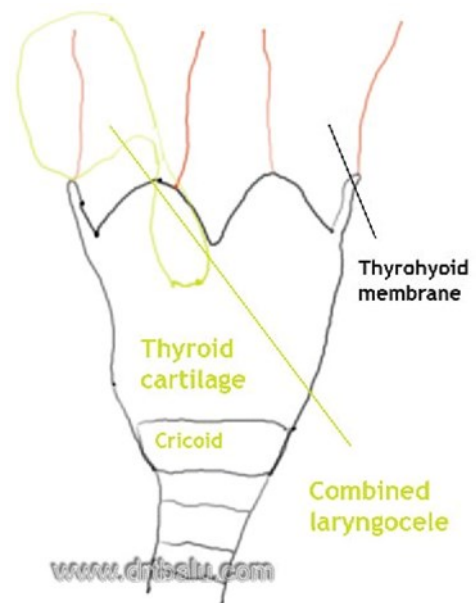


Figure showing combined laryngocele

If the communication between the laryngocele and the laryngeal lumen gets occluded, fluid may get accumulated within the sac. If the accumulated fluid is mucoid in nature the term laryngomucocele is used. If it is filled with pus then laryngopyocele is used to describe the mass.

Laryngoceles are rare in infants. If they are found they are invariably congenital in nature. They must be carefully differentiated from saccular cysts. These congenital laryngoceles may be managed conservatively, provided there is no airway compromise. If saccular cysts are present in infants they must be decompressed / aspirated.

Since laryngoceles may be associated with laryngeal malignancies, its presence in a old patient should prompt the examiner to diligently search for laryngeal malignancy.

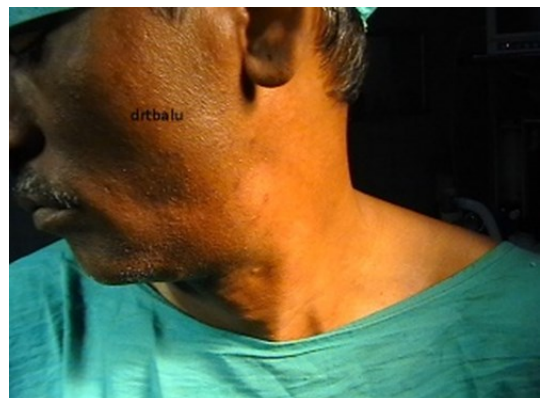Indirect laryngoscopy is diagnostic. Indirect / combined laryngoceles appear as submucosal mass in the region of false vocal cord. If fibre optic laryngoscope is used these masses can be seen to enlarge during a valsalva maneuver. In pure external laryngoceles endolaryngeal examination will be normal.

If combined laryngocele is presenting as a neck mass, compression will cause a hissing sound as the air escapes from it (Bryce sign) into the larynx. This test is fraught with danger in cases of combined laryngoceles because air from the external component may get forced into the internal component causing acute airway obstruction.

Pathophysiology: Factors that cause an increase in intra laryngeal pressure like coughing, straining, blowing wind instruments may cause laryngocele. Gradual weakening of the laryngeal tissues due to aging also plays a role in the Pathophysiology of development of laryngocele. In fact laryngoceles have been considered to be a health hazard in glass blowers. The neck of the saccule has been postulated to act as a one way valve allowing accumulation of air and preventing its egress.

Etiology of laryngocele is not very clear. Lots of controversies shroud this topic. Laryngoceles have been described in neonates; hence congenital element could also be involved. Anatomical variations of saccule⁶ combined with raised intra laryngeal pressure could play a role. Causes of elevated intralaryngeal pressure include:

1. Chronic persistent cough
2. Malignancy larynx
3. In professionals who constantly voluntarily increase intralaryngeal pressure like glass blowers and horn players



Neck swelling due to laryngocele anterior to sternomastoid muscle

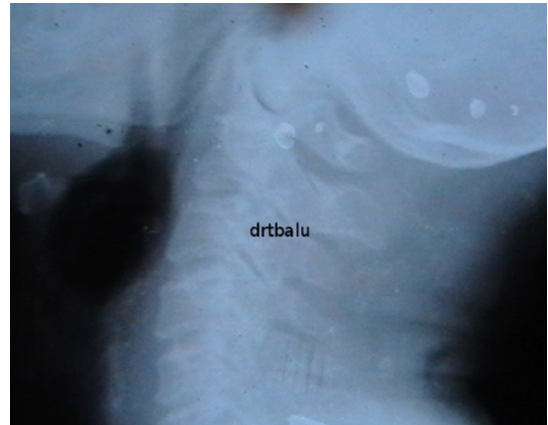Symptoms of laryngocele are dependent on their type. External and combined laryngoceles present with neck mass anterior to the sternomastoid muscle. Classically this mass is soft in nature, reducible and increases in size on Valsalva maneuver. Laryngoceles are usually non tender and soft. If the neck mass is tender, and tense then infected laryngocele / pyocele is a distinct possibility.

The laryngoceles must be differentiated from saccular cysts; which is filled with mucous, and don't communicate with the laryngeal lumen. These saccular cysts are common in infants while laryngoceles are common in adults.

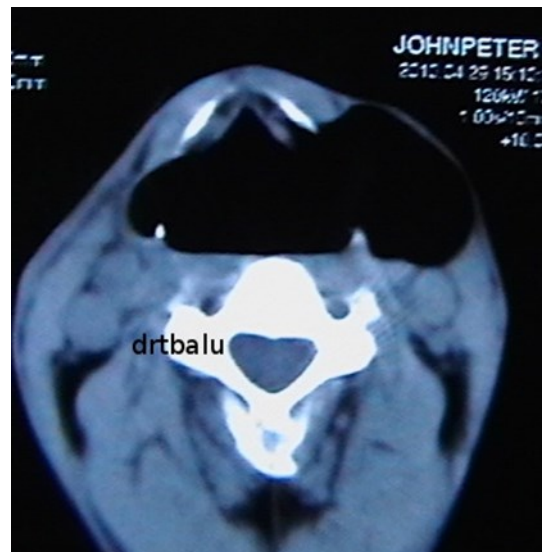
Differences between laryngocele and saccular cysts

Laryngocele	Saccular cyst
Filled with air	Filled with mucous
Common in adults	Common in children
Sac communicates with laryngeal cavity	Sac does not communicate with laryngeal cavity

Radiological examination: Plain x-ray soft tissue neck show air filled sac protruding from the soft tissues of neck. X-ray when repeated on Valsalva maneuver the size of the mass shows increase in size. Small internal laryngoceles are difficult to identify radiologically in plain films. CT scans are diagnostic.



X ray soft tissue neck lateral view showing air filled sac



CT scan axial view of neck: Showing air filled sac in the neck extending from the interior of larynx

CT scans is the most accurate imaging. It clearly defines the spatial relationship with the mass and the larynx. It also helps in differentiating laryngocele from other cystic lesions. This imaging modality also helps in ruling out co-existent laryngeal malignancy⁸.

Management:

External lateral neck approach is commonly favored by most surgeons to excise laryngocele because of its excellent exposure, minimal morbidity and reduced chances of recurrence. To manage internal laryngoceles a small portion of thyroid cartilage may have to be removed to allow adequate exposure. External and combined laryngoceles can be dissected via the thyrohyoid membrane and cartilage sacrifice is not required.

The surgeon approaches the mass through a horizontal incision over natural skin crease just over the region of thyrohyoid membrane. The mass overlies this area hence there may not be any difficulty in identifying the thyrohyoid membrane area. Skin flaps are elevated in the subplatysmal plane. The bulging strap muscles may be transected for better exposure of the mass. The carotid sheath is pushed posteriorly. The ansa cervicalis nerve may be adherent to the laryngocele and may be dissected out / transected if necessary. When the laryngocele is delivered there is dehiscence in the thyrohyoid membrane which is closed with sutures.

During this procedure the superior laryngeal nerve must be identified and carefully preserved since it could be intimately related to the mass.

Complications of this procedure include:

1. Airway compromise due to mucosal oedema
2. laryngo cutaneous fistula
3. Subcutaneous emphysema
4. Injury to superior / internal laryngeal nerve

Laryngofissure: Here larynx is opened in the midline. A submucosal or transmucosal technique can be used to remove small internal laryngoceles. The major disadvantage of this procedure is the risk of anterior commissure blunting and subglottic stenosis.

Endoscopic approach: can be resorted to in small internal laryngoceles. The cyst is decompressed internally. Recurrence is common in this procedure. This approach is commonly used because internal small laryngoceles are the most common types encountered. When carbon dioxide laser⁹ is used surgery can be performed with less bleeding and with greater ease.

CT guided needle aspiration:

Major advantage of this procedure is that it acts as both diagnostic as well as therapeutic procedure. This also helps in securing patient's airway before surgical excision in huge laryngoceles.

Conclusion:

Laryngocele is a rare condition. It is commonly an incidental finding. Management is dependent on the type of laryngocele. Small internal laryngoceles can be managed by endoscopic resection while large external and combined laryngoceles can be removed via external approach. Use of laser has facilitated safe endoscopic resection of internal laryngoceles.

References:

1. Al-Tamimi S, Nawaiseh S, Hiari MA, Al-Hrout A. Combined Laryngocele: A Case Report. *Journal of the Royal Medical Services* 2010; 17: 51-3. (Available online on, <http://www.jrms.gov.jo/Portals/1/Journal/2010/pdf%20feb2010/62-04%20Al-Tamimi-14.pdf>, accessed on 29-01-2012)
2. George IR, Hasan S, Kumar GN, Tobook SMS, Dhinakar M. A rare case of laryngocele in a young Omani male. *Oman Medical Journal* 2010; 25. (Available online on, <http://www.omjournal.org/CaseReports/FullText/201004/ARareCaseofLaryngocelein.html>)
3. Vasileiadis I, Kapetanakis S, Petousis A, Stavrianaki A, Fiska A, Karakostas E. Internal laryngopyocele as a cause of acute airway obstruction: an extremely rare case and review of the literature. *ACTA Oto Rhinolaryngologica Italic* 2011; 31. (Available online on <http://www.actaitalica.it/issues/earlyview/Vasileiadis%20early%20view.pdf>)
4. http://www.drtdbalu.co.in/l_cele.html
5. Verret DJ, DeFatta RJ, Sinard R. Combined laryngocele. *Ann Otol Rhinol Laryngol* 2004;113:594–6.
6. Ingrams D, Hein D, Marks N. Laryngocele: an anatomical variant. *J Laryngol Otol* 1999;113:675-7.
7. Gallivan KH, Gallivan GJ. Bilateral mixed laryngoceles: simultaneous stroboscovideolaryngoscopy and external video examination. *J Voice* 2002;16:258-66.
8. Larsen JL, Lind O. Laryngocele. *Tidsskr Nor Laegeforen* 1991;111:1488-9.
9. Devesa PM, Ghufloor K, Lloyd S, et al. Endoscopic CO2 laser management of laryngocele. *Laryngoscope* 2002;112:1426–30