



Intralesional steroid for Infantile Parotid Hemangiomas: An understanding with a case report

Anju Chauhan, Vikram Wadhwa, Samuel Rajan , P.K. Rathore

Maulana Azad Medical College, New Delhi, India

ABSTRACT

Hemangiomas are the most common parotid gland tumours in children. These lesions commonly go unnoticed in the newborn period but become conspicuous in the initial months of life. They increase in size during the first year of life and typically regress during the next decade. The presentation of hemangioma is variable in relation with their size, extent and morphology (1). These may be part of a V3 mandibular segment hemangioma associated invariably with cutaneous involvement and occasionally with airway involvement, or they may present as isolated focal hemangioma (2). These lesions display female predilection. There is an increased frequency of hemangiomas in premature infants and are uncommonly seen in dark skinned infants (1).

In the first year of life, hemangiomas account for approximately 50% of parotid tumours (3). Because these lesions have an affinity for ectoderm, the parotid gland and the minor salivary glands of the lower lip mucosa are the only salivary gland affected (4). Diagnosis can be established by various diagnostic techniques like ultrasonography, computed tomography or MRI. Owing to the benign nature of these hemangiomas, many authors favour conservative, non-operative treatment, including corticosteroids (systemic or intra-lesional), interferon, propranolol and various sclerosants.

We here present a child with a parotid hemangioma involving both lobes of parotid who showed substantial regression following intralesional dexamethasone along with an insight into review of literature.

Case report

An eight year old child presented to ENT out patient department with the complaint of swelling over left preauricular area for four years. The swelling was painless and progressively enlarging. On examination, a non pulsatile , soft, compressible swelling in left preauricular area, 3×2 cm in size with ill defined margins was noted. Overlying skin was normal and there was facial asymmetry. The child was a term baby, and had normal developmental milestones. FNAC was suggestive of vascular lesion. Ultrasonography revealed multiple hypoechoic lesions in parotid gland. MRI of left parotid region demonstrated a lesion of mixed signal intensity with thin septations in both superficial and deep lobes of parotid gland. It showed intense post contrast enhancement suggesting hemangioma (Figure no 1). There was also partial involvement of masseter and temporalis muscle. After counselling the parents of the patient, medical management in the form of intralesional dexamethasone was started. Single shot of calculated dose (0.8- 1.6 mg/kg) was given fortnightly for six months. There was marked regression observed in size of the lesion (Figure no . 2) and a follow-up ultrasonogram revealed multiple anechoic small areas in left parotid gland and decreased size of lesion and no flow was seen in power Doppler (Figure no. 3). The patient is in regular follow-up and is symptom free now.

Discussion

Vascular anomalies have been confronted with confusing terminology leading to improper diagnosis, illogical treatment and misdirected research. In 1982, a biologic classification system incorporating physical findings, natural history and cellular features was introduced which consists of two major categories: tumours and malformations (5).

Vascular tumours are endothelial neoplasm featuring increased cellular proliferation. Hemangioma (the most common and exclusive in infants), hemangioendothelioma, tufted angioma, hemangiopericytoma and rarely angiosarcoma are the examples included in this group (1). Vascular malformations are the result of abnormal development of vascular elements during embryogenesis and fetal life. They include capillary, arterial, lymphatic, or venous types. These malformations do not generally demonstrate increased endothelial turnover. Rarely vascular tumours and vascular malformations can coexist (1).

Hemangiomas are endothelial tumours which grow rapidly, regress slowly and never recur. The three stages in the life cycle of a hemangioma are ; (1) proliferative phase (0-1 year of age), (2) the involuting phase (1-5 years of age), (3) the involuted phase (> 5 years of age) (1). If there is dermatomal involvement of V1,V2 , or V3, consideration must be in favour of PHACES syndrome (Posterior fossa malformations, Hemangioma, Arterial anomalies, Coarctation of aorta and cardiac defects, and Eye abnormalitieS). Airway involvement manifest due to subglottic hemangioma characterized by hoarseness , dyspnea, and biphasic stridor between 4-12 weeks of age. Spontaneous epithelial breakdown, crusting, ulceration and necrosis occurs in 5% of cutaneous hemangiomas. An infant with five or more cutaneous hemangiomas should be suspected to have visceral hemangiomas and lumbosacral hemangiomas are associated with an underlying tethered spinal cord (1).

Hemangiomas of parotid gland are diagnosed on clinical findings that are substantiated by imaging techniques. Ultrasonography is initial diagnostic technique for assessment of these lesions which satisfactorily differentiates dermal/cutaneous and glandular lesions. Ultrasonographically Hemangiomas are generally hypoechoic relative to parotid tissue and at Doppler ultrasonography it displays a variable degree of abnormal flow (6). Hemangiomas are homogeneous hyperintense on T2 weighted MRI and they are usually isointense when compared to muscle on T1 weighted MRI. Internal flow voids may be seen in hemangioma (7).

Due to their natural history, various authors have documented different treatment protocols to shorten this long involution process. Because the size of lesion, location, sex and age at presentation do not affect the clinical course, it is often perplexing to decide which cases will achieve complete resolution and which cases will result into residual disfigurement (8). Conservative approach of observation and regular follow-up is indicated in patients in whom there is minimum expansion of lesion, involution is expected, and there are no clinical sequelae as cardiomegaly and/or CHF. In all other cases, active intervention is necessary (4). Medical management consists of corticosteroids, sclerosants and various drugs.

Intralesional corticosteroid injection into an enlarging parotid lesion has shown good results without the serious side effects seen with systemic steroid therapy. Steroid is thought to incite cessation of angiogenesis process eventually arresting their expansion (4). Boon et al reported 62 patients treated with corticosteroids and described short term complications like cushingoid facies, personality changes, gastric irritation, fungal infections, weight gain and diminished growth (9).

Systemic corticosteroid treatment is given in the form of prednisolone or prednisolone elixir, 2-4 mg/kg/day for a continuous period. Rebound growth after cessation of treatment is usually seen and side effects are often severe, although mostly transient (4). Some authors have reported of treating parotid hemangiomas up to 9 cm large with triamcinolone with gratifying results up to 70% in infants (< 1 year) but failure to thrive is a potential complication (10).

Systemic IFN alpha-2a possesses antiangiogenic properties and was widely used alone or in conjunction with corticosteroid injection. However cases of irreversible spastic diplegia have been reported after its use so it is no longer advised for treatment in children with hemangiomas. Systemic vincristine then has been adopted as an alternative for the treatment of corticosteroid resistant hemangiomas (1). In a study of 13 patients treated with oral steroids and interferon alfa-2a therapy, Blei et al noted no improvement in parotid hemangioma size, implying that lesions in this site behave stubbornly than those limited to skin and subcutaneous tissue (11).

Parotid hemangiomas, particularly those with a deep component and segmental morphologic features are somewhat more resistant to therapy with corticosteroids or interferon alfa-2a (12). A group of French authors were the first to report in 2008 the role of propranolol in inhibiting the growth of large hemangiomas and since then it is in use as a drug of choice (at therapeutic doses of 2-3 mg/kg/day in divided doses) (6) showing encouraging results (13).

However , it should only be used in complicated cases where rapid growth poses functional problems and not for those cases having cosmetic aspect alone(6).

Sclerotherapy for enlarging parotid lesions with embolic substance has also been reported. An antineoplastic drug bleomycin has been described as a sclerosing agent in alone or in conjunction with surgery (4).Pre-operative treatment of large parotid hemangioma with intralesional injection of 100% ethyl alcohol solution to reduce the size of mass has also been described (3). Pulsed –dye laser (595 nm) has been used with gratifying results. It is used for superficial skin staining. It does not penetrate sufficiently into a hemangioma in parotid gland (4).

Surgical intervention should be considered during each of three stages for specific indication: 1. proliferative phase –obstruction, visual or subglottic, deformation, ulceration or bleeding unresponsive to other therapies. 2- involuting phase- when resection is inevitable, scar issues. 3- involuted phase - damaged skin, abnormal contour and distortion (1).Even though cheek skin and underlying tissue may revert to normalcy, there is usual permanent residual telangiectasia, tissue laxity and cheek fullness ensuing involution of large parotid hemangiomas (14). There is no role for irradiation in the management of cutaneous hemangioma (1).

In conclusion, during the last few decades, the management protocol of hemangiomas has undergone substantial change. Naming hemangioma as a universal diagnosis for all vascular malformations will not only lead to irrevocable complications but also to increased expenditure and mental and social stigma. A clear demarcation between focal and segmental haemangioma must be established before instituting definitive treatment.

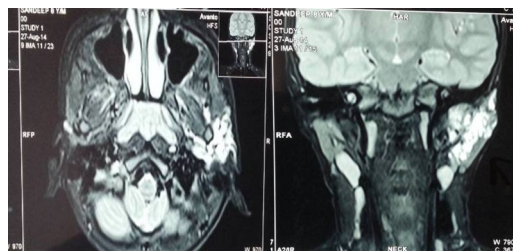


Fig 1 MRI of left parotid (coronal and axial cuts) reveals intensely enhancing tubular lesion involving preauricular area and superficial and deep lobes of parotid

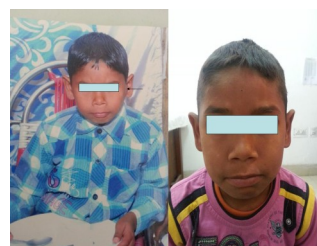

Fig 2 Pre- and post-treatment picture of the patient

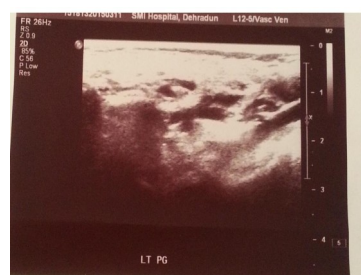

Fig 3 Post –treatment USG revealing multiple anechoic tubular areas in left parotid gland. No flow is seen on power Doppler

References:

1. Marler JJ, Mulliken JB. Current management of hemangiomas and vascular malformations. *Clin Plastic Surg* 2005;32:99-116.
2. Waner M, Suen JY. Hemangiomas and vascular malformations of the head and neck. New York: J. Wiley; 1999.
3. Emsen IM. Preoperative treatment of a parotid hemangioma with 100% ethyl alcohol. *Can J Plast Surg* 2008;16(4):239-40.
4. Weiss I, Teresa M, Lipari BA, Meyer L, Berenstein A, Waner M. Current treatment of parotid hemangiomas. *Laryngoscope* 2011;121:1642-50.
5. Mulliken JB, Glowacki J. Hemangiomas and vascular malformations in infants and children: A classification based on endothelial characteristics. *Plast Reconstr Surg* 1982;69:412-22.
6. Mantadakis E, Tsouvala E, Deftereos S, Danielides V, Chatzimichael A. Involution of a large parotid hemangioma with oral propranolol: An illustrative report and review of the literature. *Case Rep Pediatr*. 2012;2012:5. [DOI]
7. Guneyli S, Ceylan N, Bayraktaroglu S, Acar T, Savas R. Imaging findings of vascular lesions in the head and neck. *Diagn Interv Radiol* 2014;20:432-437.
8. Bentz BG, Hughes CA, Ludemann JP, Madalozzo J. Masses of the salivary gland region in children. *Arch Otolaryngol Head Neck Surg* 2000;126:1435-9.
9. Boon LM, MacDonald DM, Mulliken JB. Complications of systemic corticosteroid therapy for problematic hemangioma. *Plast Reconstr Surg* 1999;104:1616-23.
10. Buckmiller LM, Francis CL, Glade RS. Intralesional steroid injection for proliferative parotid haemangiomas. *Int J Pediatr Otorhinolaryngol* 2008;72(1):81-87.
11. Blei F, Isakoff M, Deb G. The response of parotid hemangiomas to the use of systemic interferon alfa-2a or corticosteroids. *Arch Otolaryngol Head Neck Surg* 1997;123(8):841-4.
12. Brandling –Bennett HA, Metry DW, Baselga E, Lucky AW, Adams DM, Cordisco MR, Frieden IJ. *Arch Dermatol* 2008;144(12) 1650.
13. Leaute –Labreze C, Dumas de la Roque E, Hubiche T, Boralevi F, Thambo JB, Taieb A. Propranolol for severe hemangiomas of infancy. *N Engl J Med* 2008;358:2649-51.
14. Reinisch JF, Kim RY, Harshbarger RJ, Meara JG. Surgical management of parotid hemangioma. *Plast Reconstr Surg* 2004;113:1940-1948.