



Inanimate foreign bodies in the nasal cavity: a challenge in pediatric rhinology

Sudhir M Naik¹, Ravishankara S², Mohan Appaji³, Goutham MK⁴, N Pinky Devi⁵, Sarika S Naik⁶

¹ Fellow, Department of Cosmetic and Aesthetic surgery, Cosmetic surgery institute of India, Mumbai.

³ Associate Professor , Department of ENT, Head and Neck surgery, KVG Medical College, Sullia, Karnataka.

² Professor, Department of ENT, Head and Neck surgery, KVG Medical College, Sullia, Karnataka.

⁴ Assistant Professor , Department of ENT, Head and Neck surgery, KVG Medical College, Sullia, Karnataka.

⁵ Junior resident, Department of ENT, Head and Neck surgery, KVG Medical College, Sullia, Karnataka.

⁶ Senior resident, Department of Anaesthesia and Critical care, Narayana Hrudayalaya, Bangalore.

ABSTRACT

Background: Nasal cavities foreign bodies are common emergencies in pediatric rhinology, sometimes leading to life threatening complications of broncho-aspiration.^{1,2} Diagnosis is often made by anterior rhinoscopy, but sometimes nasal endoscopy and imaging may be needed for deep seated foreign bodies.^{1,2}

Objectives: To evaluate 79 cases of inanimate nasal foreign bodies removed in our ENT OPD & type of foreign body and complications.

Materials and method: 79 cases of nasal foreign bodies removed in the ENT OPD between February 2008 and June 2010 were evaluated.

Result: We found higher incidence between 0 and 2 years of age, and the most frequently found foreign bodies were small plastic objects in 21 cases (26.25%), food grain in 18 cases (22.78%), stone pieces in 9 cases (11.39%), sponge pieces in 7 cases (8.86%), dress buttons in 6 cases (7.59%), seeds in 7 cases (8.86%), button battery cells in 5 cases (6.32%), parts of toys in 4 cases (5.06%) & chalk pieces in 2 cases (2.53 %).

Conclusion: Nasal foreign bodies are especially found between the ages of 0 and 2 years. In our study, small plastic objects, food grain, stone pieces were the most frequent foreign bodies found.^{2,3} 75 cases were removed successfully in OPD & 4 cases needed general anesthesia for removal.

Complications rate of 17.72% was seen in our study. Epistaxis and vestibulitis were the complications & no broncho-aspiration seen.

Introduction

Foreign bodies in the nasal cavity are a common problem, especially in pediatric otolaryngology, sometimes followed by complications with varying severity.⁴ The first years of a child's life represent a phase of exploration and interaction with the environment.⁵ When they start moving by their own means (crawling and walking), the child starts having access to a number of objects that have to be duly explored.⁵ This process encompasses, amongst other things, the placement of objects in orifices, such as nose.⁵ Parent's laxness and lack of attention, leaving small objects at the child's reach and not properly watching them, much contributes to this high incidence of foreign bodies.⁵ Nose is the most exposed orifice, hence the high incidence of foreign bodies in it.⁵ In adults foreign bodies in the nasal cavities are seen in patients with psychiatric disorders.⁵

The presence of foreign bodies in nasal cavities is one of the most common causes of emergency in pediatric otolaryngology.^{6,7} The cases of nasal foreign bodies often cause symptoms such as sneezing, common cold and nasal blockage that develop to unilateral purulent and fetid rhinorrhea^{6,7}. The longer the presence more excessive are the symptoms in the nasal cavities.^{6,7}

These foreign bodies can be introduced spontaneously or accidentally.⁵ The former is more common in children and the latter in adults with psychiatric disorders.⁵ These nasal foreign bodies may be animate or inanimate.⁵ Animate foreign bodies are rare & we could not find any animate foreign bodies in our study.⁵

The size and shape of the foreign body can determine the difficulty in its removal, what can cause minor epistaxis to life threatening complication like bronchoaspiration.^{2,8} The great potential for complications during the removal of these foreign bodies makes the performance of the ENT doctors important in this procedure.^{2,8} The success of the removal of foreign body depends on the cooperation of the patient, the ability of the doctor in visualizing the foreign body, the type of the foreign body, the previous manipulation done and the availability of the suitable instrument in removing it.^{2,8}

In our study, a brief history of the patient was taken. The type of foreign body, time of insertion, clinical signs & symptoms, previous attempts at removal of the foreign body were all recorded in detail.

Materials and Methods

In our study, records of 79 patients were retrospectively examined from February 2008 to May 2010.

They were suspected of foreign body in the nose. Such patients were shifted to ENT OPD & a reassurance to the accompanying parents was given. The patient was made to sit on parents lap & anterior nasal rhinoscopy performed with Thudicum's nasal speculum. In 75 cases the foreign bodies were anteriorly placed & seen on anterior rhinoscopy but in 4 cases the patients were too uncooperative for anterior rhinoscopic examination. Exact location, type, size of the foreign body located in the nasal cavity was noted and explained to parents (fig 1,2). Anteriorly placed foreign bodies were removed using Jobson's Horne probe with ring curette (or Rose Eustachian catheter/ Wire vectis usually used in cataract surgery). (fig 3)

After removal of the foreign body, the nasal cavity was examined. Bleeding if present was controlled by pinching the nostrils. All the patients were observed for 30 minutes. All the 75 patients who were treated in the OPD were discharged within an hour after the procedure. No complications were seen which led to admission of the patient. In 4 cases general anaesthesia was preferred as the children were too uncooperative for examination & removal in the OPD. In these 4 cases the foreign bodies were removed under general anaesthesia with cuffed oral endotracheal tube & a pharyngeal pack inserted. 2 foreign bodies were removed from the anterior nares, but 2 were wedged posteriorly & could be removed through the nasopharynx.

Here in these 4 cases unilateral nasal packing was done using merocel packs. The merocel packs were removed in 24 hours. All the 4 were discharged after 24 hours with post-operative antibiotics, anti-inflammatory drugs & decongestants nasal drops.

Results

79 cases of foreign bodies in nasal cavity were studied. When evaluating the distribution of the cases regarding age of patients, there was an absolute concentration on those less than 5 years, only one case of a 7-year-old patient.

42 patients (53.16%) belonged to the age group 0- 2 years, 34 patients (43.03%) belonged to the age group 2- 4 years, 2 patients (2.53%) belonged to the age group 4-6 years and 1 patient (1.26%) belonged to the age group of more than 6 years. (table 1) .

The foreign body was removed in the OPD itself in 75 cases (94.93%) but in 4 patients (5.06%) it was done in the operation theatre. The instrument used for removing them was Jobson Horne probe with curette, wire vectis or Rose Eustachian catheter. No anaesthesia was given to the 75 patients treated in OPD but 4 uncooperative patients were shifted to the operation theatre and removed under general anaesthesia.

54 cases (68.35%) presented with foreign body in the right nasal fossa and 25 cases (31.64%) in the left nasal fossa. Incidence was more in boys (56 cases, 70.88%) when compared to girls (23 cases, 29.11%). (table 2)

A great variety of foreign bodies were observed in our study. The most frequent ones were: small plastic objects in 21 cases (26.25%), food grain in 18 cases (22.78%), stone pieces in 9 cases (11.39%), sponge pieces in 7 cases (8.86%), dress buttons in 6 cases (7.59%), seeds in 7 cases (8.86%), button battery cells in 5 cases (6.32%), parts of toys in 4 cases (5.06%) & chalk pieces in 2 cases (2.53%). (table 3)

Most of the patients presented with foreign bodies introduced with less than 12 hours duration, so no signs of nasal discharge was seen. But patients who came with history of more than 12 hours duration presented with unilateral nasal discharge. The main symptoms were unilateral nasal discharge in 15 patients (18.98%) and foul smelling unilateral nasal discharge in 6 cases (7.59%). Only in 4 patients (5.06%) attempts of removal of the foreign body was done by non ENT doctors but in all cases they were unsuccessful. After removal epistaxis was seen in 6 (7.59%) cases and vestibulitis in 8 (10.12%) cases. (table 4)

According to development time, most of foreign bodies were removed on the first day, in 66 cases (83.54%), 5 cases (6.32%) had their removal on the second day, 2 was removed on the third day (2.53%), 2 on the fourth (2.53%), 1 on the fifth (1.26%), 1 on the seventh day (1.26%) and 2 were removed between the tenth and fourteenth days (2.53%). (table 5)

2 drops of 0.25% oxymetazoline decongestant nasal drops was used in all cases after foreign body removal. Oral antibiotic therapy was necessary in 8 patients (10.12%) because of vestibulitis. Epistaxis seen in 6 (7.59%) cases was managed with 0.25% oxymetazoline decongestant nasal drops for 3 days. No complications were seen in 65 (82.27%) cases.

Discussion

Nasal foreign bodies can be found in any portion of the nasal cavity, although they are typically discovered around the floor of the nose just below the inferior turbinate.⁴ Another common location is immediately anterior to the middle turbinate.⁴ These objects are generally placed by children whose curiosity leads them to explore body orifices.⁵ Any article small enough to be admitted into the anterior nasal orifice can be introduced into the nasal cavity.⁵ Foreign bodies that are impacted or those that have been present for some time cause difficulty while removal.^{2,8} Some foreign bodies are inert and may remain in the nose for years without mucosal changes.⁹ However, most inanimate objects initiate congestion and swelling of the nasal mucosa, with the possibility of pressure necrosis producing ulceration, mucosal erosion, and epistaxis.⁹ The retained secretion, the decomposed foreign body, and the accompanying ulceration can result in foul smelling nasal discharge.⁹ These changes further impact the foreign body because of surrounding oedema, granulations, and discharge.⁹ This is particularly seen with vegetable foreign bodies which not only absorb water from the tissues and swell but also evoke a very brisk inflammatory reaction.^{9,10} Occasionally, the inflammatory reaction is sufficient to produce toxemia.^{9,10}

Button batteries may result in severe destruction of the nasal septum.¹¹ These are composed of various types of heavy metals: mercury, zinc, silver, nickel, cadmium, and lithium.¹¹ Liberation of these substances causes various types of lesions depending on the localisation, with an intense local tissue reaction and liquefaction necrosis.¹¹ As a result they can cause septal perforations, synechiae, constriction, and stenosis of the nasal cavity.¹¹

A cooperative patient is needed to detect and remove a nasal foreign body successfully.¹² The patient is usually examined in the upright sitting position carried out for routine otorhinological examination.¹² A child may be best examined by tilting the head back slightly so that the floor of the nose is visible to the examiner.¹² For this an adult may need to restrain a child and hold the head steady.¹²

Most inanimate foreign bodies, if visualised well, can be removed easily through the anterior nares with the use of Jobson's probe or eustachian tube catheters, and suction.¹³ This can be done either with no anaesthetic or after spraying with a local topically acting anaesthetic solution such as 4% lignocaine.¹³ Removal of a rounded object may be a risky task because of difficulty in grasping foreign bodies of this shape.¹³ A curved hook is best suited for this job.¹³ The hook is first passed behind the object, the tip rotated to rest just behind it and then the foreign body is gradually drawn forwards and out through the nose.¹³ Additionally, several suction methods have been described that aid in the removal of round foreign bodies.¹³ Plastic objects and vegetable matter may be difficult to extract because of their tendency to break into small pieces.¹³

Non ENT doctors should not attempt to remove the foreign body.¹⁴ The foreign body may be displaced backwards and may even reach the nasopharynx with a risk of bronchoaspiration.¹⁴ Marked epistaxis may occur making the nervous child very uncooperative.¹⁴ Here foreign body removal under general anaesthesia will become absolutely necessary.¹⁴ Posteriorly placed nasal foreign bodies should be removed by pushing it posteriorly into the nasopharynx under general anaesthesia.⁵ Here cuffed endotracheal intubation with pharyngeal packing should be used to protect the airway.⁵

After successful removal of a nasal foreign body, careful examination of the involved nasal cavity to exclude the presence of foreign body fragments should be done.⁵ Additionally, epistaxis which frequently accompanies the removal of nasal foreign bodies must be treated by digital pressure on the nostrils & nasal decongestant drops.⁵

In our study maximum numbers of cases were observed in the age group 0- 2 years and age group 2- 4 years. Incidences were more in boys (56 cases, 70.88%) when compared to girls (23 cases, 29.11%). These two data are similar to that described in literature. Regarding the side of presentation of the foreign body, predominance was not observed. There was only one case in which foreign bodies were found in the two nostrils.

In our study it was noticed that the symptoms like unilateral nasal discharge increased with delay in treatment time. Most of the patients gave a history of less than 12 hours of introduction of the foreign body. So no clinical symptoms were observed in them. 15 patients had unilateral nasal discharge & 6 patients had foul smelling unilateral nasal discharge as they delayed contacting the doctor.

2 drops of 0.25% oxymetazoline decongestant nasal drops was used in all cases after foreign body removal. After removal complications in the form of vestibulitis was seen in 8 patients (10.12%). So oral antibiotics & topical antibiotic cream was prescribed in these 8 patients. Epistaxis which was seen in 6(7.59%) patients was managed by pressure over the anterior nares & later applying 0.25% oxymetazoline decongestant nasal drops for 3 days. No complications were seen in 65(82.27%) cases.

We found a complication rate of 17.72% which included epistaxis & vestibulitis. It was similar to study conducted by Marques et al. who found a complication rate of 19.19%.⁴ (table 6) In 6 cases button batteries were found in the nasal cavities and no complications was seen after removal as they presented early. Fosarelli et al., has reported destruction of the nasal septum with button batteries as foreign body which had corroded the septum for 7 days.¹¹ .

Conclusion

Nasal cavities foreign bodies are common emergencies in pediatric rhinology mostly seen in children below 4 years of age.¹⁵ In most situations they are avoidable if the parents are careful and attentive.¹⁵

The most common foreign bodies in our study were small plastic objects, food grains, stone pieces, sponge pieces, dress buttons, seeds, button battery cells, parts of toys & chalk pieces. Although in most situations they are removed without complications sometimes epistaxis and vestibulitis are seen. In our study no severe complications like broncho-aspiration seen. But every nasal foreign body can be aspirated if managed carelessly.¹⁶ It is important to that all cases of nasal foreign bodies should be removed by ENT surgeons only.¹⁶ Proper instruments should be used to avoid complications.¹⁶

Summary

In our study, the nasal foreign bodies were found especially in patients aging from 0 to 2. The main associated symptom was unilateral rhinorrhea. In most of the cases the foreign bodies were removed as a simple OPD procedure.

The most of cases of nasal foreign bodies are easily treated without complications, but some can develop serious complications, mainly when there is an attempt of removal by non ENT specialists.¹⁴ The most feared complication of nasal foreign bodies, although rare, is the broncho-aspiration.¹⁴ So an ENT doctor should be well trained in managing nasal foreign bodies as well as bronchoscopy to deal with broncho- aspiration.¹⁴

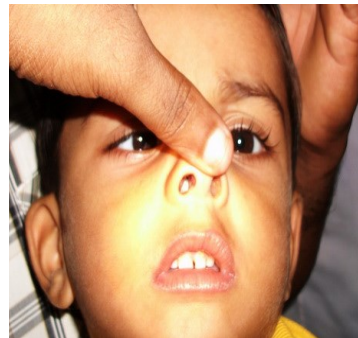

Fig 1: anteriorly placed nasal foreign body

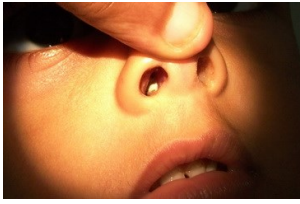

Fig 2: small plastic object foreign body seen in the anterior nares

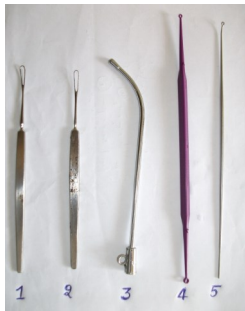

Fig 3: instruments used in removing the nasal foreign body

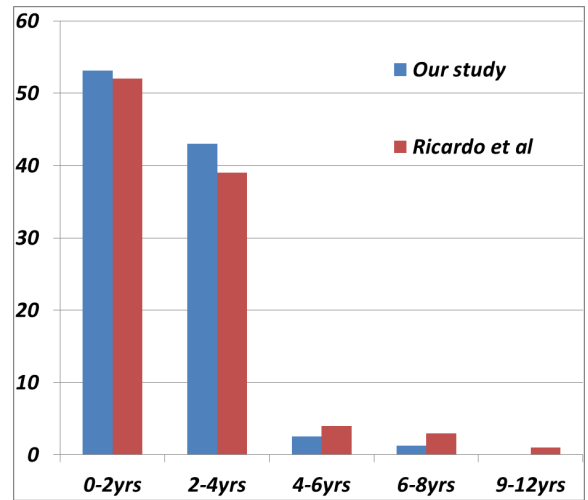


Table 1: Incidence by age³

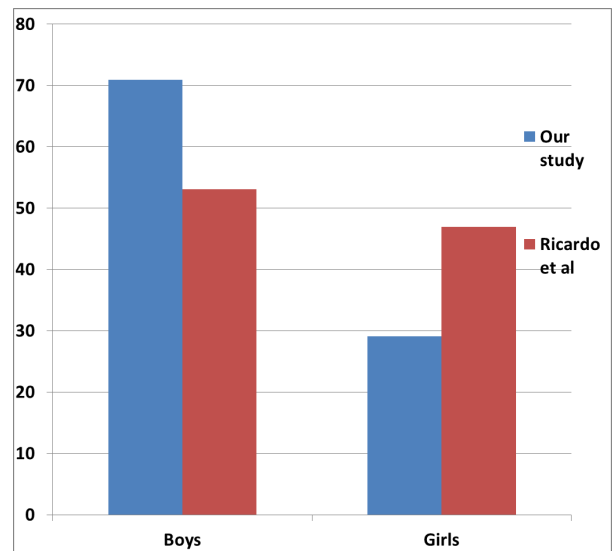


Table 2: sex incidence.³

| Type of foreign body | Cases | Per-centage |
|------------------------------|--------------|--------------------|
| Small plastic objects | 21 | 26.25 |
| Food grain | 18 | 22.78 |
| Stone pieces | 9 | 11.39 |
| Sponge pieces | 7 | 8.86 |
| Dress buttons | 6 | 7.59 |
| Seed | 7 | 8.86 |
| Button battery cell | 5 | 6.32 |
| Parts of toys | 4 | 5.06 |
| Chalk | 2 | 2.53 |
| Total | 79 | 100% |

Table 3: types of foreign body(our study)

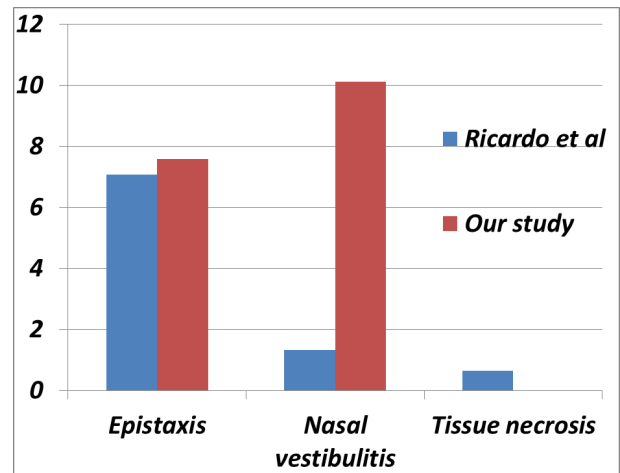


Table 4: Complications³

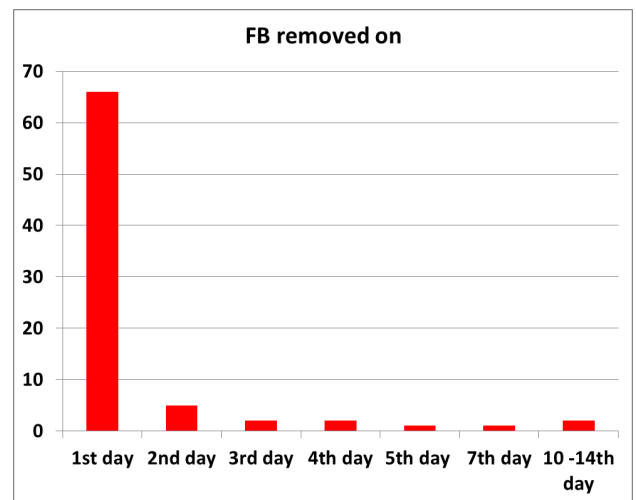


Table 5: treatment given on particular day after diagnosis

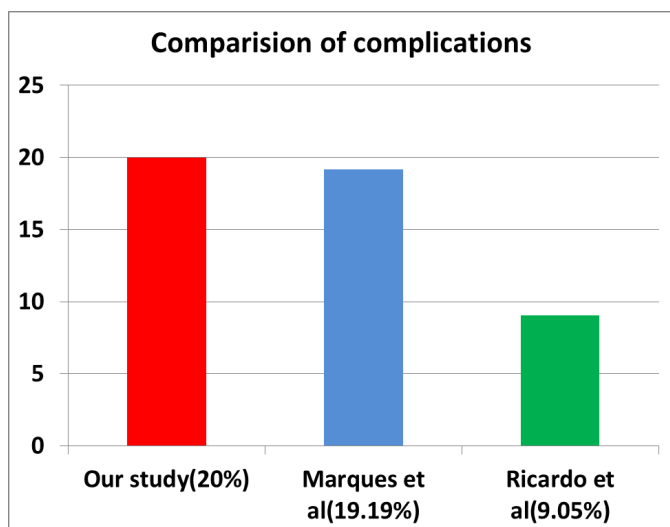


Table 6 : comparison of complication rates ^(3,4)

References

- Ikino CMY, D'antonio WEPA, Balbani APS, Sanchez TG, Butugan O. Análise dos atendimentos para retirada de corpos estranhos de ouvido e nariz em crianças. Rev Bras Otorrinolaringol. 1998; 64:379-83.
- Tiago RSL, Salgado DC, Corrêa JP, Pio MRB, Lambert EE. Corpo estranho de orelha, nariz e orofaringe: experiência de um hospital terciário. Rev Bras Otorrinolaringol. 2006; 72:177-81.
- Figueiredo RR, Azevedo AA, Kós AOA, Tomita S. Corpos estranhos de fossas nasais: descrição de tipos e complicações em 420 casos. Rev Bras Otorrinolaringol. 2006; 72:18-23.
- Marques MPC, Sayuri MC, Nogueira MD, Nogueirol RB, Maestri VC. Tratamento dos corpos estranhos otorrinolaringológicos: um estudo prospectivo. Rev Bras Otorrinolaringol. 1998, 64:42-7.
- Reilly J. Pediatric aerodigestive foreign body injuries are complications related to timeliness of diagnosis. The Laryngoscope 1997; 107: 17-20.
- Balbani APS, Kii M, Angélico Jr FV, Sanchez TG, Voegels RL, Butugan O, Câmara J. Atendimento para retirada de corpos estranhos de ouvido nariz e faringe em crianças. Revista de Pediatria do Centro de Estudos Prof. Pedro Alcântara. Instituto da Criança do Hospital das Clínicas da FMUSP. Pediatria (São Paulo) 1998; 20(1): 8-13.
- Sharif S, Roberts G, Philips J. Transnasal penetrating brain injury with a ball-pain. Br J Neurosurgery 2000;14(2): 159-60.
- Bressler K, Shelton C. Ear foreign-body removal: a review of 98 consecutive cases. Laryngoscope. 1993, 103(4PT1):367-370.
- Harner SG : Foreign bodies in the ear, nose and throat. Postgrad Med J 57:82–83. (1975)
- Paparella MM, Shumrick DA , Baluyot ST : Foreign bodies in the nasal cavity. in Otolaryngology. eds Paparella MM, Shumrick DA (WB Saunders, Philadelphia), (1980)
- Fosarelli .P, Feigelman . S, Pearson . E , Calimanodiaz .A(1988) An unusual intranasal foreign body . Pediatric Emergency Care.4. 117-118

12. Foreign bodies in the nasal cavities: a comprehensive review of the aetiology, diagnostic pointers, and therapeutic measures; *Postgrad Med J* 2000;76:484-487 doi:10.1136/pmj.76.898.484
13. McMaster WC; Removal of foreign body from the nose. *JAMA* 213:1905. (1970)
14. Kerr AG, Walby AP, Foreign bodies in the ear or nose. *Scott-Brown's otolaryngology*. Kerr AG (Butterworth-Heinemann, Oxford), 6th Ed. pp 6/14/1–6/14/6. (1997)
15. Figueiredo RR, Dorf S, Couri MS, Azevedo AA, Mossumez F. Corpos estranhos animados em otorrinolaringologia. *Rev Bras Otorrinolaringol*. 2002; 68:722-9.
16. Morris MS ;New device for foreign body removal. *Laryngoscope* 94:980;(1984)