



Human otoacariasis: a common outbreak in rubber growing belt of Karnataka.

Sudhir M Naik¹, Mohan Appaji², Ravishankar S³, Goutham MK⁴, Annapurna SM⁵, N Pinky Devi⁶, Sarika S Naik⁷

¹ *Fellow, Department of Head and Neck Oncosurgery, KMIO, Bangalore.*

² *Professor & Head of Department of ENT, Head and Neck surgery, KVG Medical College, Sullia, Karnataka.*

³ *Associate Professor, Department of ENT, Head and Neck surgery, KVG Medical College, Sullia, Karnataka.*

^{4,5,6} *Junior resident, Department of ENT, Head and Neck surgery, KVG Medical College, Sullia, Karnataka.*

⁷ *Senior resident, Department of Anaesthesia and Critical care, Narayana Hrudayalaya, Bangalore.*

Abstract

Background/Objective: *Soft tick in the ear is a very common acute painful and distressing condition in the flowering months of October to March. It's a common condition in the rubber growing belt of Sullia.*

The mouthparts of the tick grips firmly the skin of the external auditory canal or the tympanic membrane and sucks blood and swells up. Otoscopy and removal of the tick from the ear can be done in outpatients in adults and difficult in a frightened irritable child.

Materials and methods: *312 cases of intra-aural ticks presenting to the opd and casualty which included 131 males and 181 females were included in the study.*

Results: *Out of the 312 cases of intra-aural ticks, 170 cases were treated in the outpatient and 140 cases under short general anesthesia with oto-microscopy.*

Conclusion: *Intra-aural tick infestation is an acute painful condition which needs prompt management by an experienced otolaryngologist. Proper visualization and instrumentation is necessary to avoid complications.*

Introduction:

Intra-aural tick infestation is a common condition seen in rubber growing population. It is a common painful condition presenting to the ENT OPD during the flowering months of October to March.¹ Animate foreign bodies are comparatively rare and inanimate foreign bodies accounts to around 84%. Majority of the animate foreign objects are small cockroaches.¹

Most of the patients present with acute severe pain in the ear.² The condition affects all age groups.² It is diagnosed by performing an otoscopic canal examination or ear endoscopy which will show the presence of tick or its blackish fecal particle.² The intense pain is because of firm gripping of the skin of the external auditory canal and the tympanic membrane by its mouthparts.²

Children and anxious adults will not cooperate for ear examination or otoscopy and forceful examination may cause damage to the external ear and tympanum.² So examination of the ear using an otoscope or oto-microscope and exact visualization of the tick is very important before attempting to remove it.² Its an acute painful condition which needs urgent intervention.² Co-operative patients can be managed in the outpatient only meanwhile anxious and pediatric patients were managed with oto-microscopy under general anaesthesia.²

Materials and methods:

A retrospective analysis of 624 patients who had intra-aural tick infestations was included in the study. 262 males and 362 females were included under the study. The youngest patient was of 3 year old girl and oldest was 79 year old woman. The study period was of 57 months from Jan 2007 to Dec 2011. All patients with intra-aural tick infestation were included in the study. All patients had excruciating pain in ear as presenting complaint. Otoscopic examination was done to confirm the animate tick foreign body.(fig 1)

Tick removal was done under 4% topical anaesthesia in co-operative adult patients in the outpatients. General anaesthesia was preferred for anxious and younger patients. Under short general anaesthesia oto-microscopy was done and the ticks removed by cupped forceps under magnification.(fig2,3) All the patients managed in OPD were observed for an hour and discharged with antibiotics and analgesics for one week. Patients managed under general

anaesthesia were observed for a day and discharged on next day with antibiotics and analgesics.(table 1)

Results:

All the ticks located on the pinna were removed in the OPD (12 males and 22 females). Out of the 240cases of ticks in the cartilaginous EAC (external auditory canal) 156 (65%) co-operated for removal in OPD and in 84 (35%) cases ticks were removed under general anaesthesia with oto-microscopy. Out of the 280 cases of ticks in the bony EAC 150 (53.57%) co-operated for removal in OPD and in 130 (46.42%) cases ticks were removed under general anaesthesia with oto-microscopy.

All ticks (70 cases) located on the tympanic membranes were removed under general anaesthesia with oto-microscopy. Here 4 females refused removal under general anaesthesia. Small perforations were seen after removal of the ticks located on the tympanic membranes in 4 males and 8females. No other complications were seen in rest of the cases.

Discussion:

Ticks are obligate blood-sucking arachnids and are easily transmitted through domestic animals and pets to humans.³ The two major types of ticks, based on the presence or absence of a hard shield called scutum, are Ixodidae (hard ticks) and Argasidae (soft ticks).⁴

Soft tick attaches to its host with its mouthpart, which not only is imbedded in the skin but is also glued into place with a cement-like secretion.⁵ The tick can voluntarily detach from its host, but when forced off, it may leave the attached mouthpart imbedded in the skin.⁵ As long as the mouthpart is attached to the patient, the patient remains at risk for tick-borne diseases.⁵ Removal of an intra-aural tick is a painful experience to patients, especially children.⁵ Most of the times, the removal is made difficult by the swollen and narrowed canal from previous multiple attempts by inexperienced medical personnel with inadequate instruments.⁵

The tick swells up after sucking blood and the engorged tick is easy to detect in narrow ear canal.² The unfed tick situated at the anterior fornix of the external ear canal is seen with difficulty on otoscopy.² The anterior bony hump of the ear canal may block the view to that particular area.² Cerumen (wax) in the canal can hinder tick visualization.² The tick stands out as a shiny surface making it conspicuous within the wax.² The dark brown color of the tick fecal matter which is digested blood might mix with the wax and create a confusing picture.² Oto-microscopy should be done to confirm the diagnosis.² A tick which is easily visualized should be grasped by a crocodile or cupped ear forceps and pulled out steadily.⁵ Rotating the tick during removal may break off the mouthparts leaving the sequelae of infection and irritation of the ear canal.⁵

Tick removal is a very painful experience to the patient because of the sensitivity of the ear canal.⁶ Patients in the pediatric age group never allow removal without anaesthesia.⁶ Swollen and narrowed ear canal due to tick bite trauma and previous attempts at removal by inexperienced medical personnel with inadequate instruments make removal even in experienced hands difficult.⁶ Always institutional management where adequate facilities and expertise are available should be sought.⁶

Ticks can be removed by manual forceps removal or by applying noxious stimuli so that the tick detaches spontaneously.⁶ Many reagents have been used to induce a noxious stimulus with varying results.⁶ Some practitioners used spirit eardrops for 3 days before syringing the tick out on day 4.⁷ Some used 4% lignocaine instead, but only instilling the canal for 10 minutes.⁸ Olive oil, sodium bicarbonate, petroleum jelly and liquid paraffin are among various preparations used to facilitate tick removal with none of them proven to be superior to another.⁸

We instilled 4% lidocaine in our patient's ear canal for 10 minutes and found that we can remove the tick easier by doing ear suction or using forceps under microscopy. Cocaine if available can be instilled which anaesthetize and disengage the tick from the tympanic membrane and also decongest the swollen canal and reducing the pain, thus calming the patient down.⁶

However, in uncooperative children, removal under general anesthesia is safer and less traumatic to the patients. The most commonly recommended and successful tick removal method is manual extraction of the tick.⁹ It is seen that the tick would best be removed by grasping it close to the skin and exerting a steady, even pressure without rotating.⁵ Another author proposed a technique of mechanical removal involving rotation instead of traction, which he claimed more reliable for rapid and painless removal of the entire tick, including the head, not leaving the mouthpart behind.¹⁰ After the removal of tick, its fecal particle should also be cleared off the ear canal since tick feces and body fluids can also be contaminated.¹⁰ Antibiotics and analgesics should be prescribed for a week to reduce secondary infection in the site of trauma.

The neurological complications of intra-aural tick infestation may occur, where they usually present as a localized manifestation such as facial nerve paralysis.⁸ Tick paralysis is a known complication of tick infestation anywhere in the body and has been reported particularly in Northern America and Australia, but was rarely encountered in this region.⁸ People from this tropic climate are more frequently exposed to tick bite and have developed some immunity to its toxin.⁸ However, cases of isolated local paralysis; usually involving facial nerve, are reported although less commonly reported in the literature.⁸

The tick salivary secretions contain a neurotoxin and the paralyzing effect of the tick is attributed to it.⁴ This toxin is found to interfere with the liberation or synthesis of acetylcholine at the motor end plate of muscle fibre.⁴ The severity of paralysis is independent of the number of tick infested.³ But a correlation between the duration of tick attachment and the likelihood of transmission of toxin or infection is reported.¹¹ several theories have been put forth to explain the pathophysiology of localized facial nerve palsy in an intra-aural tick infestation.¹¹

The presence of tympanic membrane perforation may enable the tick saliva (with toxin) to enter the middle ear and reach the facial nerve probably through a natural dehiscence of the fallopian canal causing paralysis.⁸ In cases that the tympanic membrane is intact, direct extension of the inflammatory process to the fallopian canal is via persistent dehiscence or direct invasion of the infectious organisms into the facial canal through the middle ear which results in edema of the inflamed nerve within the canal.¹²

Conclusion:

Intra-aural tick infestation is an acute painful condition which needs prompt management by an experienced otolaryngologist. Proper visualization and instrumentation is necessary to avoid complications. Facial nerve paralysis is a known complication resulting from local spread of toxin to the nerve. It usually resolves quickly after the tick is removed.

<i>location</i>		<i>no</i>	<i>OPD removal</i>	<i>Otomicroscopic removal (GA)</i>	<i>complications</i>
<i>Pinna</i>	<i>males</i>	12	12	0	0
	<i>females</i>	22	22	0	0
<i>Cartilaginous EAC</i>	<i>males</i>	98	62	36	0
	<i>females</i>	142	94	48	0
<i>Bony EAC</i>	<i>males</i>	124	92	32	0
	<i>females</i>	156	58	98	0
<i>Tympanic membrane</i>	<i>males</i>	28	0	28	4
	<i>females</i>	42	0	36	8
<i>Total (624)</i>	<i>males</i>	262	166	96	4
	<i>females</i>	362	174	184	8

Table 1: location & management of intra-aural ticks.

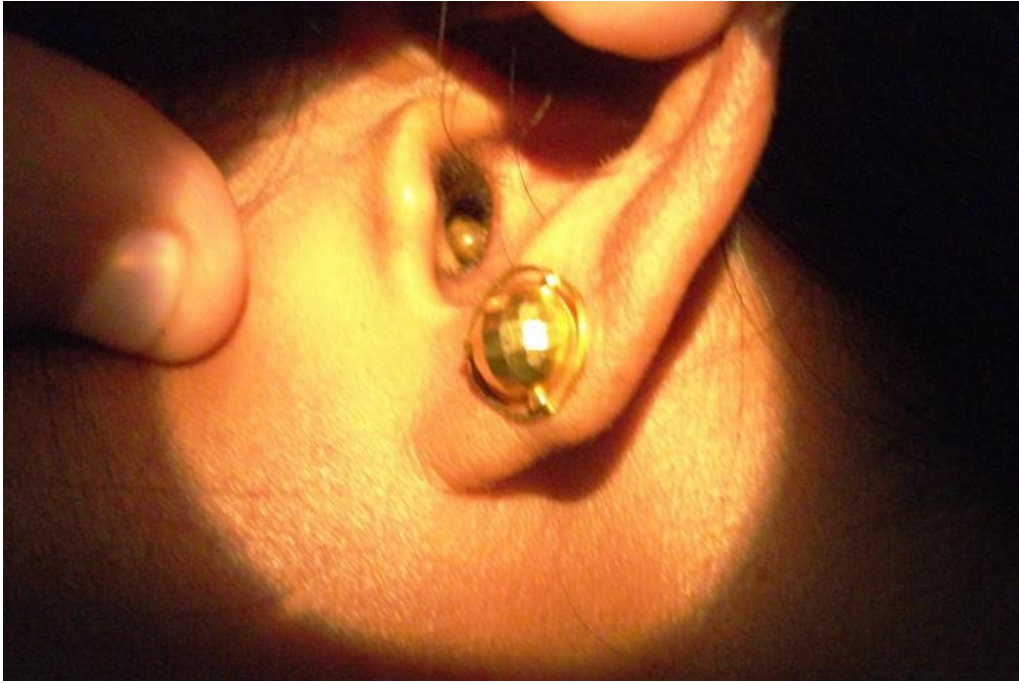

Figure 1 showing Tick in the external auditory canal

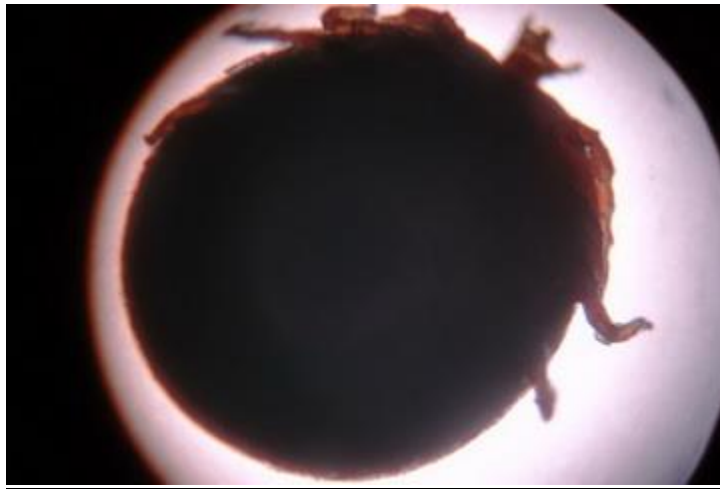


Figure 2 showing Tick on magnification



Figure 3 showing tick under low magnification

References:

1. KSG Somayaji, A Rajeshwari: Human otoacariasis: *Indian J Otolaryngol. Head Neck Surg* July-Sept 2007; 59:237-239.
2. Srinovianti N, Raja Ahmad RLA. Intra-aural tick infestation: The presentation and complications. *Intern Med J* 2003, 2(2): 21.
3. Spach DH, Liles WC, Campbell GL, Quick RE, Anderson DE, Fritsche TR . Tick-borne disease in the United States. *N Engl J Med* 1993, 329(13): 936-947.
4. Vedanarayanan V, Sorey WH, Subramony SH. Tick Paralysis. *Semin Neurol*,2004 24(2): 181-184.

5. Needham GR. Evaluation of five popular methods for tick removal. *Pediatrics* 1985, 75: 997-1002.
6. Zamzil AA, Baharudin A, Shahid H, Din Suhaimi S, Affendie MJ: Isolated facial palsy due to intra-aural tick (*ixodoidea*) infestation: *Archives of Orofacial Sciences*.2007,2,51-53.
7. Fegan D and Glennon J (1996). Intra-aural ticks in Nepal. *Lancet*, 348(9037): 1307-1322.
8. Indudharan R, Ahamad M, Ho TM, Salim R and Htun YN (1999). Human otocariasis. *Ann Trop Med Parasitol*, 93(2): 163-167.
9. Gammons M and Salam G (2002). Tick removal. *Am Fam Physician*, 66(4): 643-647.
10. Schultheis L (1998). A novel technique to remove the common dog tick. *Am Fam Physician*, 58(2): 354.
11. Sood SK, Salzman MB, Johnson BJ, Happ CM, Feig K and Carmody L (1997). Duration of tick attachment as a predictor of the risk of Lyme disease in an area in which Lyme disease is endemic. *J Infect Dis*, 175: 996-999.
12. Miller MK (2002). Massive tick (*Ixodes holocyclus*) infestation with delayed facial-nerve palsy. *Med J Aust*, 176(6): 264-265.