



**“Healing and hearing results of temporalis fascia graft Vs cartilage graft (Full thickness and half thickness) in type I tympanoplasty”**

Sanjana V. Nemade. Jyoti P. Dabholkar

Smt. Kashibai Navale Medical college and General Hospital, Pune.

**Abstract:**

**Background-** Although temporalis fascia is the commonly used graft material for tympanic membrane reconstruction, cartilage–perichondrium graft is the material of choice for the reconstruction of the atelectatic tympanic membrane, recurrent perforations, subtotal and total perforations. Stiffness of cartilage graft is always the concern for the audiological outcome of the surgery. In our study, we used temporalis fascia and the cartilage graft of different thickness and have done the honest efforts to find out the ideal graft that will form a perfect balance between the stability and the acoustic sensitivity of the tympanic membrane.

**Materials and methods:**

90 patients were included who underwent type one tympanoplasty between July 2003 to January 2006. 30 cases were included in Group A in which temporalis fascia was used. 30 cases were included in Group B in which full thickness tragal cartilage (1mm) was used and 30 cases were included in Group C in which partial thickness (0.5 mm) tragal cartilage was used. **Results:** Graft take was accomplished in 86 patients (95.5%).

The average Air-Bone gap closure achieved in Group A was 27.4 dB; in Group B was 17.5dB while in Group C it was 26.8 dB.

**Conclusion-** Cartilage of 0.5 mm thickness maintains a perfect balance between sufficient stability and adequate acoustic sensitivity. If the stability of the reconstructed membrane is a higher priority, like in chronic eustachian tube blockage, full thickness tragal cartilage can be used, although it entails some sacrifice of acoustic quality.

**Key words:** Tympanoplasty, Temporalis fascia graft , Tragal cartilage, Cartilage graft thickness , Post operative hearing gain.

## Introduction

Historically, various grafting materials have been used to reconstruct the tympanic membrane, including skin, fascia, vein, perichondrium, dura mater, and cartilage.

Presently, temporalis fascia is the most frequently used grafting material, and most series have reported approximately 90% graft take<sup>1,2</sup>. For cases at high risk for failure, such as recurrent perforations, total perforations, and severely atelectatic tympanic membranes, many surgeons have used cartilage as a grafting material because of its increased stability and resistance to negative middle ear pressure.<sup>3</sup>

Cartilage material has been criticized because of concerns regarding hearing results. The thickness and composition of cartilaginous TM should represent a compromise between sufficient stability and adequate acoustic sensitivity. Various Authors have shown that the audiologic results, following cartilage tympanoplasty are comparable to those after perichondrium or fascia grafting<sup>4,5</sup>. Assuming that replacing a large portion of the tympanic membrane with cartilage would add stiffness and mass, Gerber et al. compared the cartilage to temporalis fascia in a frequency-specific manner and again no significant difference was observed<sup>5</sup> This study aimed to evaluate the anatomical and audiological outcomes of type one tympanoplasty performed with a temporalis fascia and tragal cartilage of two different thickness.

## **Materials and methods**

90 patients who underwent type one tympanoplasty at our institute from July 2003 to January 2006 were prospectively reviewed. Data collected of each patient included- Age, Gender, Previous otologic surgery, Preoperative pure tone audiometry, Indication for surgery, Surgical data and Postoperative clinical findings and pure tone audiometry.

### **Inclusion criteria:**

- \* Primary tympanoplasty cases with central perforation.
- \* Primary tympanoplasty cases with subtotal ((perforation >50% of the whole TM area), or total perforation .
- \* Revision Tympanoplasty.

In all cases the ear was dry and with normal middle ear mucosa for at least one month prior to surgery. There was no history of previous mastoid surgery. Eustachian tube patency was judged by asking the patient the history of ear drops coming in throat.

### **Exclusion Criteria:**

History of previous mastoid surgery, discharging ear, cases requiring ossicular reconstruction, cholesteatoma.

An underlay type one tympanoplasty ( primary or revision) , using temporalis fascia, tragal cartilage of two different thickness was performed. 30 cases were included in Group A in which temporalis fascia was used. 30 cases were included in Group B in which full thickness tragal cartilage (1mm) was used and 30 cases were included in Group C in which partial thickness (0.5 mm) tragal cartilage was used.

All procedures were performed by the same surgeon. A successful anatomical Outcome was considered to comprise full, intact healing of the graft without perforation, retraction, lateralisation or blunting, for at least 3 years post-operatively and with Improvement of hearing. All patients were followed up for 5 years after surgery. Graft take was evaluated in all patients and postoperative complications were noted. Average preoperative Air-Bone gap, postoperative Air-Bone gap and the Air-Bone gap closure in dB at 500 Hz, 1000 Hz, 2000 Hz was noted.

For the statistical analysis, we compared the anatomical and audiological findings in the groups as follows-

1. Group A with Group B.
2. Group A with Group C
3. Group B with Group C

We applied 3x3 chi-square test with Pearson's method for comparing the continuous variables in three groups. Mean, standard deviation (SD) and the standard error of deviation was calculated for the average Air-Bone gap closure at different speech frequencies i.e. 500Hz, 1000Hz and 2000Hz. The 2-Tailed T-test was applied to find out statistically significant difference between the means of two groups.

To compare the graft take up rate, the 3x3 Chi square test with Pearson's method and 2-tailed Fishers exact probability test was applied. P value < 0.05 was considered as statistically significant.

## **Technique**

A post-auricular approach was used under general anaesthesia supplemented with local infiltration of 2% Xylocain with 1: 2,00,000 adrenaline. Posterior meatotomy was done. The edges of the perforation were scrupulously denuded to promote good capillary blood flow (Fig.1). Vascular stripe incision was taken and posterior tympanomeatal flap was elevated. The middle ear was exposed. For Group A patients( n=30) ,temporalis fascia graft was harvested. For patients in Group B and C ( n= 30 each) ,the tragal cartilage was harvested together with the perichondrium after making incision on the medial part of the tragus (Fig. 2). A lateral cartilaginous bridge of about 2 mm was left for aesthetic reasons. This cartilage is ideal since it is thin, flat and is in sufficient quantities to permit reconstruction of the entire tympanic membrane. Typically, the piece of cartilage is 15 mm in length, 10 mm in width and 1 mm in thickness (Fig.3). The perichondrium was dissected from both sides and was thinned with a hand press while the cartilage was sized and shaped properly to entirely replace the tympanic membrane. In 30 cases, we used full thickness of tragal cartilage (1mm) and in another 30 cases we sliced it to 0.5 mm thickness with cartilage knife. A V-shaped notch was removed from the cartilage shield to accommodate the malleus handle. The middle ear space was packed with gelfoam. The cartilage graft was placed on the same plane as the manubrium of the malleus and medial to tympanic membrane remnants or the fibrous annulus. It has been

shown that incorporation of the malleus, in the graft, offers an acoustic gain <sup>8</sup>. The tragal perichondrium was placed lateral to the cartilage and medial to the edges of the perforation and extended posteriorly onto the canal wall (underlay technique) (Fig.4). The vascular stripe was returned to its original position. Gelfoam was placed over the graft for stabilization. The post-auricular incision was closed in two layers and mastoid dressing was applied.

**Post-operative care:**

Patients were given water precautions and cautioned against vigorous nose blowing. Suture removal was done one week after surgery and the gelfoam was suctioned from the ear canal 3 weeks post-operatively. Antibiotic steroid-containing drops were used for a further 2 weeks to clear the ear of residual gelfoam which can lead to granulation and fibrous tissue formation if not completely removed from the tympanic membrane. An audiogram was performed 2 months after surgery and the tympanic membrane was examined. In case of good hearing result and the clear tympanic membrane, the ear was examined at 6 months and, thereafter, every year for 5 years (Fig.5).

## Results

90 patients underwent type one tympanoplasty over the study period. The ratio of males to females was 67: 23. Patients' age ranged from 18 to 52 years, with a mean age of 45.5 years; 30 cases were included in Group A in which temporalis fascia graft was used. 30 cases were in Group B in which full thickness tragal cartilage (1mm) was used. Group C included 30 cases in which partial thickness (0.5 mm) tragal cartilage was used. The clinical characteristics of the 3 groups are summarized in Table-I.

In Group A, the preoperative average Air-Bone gap in speech frequencies (500Hz, 1000Hz, 2000 Hz) was 44.0 dB and the post-operative average Air-Bone gap was 16.6 dB. Average Air-Bone Gap closure (dB) achieved was 27.4 dB.(Table-II)

In Group B, the preoperative average Air-Bone gap in speech frequencies (500Hz, 1000Hz, 2000 Hz) was 42.2 dB and the post-operative average Air-Bone gap was 24.7 dB. Average Air-Bone Gap closure (dB) achieved was 17.5 dB.(Table-III)

In Group C, the preoperative average Air-Bone gap in speech frequencies (500Hz, 1000Hz, 2000 Hz) was 49.3 dB and the post-operative average Air-Bone gap was 22.5 dB. Average Air-Bone Gap closure (dB) achieved was 26.8 dB.(Table-IV)

We compared the groups as-

1. Group A with Group B.
2. Group A with Group C
3. Group B with Group C

The 2 Tail T-test was applied for comparison in the air –bone gap closure achieved in the two groups.



For Group A and B, 2 Tail T-test value was 19.584 at 100% of actual confidence level and 40 degrees of freedom. Statistically significant difference was noted in Air-Bone gap closure of two groups (Table-V).

For Group A and C, 2 Tail T-test value was 1.4116 at 83.42% of actual confidence level and 40 degrees of freedom. Statistically no significant difference was noted in Air-Bone gap closure of two groups (Table-VI).

For Group B and C, 2 Tail T-test value was 26.642 at 100% of actual confidence level and 42 degrees of freedom. Statistically significant difference was noted in Air-Bone gap closure of two groups (Table-VII).

Table-VIII shows the comparison of graft take up rate in all groups. Well taken up graft was found in 28 of 30 patients in group A. In group B, 28 patients of 30 had well taken up graft. In Group C, all 30 patients had well taken up graft.  $3 \times 3$  Chi-square test with Pearson's method showed chi square value- 1.9786 with 4 degrees of freedom. Two tailed P value was 0.7397. With Fisher's exact probability test, two tailed P value was 0.8239. Statistically no significant difference was noted in the graft take rate in three groups.

There was no immediate post-operative complication such as wound infection, hematoma, sensorineural hearing loss or facial nerve injury.

## Discussion

The Tympanic Membrane (TM) plays a significant role in the physiology of hearing as well as in the pathophysiology of chronic inflammatory middle ear diseases. The TM perforations significantly impair the quality of life for millions of patients.<sup>6</sup> There are a number of materials for closure of TM perforations like skin,<sup>7</sup> perichondrium,<sup>8,9</sup> vein,<sup>10</sup> temporalis fascia,<sup>11</sup> dura<sup>12</sup> and cartilage.<sup>5,13</sup> The most frequently used technique for the repair of tympanic membrane perforations is underlay grafting of temporalis fascia.

Advantages of temporalis fascia graft: <sup>14</sup>

1. Easily available in sufficient quantity
2. Separate incision not required
3. Adequately firm
4. Thickness similar to TM
5. Low basal metabolic rate.

Disadvantages of temporalis fascia graft: <sup>14</sup>

1. If it is not denuded properly of the muscles, then oxygen and the metabolic requirement increases and the graft may fail.
2. In revision cases, adequate graft maybe difficult to obtain.
3. Graft retraction
4. Graft medialization in cases of eustachian tube dysfunction.

In the cases of subtotal and total perforations, atelectatic ear, retraction pocket, long term results of temporalis fascia graft may not be very satisfactory.<sup>15,16</sup> To overcome this, perichondrium and/or cartilage grafts are used with good results. Cartilage was first used in middle ear surgery for ossicular chain reconstruction in 1958 by Jansen. In 1963, Salen<sup>17</sup>

and Jansen<sup>18</sup> first reported the use of cartilage composite grafts for tympanic membrane reconstruction. Since the first description of tympanoplasty, clinicians have attempted to reduce the frequency of complications such as recurrent tympanic membrane retraction and cholesteatoma.<sup>19</sup>

Cartilage contributes minimally to an inflammatory tissue reaction and is well incorporated with tympanic membrane layers; it also provides firm support to prevent retraction. The greatest advantage of the cartilage graft has been thought to be its very low metabolic rate. It receives its nutrients by diffusion, is easy to work with because it is pliable, and it can resist deformation from pressure variations.<sup>20</sup> Perichondrium and cartilage share with fascia the quality of being mesenchymal tissue, but they are thicker and stiffer. They mechanically reduce the vibratory pattern of the tympanic membrane, contributing to some impairment in functional results, especially in the higher tones.<sup>20</sup>

Four techniques have been described for cartilage tympanoplasty, namely the Inlay butterfly graft, Perichondrium/cartilage island flap, palisade flap, and cartilage shield tympanoplasty. The choice of technique is dictated by surgeon's preference, size of the perforation, integrity of the ossicular chain, and the presence of cholesteatoma<sup>3</sup> In our study, we used cartilage shield technique for type one tympanoplasty using tragal cartilage of two different thickness ( 1mm,0.5 mm) .

The grafts whose material properties ( mass, stiffness,damping) differ significantly from the properties of TM can alter the impedance of the TM and contribute to acoustic transmission losses. Cartilage may be used as full thickness graft or may be split into thinner plates or palisades for the treatment of tubal ventilation problems, adhesive process, tympanic fibrosis. A soft membrane that vibrates easily in response to acoustic energy will

offer very little resistance to static pressure. Conversely a thick cartilage disk has excellent stability but will reflect most of the incoming sound. The elastic modulus of various graft materials has been determined in mechanical traction experiments. The higher the E-modulus, the stiffer the material. Table-IX shows the comparison giving information on the stiffness of different materials having same thickness. Fascia and perichondrium are considerably softer than the tympanic membrane. So when these materials are used to graft large area of tympanic membrane, the reconstructed membrane is likely to become unstable in response to static pressure load. This can lead to membrane retraction if eustachian tube function is impaired. While cartilage has smaller E-modulus than tympanic membrane, this softness is apparent only when the thickness of the graft is comparable to that of tympanic membrane i.e. 100  $\mu\text{m}$  (0.1 mm). In practice, cartilage is always thicker, giving it greater overall stiffness than thin tympanic membrane. Its compliance to atmospheric pressure is then dependent on its thickness. Cartilage disk thickness of 500 $\mu\text{m}$  (0.5 mm) has E-modulus similar to that of tympanic membrane <sup>21</sup>.

Overbosch in 1971 was first to describe a microslice technique to improve the acoustic properties of the reconstructed tympanic membrane. He cut the cartilage by a dermatome into plates with thickness of 0.2-1mm.<sup>22</sup> According to Zahnert's experimental study, cartilage slices <500  $\mu\text{m}$  thick are similar to the tympanic membrane in terms of their acoustic properties. They reported that when the large tympanic membrane defects are reconstructed with thick pieces of cartilage, transmission losses occurred at lower frequencies.<sup>23</sup> The thicker disk has higher stiffness than tympanic membrane. In normal/partially ventilated middle ear, thickness up to 0.5 mm gives sufficient mechanical stability

and low acoustic transfer loss, but in cases of atelectatic ears due to chronic Eustachian tube dysfunction, disk >0.5 mm thickness should provide a more stable reconstruction.<sup>21,23</sup>

In complex mechanical properties of tympanic membrane, at very low pressure loads, that are within the range of acoustic pressures, the motion pattern of tympanic membrane is similar to that of fascia and perichondrium, but as the pressure load increases, entering the range of atmospheric pressure, tympanic membrane does not undergo further stretching like fascia and perichondrium but becomes stiffer and behaves much like a rigid wall. Thus atmospheric pressure changes do not lead to unlimited displacement of tympanic membrane. In contrast, fascia and perichondrium offer no resistance to rising pressure. Thus cartilage appears to be well suited to tympanic membrane reconstruction from the standpoint of its acoustic and mechanical properties<sup>21</sup>. The thickness and composition of cartilaginous tympanic membrane should represent a compromise between sufficient stability and adequate acoustic sensitivity.

In our study, when we compared the temporalis fascia with cartilage of 0.5 cm thickness, we found no statistically significant difference in the graft take rate as well as hearing gain. (Table-VI). But with full thickness cartilage, though the graft take up rate is comparable to that of temporalis fascia and the partial thickness cartilage graft, hearing gain is significantly less (Table-V and Table-VII). Thus the cartilage graft of 0.5 cm thickness offers the best balance between the stability and the acoustic sensitivity.

## **Conclusion**

Cartilage–perichondrium graft is experiencing a renaissance in ear surgery for reconstruction of the tympanic membrane in case of high risk perforations( subtotal, total and revision) and atelectatic tympanic membrane.

The rigidity of the cartilage graft has benefits in reducing retraction of the tympanic membrane; however, concerns that the stiffness and mass of cartilage may adversely affect hearing, still hesitates an otologist for its use. As we exposed, cartilage is an excellent grafting material because it is easily accessible, easy to adapt, resistant to negative middle ear pressures, stable, elastic, well tolerated by the middle ear, resistant to resorption and with high graft take rate. Furthermore, cartilage graft of 0.5 mm thickness offers the best balance between the stability and the acoustic sensitivity.

## References

1. Dornhoffer J. Cartilage Tympanoplasty: Indications, techniques and outcomes in 1000 patient series. *Laryngoscope* 2003; 113: 1844-56.
2. Murbe D, Zahnert T, Bornitz M., Huttenbrink KB, Acoustic properties of different cartilage reconstruction techniques of the tympanic membrane. *Laryngoscope* 2002; 112: 1769-76.
3. Ioannis Aidonis, Thomas C. Robertson, and Aristides Sismanis. Cartilage Shield Tympanoplasty: A Reliable Technique. *Otology and Neurotology* 2005, 26;838-841.
4. Dornhoffer JL. Hearing results with cartilage tympanoplasty. *Laryngoscope* 1997;107:1094-9.
5. Gerber MJ, Mason JC, Lambert PR. Hearing results after primary cartilage tympanoplasty. *Laryngoscope* 2000; 110:1994-9.
6. Anisur Rahman. Healing of tympanic membrane perforation : an experimental study from Karolinska Institute And University Hospital Stockhole Sweden 2007, ISBN 978-91-7357-243-9.
7. Berthold E. Uber Myringoplastic. *Med-chir centralb.* 1879; 14: 195-207
8. Goodhill V. Articulated polyethylene prosthesis with perichondrial graft in stapedectomy. *Rev Laryngol(Bordeaux)* 1951;82:305-320.
9. Linde RE. The cartilage-perichondrium graft in the treatment of posterior tympanic membrane retraction pockets. *Laryngoscope* 1973;83:747-53
10. Tabb HG. Closure of perforations of the tympanic membrane by vein grafts: a preliminary report of 20 cases. *Laryngoscope* 1960;70:271-286.
11. Storrs L. Myringoplasty with the use of Fascia Grafts. *Arch Otolaryngol* 1961;74:45-49.

12. Yetiser S, Tosun F, Satar B. Revision myringoplasty with solvent-dehydrated human dura mater. *Otolaryngol Head Neck Surg.* 2001 May;124(5):518-21.
13. Couloigner V, Baculard F, El Bakkouri W, Viala P, Francois M, Narcy P et al. Inlay butterfly cartilage tympanoplasty in children. *Otol Neurotol* 2005;26:247 –51
14. Sunil S Nichlani et al. Reconstruction of the Tympanic Membrane with Partial Tragal cartilage Graft Versus Temporalis Fascia Graft. *Bombay Hospital Journal*, vol.52, No.2, 2010
15. Anderson J, Caye-Thomasen P, Tos M. A comparison of cartilage palisades and fascia in tympanoplasty after surgery for sinus or tensa retraction cholesteatoma in children. *Otol Neurotol* 2004;25:856–63
16. Gierek T, Slaska-Kaspera A, Majzel K, Klimczak-Gotqbm L. Results of myringoplasty and type I tympanoplasty with the use of fascia, cartilage and perichondrium grafts [in Polish]. *Otolaryngologia Polska* 2004;3:529–33
17. Salen B. Myringoplasty using septum cartilage. *Acta Otolaryngol* 1963;Suppl 188:8291
18. Jansen C. Cartilage–tympanoplasty. *Laryngoscope* 1963;73: 1288-1302.
19. Buckingham RA. Fascia and perichondrium atrophy in tympanoplasty and recurrent middle ear atelectasis. *Ann Otol Rhinol Laryngol* 1992;101:755-758.
20. M YUNG Cartilage tympanoplasty: literature review. *The Journal of Laryngology &*



Otology (2008), 122, 663–672.

21. Klaus Jahnke. Middle ear surgery: Recent advances and future directions.

2004. Georg Thieme Verlag ; Chapter 2- Biomechanical Aspects of middle ear reconstruction- K.B. Hottenbrink. Pg.30-32.

22. Overbosch HC. Homograft myringoplasty with microsliced septal cartilage.

Otolaryngol 1971; 33:356-7.

23. Zahnert T, Hüttenbrink K, Mürbe D, Bornitz M. Experimental investigations of the use of cartilage in tympanic membrane reconstruction. Am J Otol 2000; 21: 322-8.

**Figures:**

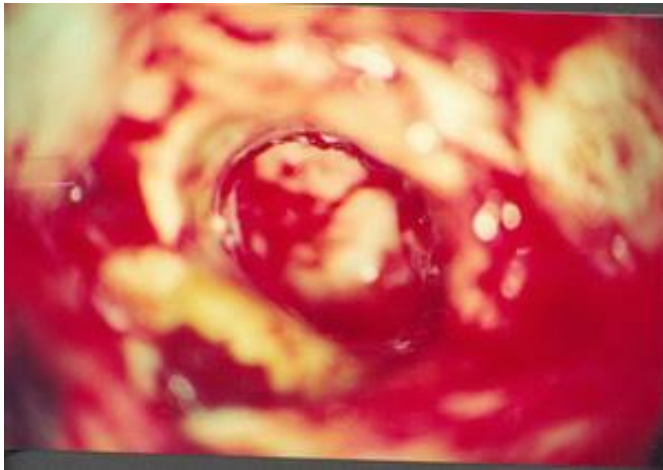


Fig.1- Perforation of the tympanic membrane.

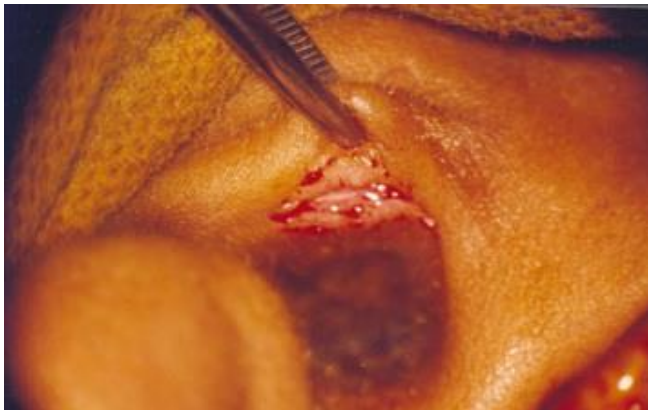

Fig.2- Incision taken for harvesting the tragal cartilage.

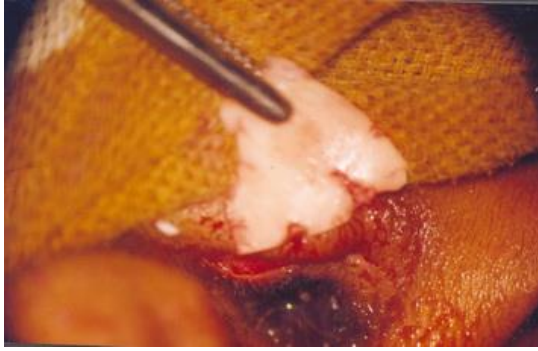

Fig.3- Tragal cartilage graft harvested.

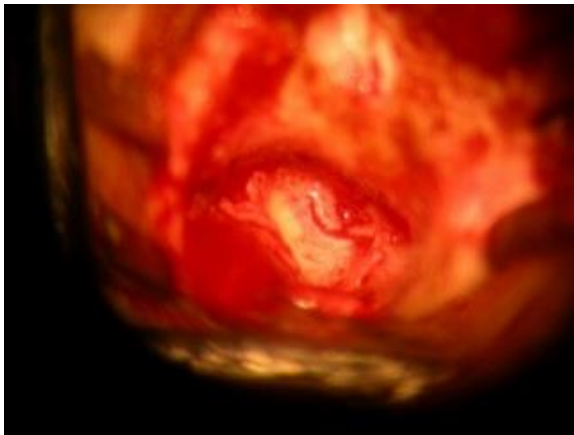


Fig.4- Cartilage graft underlaid to cover the perforation.

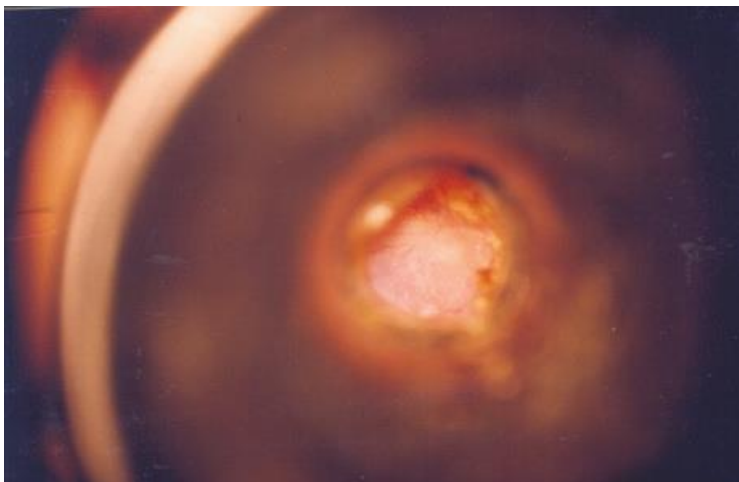


Fig. 5- Cartilage graft accepted.

