



Giant Parapharyngeal Lipoma Mimicking Parotid Tumor

Nitish Baisakhiya*, Ginni Dutta, Dalbir singh, Vandana

Department of ENT, Maharishi Markandeshwar institute of Medical sciences and research
Mullana, Ambala, Haryana.

*Corresponding author: Nitish Baisakhiya, Department of ENT, Maharishi Markandeshwar
institute of Medical sciences and research Mullana, Ambala, Haryana; E-mail: nitish.
baisakhiya@gmail. com

Received: April 06, 2016; **Accepted:** April 08, 2016; **Published:** April 11, 2016

ABSTRACT

Lipoma is a rare tumor to be present in the parapharyngeal space. Clinical examination of tumors present in this region is difficult due to its Anatomical location. Modern radiological modalities are the investigation of choice to diagnose and access these tumors. We are reporting a case of large parapharyngeal space Lipoma mimicking parotid tumor. He was clinically asymptomatic and reported for cosmetic purpose only.

Keywords: Lipoma, Parapharyngeal space, parotid tumor

Introduction:

Lipoma is a common mesenchymal tumor present in the body but rare to be reported in the Head neck region especially in parapharyngeal space. They are commonly present in the subcutaneous tissue. Parapharyngeal space is the rare site for its occurrence. Symptoms are mainly depending upon the site, size and involvement of adjacent structure. Parapharyngeal space is clinically not accessible which allow this to grow asymptotically. Presence of pain, neurological deficit and trismus are the features of its malignant conversion. CT scan, MRI and rarely angiography are the investigation of choice for its evaluation. Surgery is only way to treat this condition.

Case report:

A 45 year male presented with a swelling on the left side of the neck and infra-auricular region since

1 year. There was no history of dysphagia, change in voice, odynophagia, pain over the swelling, toothache, trismus, trauma and facial asymmetry. On examination there was soft to firm swelling about a size of about 6 × 10 cm extending suprioinferiorly (SI) from parotid region to the thyroid notch and posterior part of the Submandibular region to the anterior border of sternocleidomastoid muscle in the anterioposterior (AP) direction. Rest of the ENT and neurological examinations were within normal limits. CT scan was showing a well defined lobulated non-enhancing hypodense (CT value -135 to -117 HU) mass lesion seen in left parapharyngeal space extending into the superficial and deep part of parotid gland measuring about 5.2(AP) X2.7 (ML) X9.0 (SI) cms (Figures 1 and 2). Lesion was extending inferiorly up to thyroid cartilage and superiorly up to C1 vertebrae. Medially it was displacing carotid vessels without involving it. No area of calcification was seen within it. Features were suggestive large parapharyngeal Lipoma and confirmed by FNAC. It was surgically managed by transparotid approach. Tumor was dissected all around from the parotid gland, carotid vessels and removed in toto by blunt dissection. Post-operatively there was no neurological deficit. He is doing in the regular follow-ups up to 9 months.

Discussion:

Parapharyngeal tumors are commonly benign and constitute about 1% of the head neck tumors¹.

They may take origin from its content (salivary

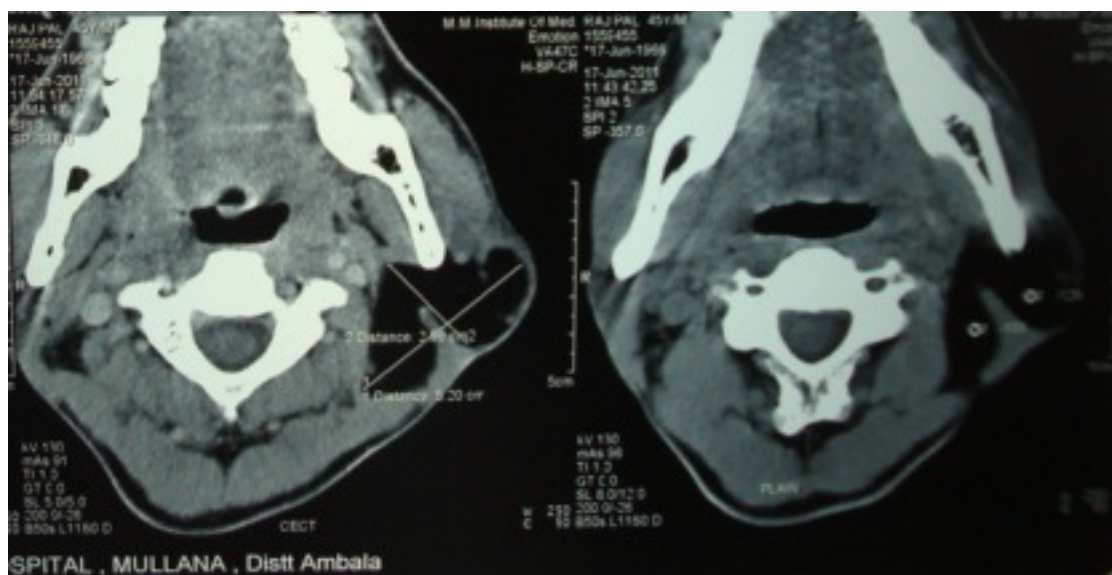


Figure 1: CT scan showing a well defined lobulated non-enhancing hypodense mass lesion seen in left parapharyngeal space.

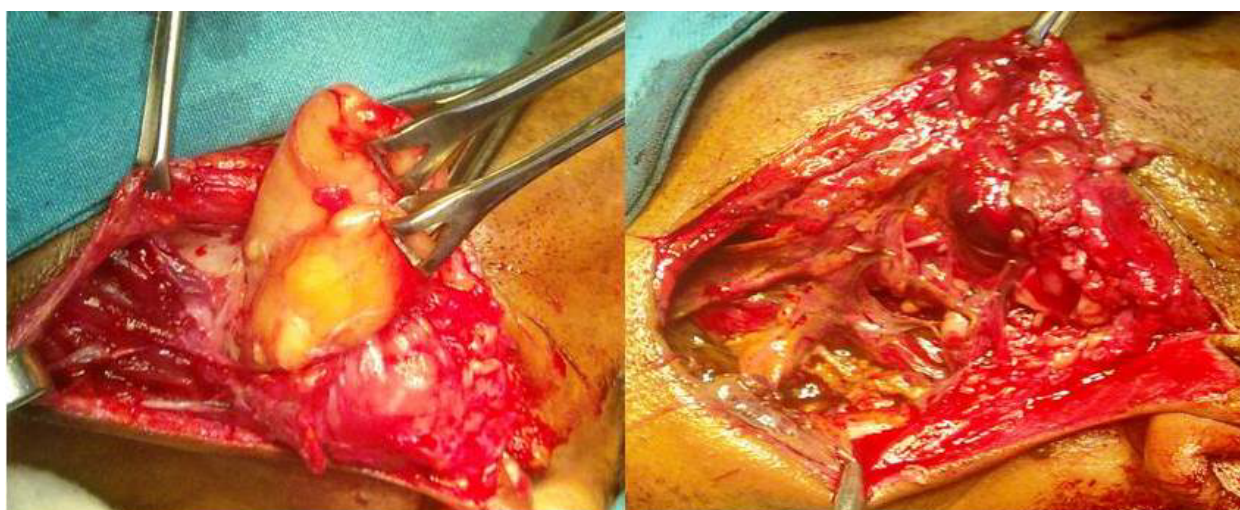


Figure 2: Itra-operative photograph showing the tumor and after excision.

gland, nerve sheath) or being involved or invaded by adjacent tumors (deep lobe of parotid). Lipoma involving this space is extremely rare². They take origin from the adipose tissue which is present commonly in the body³. This tissue present in both superficial and deep compartments which make there occurrence in anywhere in the body. They are commonly present in posterior part of the neck. Histopathologically they are characterize by adipose tissue cells separated by fibrous trabeculae⁴. This feature can differentiate it with normal lipomatosis which lack fibrous trabeculae. Most of the tumors are asypmtomatic⁵. Symptoms is present when the increase in size and pressing surrounding structure. Symptoms include neck mass, dysphagia, pharyngeal mass, lower cranial nerve pals. Patient may report for the cosmetic purpose only as in present case.

Clinically they be confused with parotid tumor due to there anatomical proximity to the deep lobe of parotid. They may be present in the prestyloid or poststyloid compartment of the parapharyngeal space. Presence of abnormal symptoms like pain, lower cranial nerve palsy, trismus and hearing loss is suggestive of malignancy⁶. Liposarcoma, metastasis and Lymphoma are the common malignancy in this space. Lipoma showed the characteristic features on CT⁷. It appears low density areas with no contrast enhancement. MRI is more sensitive because of its superior soft tissue contrast. Multiplan MRI clearly demonstrates tumor and its relation with surrounding neurovascular bundle⁸. Surgery is the treatment of choice. Parapharyngeal space can be approach by transoral, transcervical, transparotid, transcervical-transmandibular, and lateral skull base rout⁹. Surgical

approach depends on the location; size, vascularity, and malignant potential of the tumor. Post-operative complications are very few and only occur during removal of malignant or neurogenic tumors. Lower cranial nerves palsy is the common complication¹⁰.

References:

1. Batsakis JG, Sneige N (1989) Parapharyngeal and retropharyngeal space masses. *Ann Otol rhinol Laryngol* 98: 320-321.
2. Higashi K, Sarashina N, Okamoto T (1992) Supernumerary ring marker chromosome as a secondary rearrangement in a parapharyngeal lipoma. *Cancer Genetics and Cytogenetics* 64: 163-165.
3. Atsunobu T (1994) Lipoma in the peri-tonsillar space. *J Laryngol Otol* 108: 693-695.
4. Barnes L (1985) In: *Surgical Pathology of Head and Neck*. Vol. 1. New York: Marcel Dekker Inc Tumours and tumour-like lesions in head and neck 747-758.
5. Shoss SM, Donovan DT, Alford BR (1985) Tumors of the parapharyngeal space. *Arch Otolaryngol* 111: 753-757.
6. Stell PM, Mansfield AO, Stoney PJ (1985) Surgical approaches to tumors of the parapharyngeal space. *Am J Otolaryngol* 6: 92-97.
7. Scott RF, Collins MM, Wilson JA (1999) Parapharyngeal Lipoma. *Journal of Laryngology and Otology* 113: 935-937.
8. Miller FR, Wanamaker JR, Lavertu P, Wood BG (1996) Magnetic resonance imaging and the management of parapharyngeal space tumors. *Head Neck* 18: 67-77.
9. Carrau RL, Meyers EN, Johnson JT (1990) Management of tumors arising in the parapharyngeal space. *Laryngoscope* 100: 583-589.
10. Malone JP, Agrawal A, Schuller DE (2001) Safety and efficacy of transcervical resection of parapharyngeal space neoplasms. *Ann Otol Rhinol Laryngol* 110: 1093-1098.