



GIANT CYSTIC HYGROMA COLLI IN AN ADULT- A RARE CASE REPORT

INTRODUCTION

Cystic hygroma (lymphangioma) is often a benign congenital malformation of the lymphatic system that occurs as a result of sequestration or obstruction of lymphatic vessels. These lesions are usually discovered in infant or children younger than two years of age. Occurrence in adults is uncommon, and fewer than 100 cases of adult lymphangioma have been reported in the literature ^(1,2) . The objectives of this case report are to present the clinical history and surgical findings, review of literature and the unique problems encountered in the surgical management of this particular patient

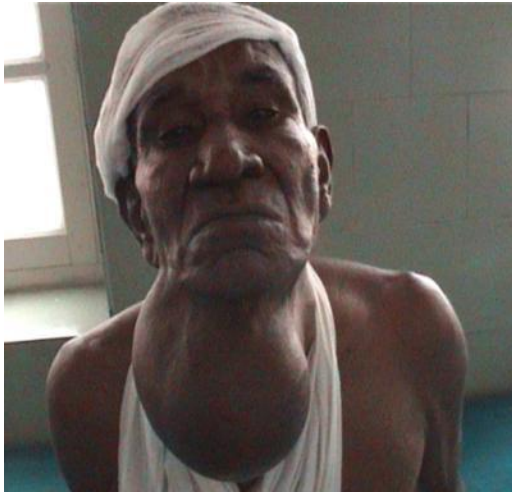Case report

HISTORY

A 75 yr old south Indian male, an agricultural labourer presented in our OPD with complaints of swelling in the neck of 2 years duration. It was slowly increasing in size and posed a restriction to neck movements. He had no complaints regarding his voice or deglutition..

He was particularly alarmed and concerned about the fact that following aspiration of the swelling a couple of weeks ago by a private practitioner the swelling had reappeared with increased vigour and attained its original size. He was not a diabetic and had no history of trauma or respiratory tract infection in the recent relevant past.

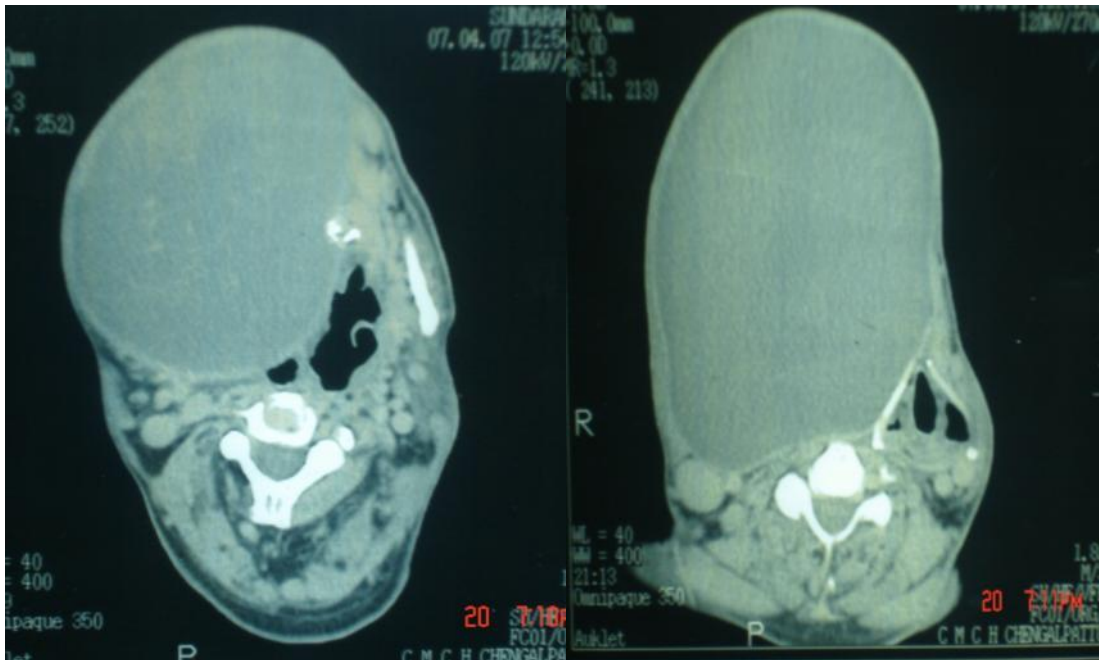
Physical examination revealed a diffuse, smooth, soft fluctuant non transilluminant swelling measuring 20 /18 cm which occupied the whole of the anterior neck pushing the right sternocleidomastoid muscle and carotid laterally. The swelling was predominantly present over the right side and encompassed the submandibular, carotid, muscular and posterior triangles on the right side. Indirect laryngeal examination revealed normal mobile vocal cords.

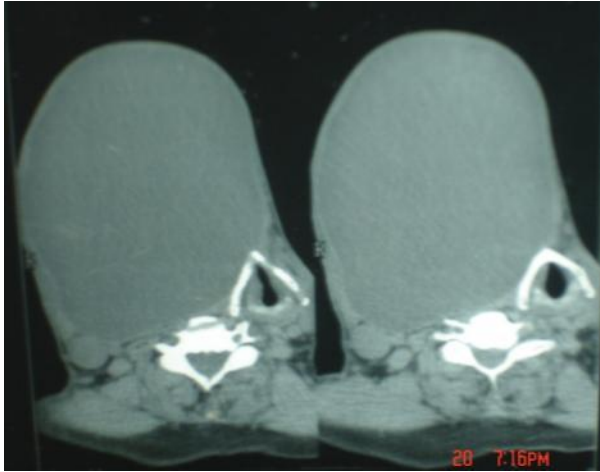


On the left side it did not cross lateral to the sternomastoid muscle .the larynx and trachea were not palpable in the midline and were pushed far to the left and were palpable along the lateral border of the neck on the left. The left carotid was palpable in normal position and was not displaced. A presumptive diagnosis of a cystic hygroma was made and investigations were carried out.

IMAGING

The contrast enhanced CT of the neck revealed a non enhancing, homogeneous soft tissue mass in the neck extending from the submandibular region to the supraclavicular fossa. The airway was pushed to the left and there was no retrosternal extension of the lesion. There was normal enhancement of the great vessels and were normal except for the lateral displacement,

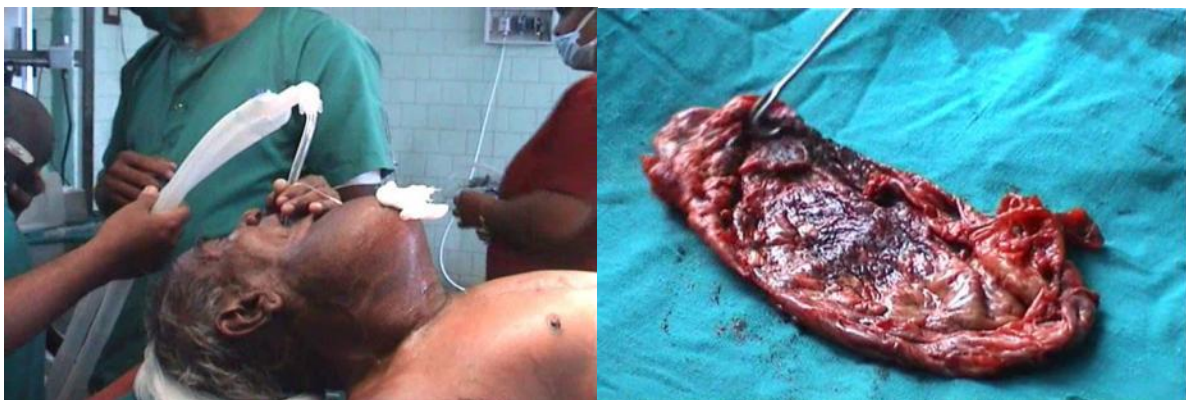



Aspiration revealed serosanguinous fluid with normal epithelial cells and a few inflammatory cells. No malignant cells were seen.

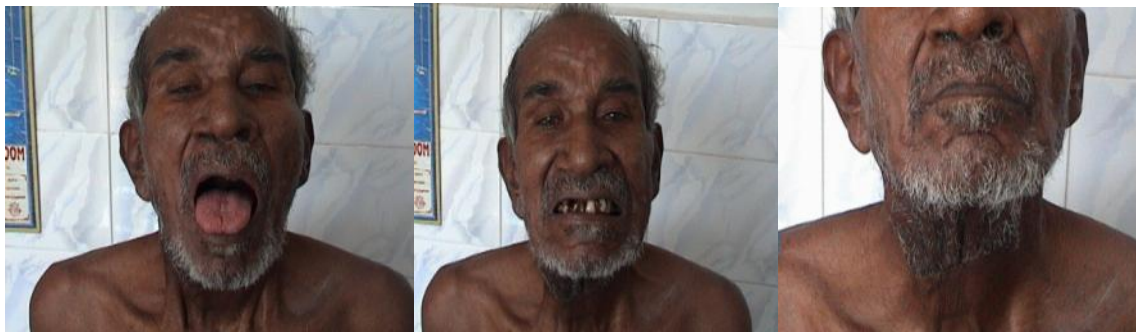SURGICAL TECHNIQUE.

This case posed unique problems because of the deviated airway. Intubation was done blindly over a bougie with a cuffed size 8 endotracheal tube. A transverse skin crease incision was made 5 cms above the suprasternal notch. Subcutaneous tissue was dissected and the platysma incised. The anterior jugular veins were encountered and ligated on both sides. The strap muscles were found to be stretched and thinned out over the swelling. While opening the strap muscles the swelling was inadvertently punctured and about 2 litres of serosanguinous fluid was let out. The cyst wall found to be thickened and contained follicles on the inner secretory surface. The cyst wall was completely dissected in toto from the surrounding structures and was found to be slightly adherent to the thyroid and cricoid cartilage. However a plane of cleavage allowed complete dissection from the cartilage. The hypoglossal nerve was encountered on the right during dissection and was preserved. There was no injury to any of the neurovascular structures of the neck. The excessively stretched out skin was trimmed and the wound was closed in layers with a drain.



There was a serous collection in the drain which continued for three days and eventually stopped. Tight compression dressing was made to avoid recollection. The patient was

discharged on the 10th day without any complications. It has been one year following surgery and patient has had no recurrent swelling.



HISTOPATHOLOGY

Histopathologic diagnosis was cystic lymphangioma which was supported with a thick fibrous wall, containing dilated blood vessels partly filled with erythrocytes and infiltrated with lymphocytes

DISCUSSION.

Cystic hygroma or giant lymphangioma is a benign malformation of the lymphatic system. It is believed to arise from a congenital malformation of the lymphatic system in which a failure of communication between the lymphatic and venous pathways leads to lymph accumulation¹. Most cystic hygromas present in-utero or in infancy and therefore most of the literature on management considers paediatric cases. The effect of these lesions depends on their position and relationship to surrounding structures, Although the lesion can occur anywhere, the most common sites are in the posterior triangle of the neck (75%), axilla (20%), mediastinum (5%), groin, retroperitoneal space and pelvis². To date there have been fewer than 150 reports of adult cervicofacial cystic hygroma in the English language literature and the optimum management of these lesions is still a matter of debate.. Thirty-two patients with cervical lymphangioma were treated at the Mayo Clinic; this is the largest series of the literature³. However, rapid enlargement over a short period of time has frequently been reported³ and major structures such as the larynx, trachea, oesophagus, brachial plexus and great vessels have known to be compressed or incorporated within the lesion. .. Diagnosis in adults is considered to present a greater challenge than in children and initial misdiagnosis, frequently as branchial cleft cysts¹

There are three histological subtype. Capillary lymphangioma (composed of small lymphatics), cavernous lymphangioma (composed of larger lymphatics), cystic lymphangioma (cystic hygroma- composed of large macroscopic lymphatic spaces with collagen and smooth muscle)¹. Cavernous lymphangioma is the most common subtype. But cystic lymphangioma occurs approximately 1 in 12000 births and 95% occurring by the second year of life¹.

Cystic hygroma could be classified into septated (multiloculated) or non-septated single cavity (non-loculated). Presentation in adulthood is rare and the cause is uncertain, although

trauma and upper respiratory tract infection have both been suggested as possible triggers for onset^[5,6]. In this case there was no identifiable cause and onset was sudden

Proposal for staging of lymphatic malformations of the head
and neck (adapted from de Serres[8])

Stage Location of lesion

I Unilateral infrahyoid

II Unilateral suprahyoid

III Unilateral infrahyoid and suprahyoid

IV Bilateral suprahyoid

V Bilateral infrahyoid and suprahyoid

Our case belonged to stage v

Complete surgical excision has traditionally been considered the treatment of choice for cystic hygroma^[6]. However, several authors have suggested that sclerotherapy may be a more appropriate first-line therapy^[7]. Although sclerotherapy is now well established in the treatment of neonatal and paediatric cystic hygromas, there have been relatively few cases reported of its use in adult patients. Some success has been reported in small numbers of adults with sclerotherapy agents such as OK-432^[7]. Caution has been urged with the use of agents such as OK-432 which induce a local immune response that often results in a rapid temporary increase in the size of the cystic hygroma^[7]. Depending on the anatomical relations of the tumour, such increases in size may be intolerable and it has been suggested that such therapy should only be administered in specialised facilities due to the risk of airway obstruction^[9]

.Smith et al^[7] compared results from their large-scale trial of OK-432 with pooled results from large surgical case series reported in the literature and reported greater success rates and lower occurrence of major complications with OK-432 sclerotherapy compared with surgical excision. However, their study focussed mainly on children and only one of the comparative surgical case series included adult patients. Several authors have expressed the opinion that surgical excision of cystic hygroma is an easier procedure in adult patients, because these lesions are better circumscribed, and as such the success rate is greater^[2,5].

In this case, it was thought that the ideal treatment would be complete surgical excision as a multiloculated cystic hygroma may not respond to sclerotherapy. Success of surgery has been found to correlate with histology, encapsulation, complete excision, anatomical location and stage of the lesion¹. Imaging appeared to show smooth margins, indicating a lack of infiltration, which is a good prognostic feature, facilitating complete removal and low recurrence. However, this was an extensive stage V lesion with close relations to major structures and therefore a difficult procedure was anticipated. It proved to be impossible to remove the cystic hygroma completely without rupture, a recognised problem as these tumours usually have a fragile thin wall. Intra-operative rupture of the lesion complicates complete removal as it obscures the limits of the structure^[1]. However, Riechelmann⁶ reported very low levels of recurrence (1/9 patients) following subtotal excision when small plaques of

tumour wall were known to be left in situ. To the best of our knowledge we were able to remove the cystic hygroma completely. Complications of surgery should be discussed with the patient before consent is obtained for surgery, including

-Difficult intubation

_ Scar: there may be a long scar depending on the size of the cystic mass but this should usually improve over time.

_ Injury to important structures and nerves: all blood vessels and nerves located between the mandible and the sternomastoid muscle are vulnerable to injury, specifically the mandibular branch of the facial nerve, the spinal branch of the accessory nerve and the greater auricular nerves and hypoglossal nerves.

_ Venous bleeding is a possibility but injury to the carotid sheath and its content and some external carotid branches should be rare.

_ Wound Infection.

_ Recurrence after surgery is a possibility.

CONCLUSION

_ Cystic hygroma are congenital neck masses usually presenting at birth but may present at any age

_ Cystic hygroma is a rare presentation in adults

_ Malignancy should be excluded in all adult patients presenting with a cystic neck swelling

Adult-onset cystic hygroma

Differential diagnoses for a congenital neck mass in adults

– Branchial cleft cyst (lateral to midline)

– Dermoid cyst (midline)

– Thyroglossal cyst (midline)

– Haemangioma

– Thymic cyst (midline/lateral)

– Neck malignancy (midline/lateral)

Investigations should include:

– Ultrasound scan

– Fine-needle aspiration (important to exclude malignancy)

– Computed tomography or Magnetic resonance imaging

_ Final diagnosis depends on tissue analysis

Treatment options in adults include:

- Surgery
- Sclerotherapy

_ In multiloculated cystic hygromas, surgery may be the preferred option but it is important that surgical complications are kept to a minimum.

REFERENCES

- 1 Adult-onset cystic hygroma: a case report and review of management L. Gow, R. Gulatib, A. Khan and F. Mihaimed *Grand Rounds Vol 11 pages 5–11 Specialities: General Surgery* Article Type: Case Report DOI: 10.1102/1470-5206.2011.0002
- 2 . Woods D, Young JE, Filice R, Dobranowski J. Late-onset cystic hygromas: the role of CT. *Can Assoc Radiol J* 1989; 40:159-161.
- 3 de Casso Moxo C, Lewis NJ, Rapado F. Lymphangioma presenting as a neck mass in the adult. *Int J Clin Pract* 2001; 55: 337–8. PMID:11452685.
- 4 Schefter RP, Olsen KD, Gaffey TA. Cervical lymphangioma in the adult. *Otolaryngol Head Neck Surg* 1985; 93: 65–69. PMID:3920626.
5. Antoniadou K, Kiziridou A, Psimopoulou M. Traumatic cervical cystic hygroma. *Int J Oral Maxillofacial Surg* 2000; 29: 47–8. doi:10.1034/j.1399-0020.2000.290111.x.
6. Riechelmann H, Muehlhans G, Keck T, Mattfeldt T, Rettinger G. Total, subtotal, and partial surgical removal of cervicofacial lymphangiomas. *Arch Otolaryngol Head Neck Surg* 1999; 125: 643–8. PMID:10367920.
7. Smith MC, Zimmerman MB, Burke DK, et al. Efficacy and safety of OK-432 immunotherapy of lymphatic malformations. *Laryngoscope* 2009; 119: 107–15. doi:10.1002/lary.20041. PMID:19117316
8. Baer S, Davis J. Cystic hygroma presenting in adulthood. *J Laryngol Otol* 1989; 103: 976-977.
9. Schefter RP, Olsen KD, Gaffey TA. Cervical lymphangioma in the adult. *Otolaryngol Head Neck Surg* 1985; 93: 65-69.
10. Aneeshkumar MK, Kale S, Kabbani M, David VC. Cystic lymphangioma in adults: can trauma be the trigger? *Eur Arch Otorhinolaryngol* 2005; 262: 335-337.