

Generalized lymphangiomatosis in an adult: Report of an uncommon entity.

Amoolya Bhat^{1*}, Mohan Kumar², Geethamani V³ and Madhuri Rao³

¹Department of Pathology, Sapthagiri Institute of Medical Sciences and Research Centre, Bangalore, Karnataka, India

²Department of Otorhinolaryngology, Sapthagiri Institute of Medical Sciences and Research Centre, Bangalore 90, Karnataka, India

³Department of Pathology, BGS Global Institute of Medical Sciences and Research Centre, Bangalore, Karnataka, India

Abstract

Generalized lymphangiomatosis is rare congenital malformation of lymphatics, infrequently noted in adults. Only a handful of cases have been reported so far. We present a unique case of generalized lymphangiomatosis presenting as bilateral cervical lymphangiomas in an adult. The awareness of this entity helps to make the right diagnosis and offer appropriate treatment.

Keywords: Adult, Bilateral, Cervical, Generalized, Lymph.

Accepted on January 23, 2017

Case Report

A 55 years old man presented with slowly growing painless masses in bilateral cervical regions since 6 months. Clinically they measured 4 × 3 × 2 cm on right and 10 × 9 × 8 cm on left and were cystic in consistency (Figure 1a and 1b). Also noted was a surgical scar on the lower cervical region. There was no history of fever, dysphagia, dyspnea or difficulty in speech. Past history revealed that the patient had undergone surgery for a swelling on the left side of neck of 6 months duration about fifteen years back which was diagnosed as lymphangioma on histopathological examination. He was asymptomatic during childhood. The ultrasonographic examination of neck showed well defined multiseptated anechoic cystic lesions in the posterior triangles of both sides of the neck suggestive of lymphangioma. Colour Doppler did not show increased vascularity. There was no cervical lymphadenopathy. The major vessels of neck and thyroid were unremarkable. ACT scan showed well defined multicystic masses in bilateral cervical areas filled with hyperintense fluid. The hyoid bone showed an expansile osteolytic lesion with sclerotic margins (Figure 1c).

Abdominal ultrasonography revealed a benign cyst in the spleen (Figure 1d). Other abdominal organs were unremarkable. Haemangiomas, lymphangiomas, lymphomas and hydatid cysts were the differentials considered. A fine needle aspiration cytology of both these swellings yielded more than 10 ml of straw colored thin serous fluid. The smears showed numerous lymphocytes in a thin proteinaceous background with occasional histiocytes suggestive of bilateral lymphangioma (Figure 2a). Complete surgical excision was performed. Intraoperatively tumor reached, medially up to carotid triangle, inferiorly up to subclavian triangle and was adherent to skin laterally (Figure 2b). Grossly the external surface was bosselated, and borders were well defined. Cut section showed multiloculated cysts filled with serous fluid (Figure 2c). Microscopic examination showed large cystic spaces lined by flattened endothelium having bland nuclei with the lumen showing eosinophilic proteinaceous fluid and scattered lymphocytes. The wall showed lymphoid aggregates and fibrous tissue (Figure 2d). These features were consistent

with that of lymphangioma. The expansile osteolytic lesion in the hyoid bone, the bilateral lymphangiomas in the neck and cysts in the spleen pointed towards the diagnosis of generalized lymphangiomatosis in this patient.

Discussion

The diffuse involvement by multiple lymphangiomas is called generalized lymphangioma. It is a rare congenital malformation of lymphatics. More than 65% of the cases are reported in children without any sex predilection. It usually presents as multiple cysts in viscera and osteolytic lesions in the bone. It arises from abnormal development of lymphatics in the fetus [1,2]. Although several cases of generalized lymphangiomatosis have been reported [1,2], bilateral affection especially of cervical region in an adult has not been reported so far. Our patient was a 55 years old male with bilateral cervical lymphangiomas and displayed features of generalized lymphangiomatosis. He was asymptomatic during childhood. The origin of lymphangiomas is not clearly known; they may be developmental, hamartomatous, or neoplastic [3]. Adult manifestations may result from delayed proliferation of congenital or acquired lymphoid nests triggered by respiratory infection or local trauma [4]. Three theories of its origin are 1) Cessation of normal growth of the primitive lymph channels during embryogenesis, 2) Failure of the primitive lymphatic sac to join the venous system, 3) inappropriate placement of lymphatic tissue during embryogenesis [5]. Based on the size of the lymphatic cavities, lymphangiomas are classified as microcystic (capillary lymphangiomas), macrocystic (cavernous lymphangiomas) and cystic hygromas [5]. These subtypes coexist in the same lesion, limiting clinical usefulness [6]. The lymphangiomas are divided into serous and chylous type based on contents. Bleeding or infection gives rise to bloody or purulent fluid. Histologically they display dilated vascular channels of varying sizes lined by 1-2 layers of endothelial cell with or without adventitial layer. Calcifications may be present [3]. Specific immunohistochemical markers include lymphatic vessel endothelial receptor 1, vascular endothelial growth factor receptor 3, Prox-1, CD31 and D2-40 [6].

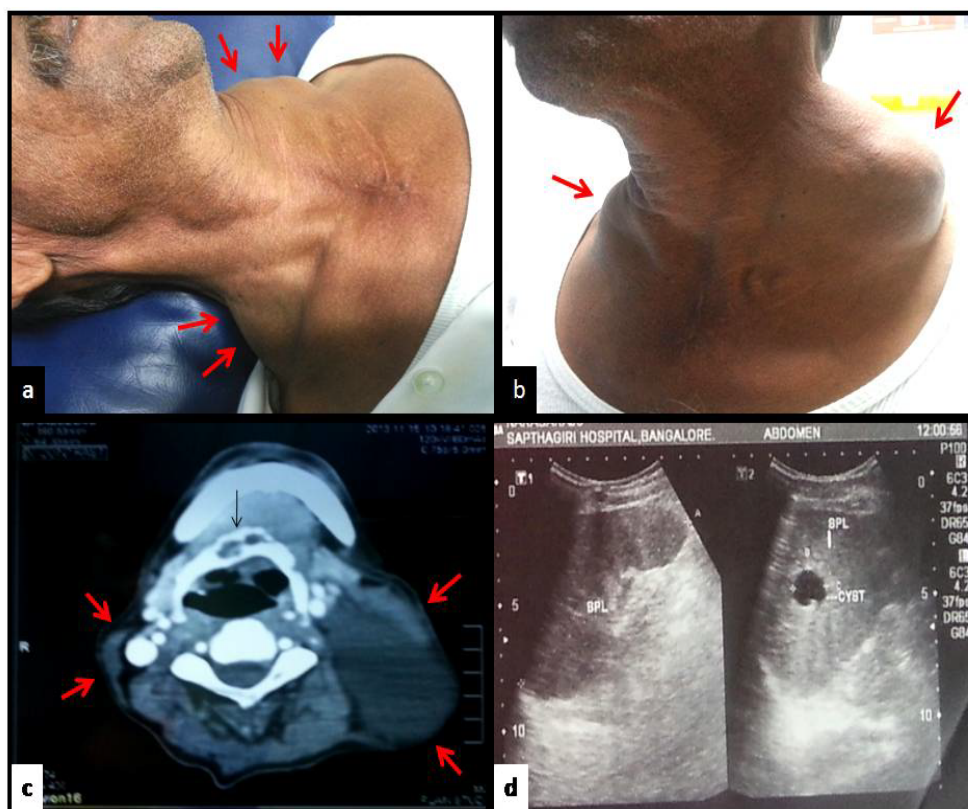


Figure 1. 1a and 1b) clinical picture showing bilateral cervical swellings. 1c) CT image showing cystic masses in the bilateral cervical area and osteolytic lesion in the hyoid bone. d) ultrasonography showing splenic cyst.

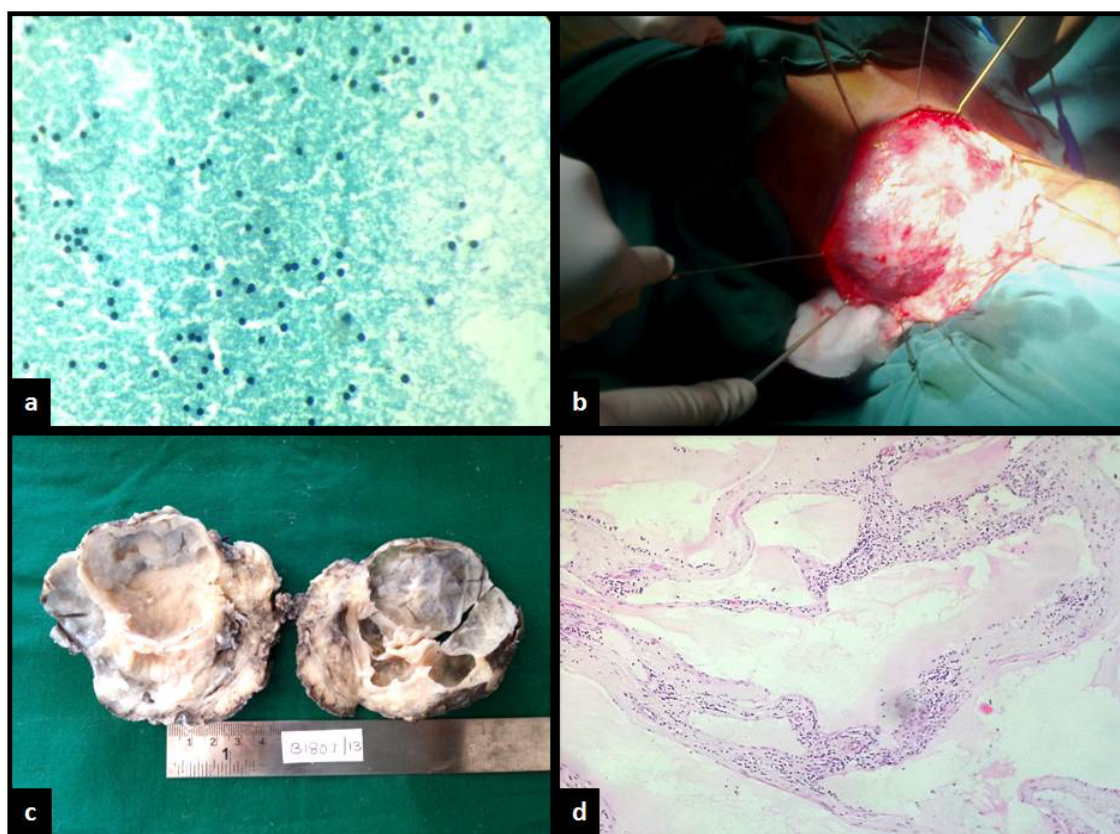


Figure 2. 2a) Cytology smear showing lymphocytes in a proteinaceous background (Pap; x400). 2b) Intraoperative picture showing mass in the subcutaneous tissue plane. 2c) Gross picture showing multi loculated cystic mass. 2d) histopathological picture showing fibrous septae separating cystic spaces lined by flattened endothelium containing eosinophilic fluid and lymphocytes (H&E; x400).

Lymphangiomas present as painless slowly enlarging mass. They show rapid growth following infection, trauma or bleeding, causing disfigurement, dyspnea and dysphagia [7,8]. The lymphangiomas appear large multicystic non-enhancing masses on MRI images. The bony lesions appear as well defined osteolytic lesions with sclerotic margins. Ultrasound and CT scan, are both very sensitive and relatively specific in diagnosing lymphangiomas. Generalized lymphangiomatosis can be diagnosed based on radiological features alone without histological confirmation [3]. Differential diagnosis in adults include, hydatid cyst, branchial cleft cyst, haemangioma, thymic cyst, malignancy and plunging ranulas/mucocoele [7,8]. Cytologically absence of parasitic elements ruled out hydatid cyst, absence of blood ruled out haemangiomas, absence of squamous cells and cholesterol clefts ruled out branchial cysts, absence of atypical cells ruled malignancy. Plunging ranulas show foamy histiocytes in large numbers and few lymphocytes [7]. The background shows mucinous material. Our case showed only rare histiocytes and the lymphocytes were found in abundance. The background showed thin serous fluid. Histopathologically the tumor showed multicystic spaces lined by flattened endothelial cells and these cysts were lined by flattened endothelial cells. The plunging ranulas lack lining epithelial cells and are lined by rows of histiocytes [8].

Fluid aspirated from thymic cysts may be rich in lymphocytes [7], and are indistinguishable from lymphangiomas cytologically. However, the histopathology shows areas of normal thymic tissue displaying lymphoid follicles and Hassall corpuscles [8] which were absent in our case. Bilaterality is extremely uncommon in all these conditions.

The complications include infections of cysts and bleeding [8]. Malignant transformation has not been described in the literature [6]. There is no specific treatment for generalized lymphangiomas. Interferon alfa and palliative therapies like draining the effusion in case of plural involvement can be done. Treatment methods for localized lymphangiomas include surgery, sclerotherapy and laser therapy, or a combination these. Complete surgical excision prevents recurrence [1,2]. Prognosis depends upon the organs affected. Thus, performing radiological evaluation is essential to identify the organs affected and extent of involvement. Patients with chylous plural effusions carry poor prognosis. Laryngeal obstruction due involvement of larynx and pathological fractures due involvement of bone occur have been noted [1,2].

Conclusions

We presented the very unique case of generalized lymphangiomatosis with bilateral cervical involvement in an adult. Although lymphangiomatosis is a benign and common condition in children, it is rare in adults. Also very few cases of bilateral cervical lymphangiomas have been reported in the past. Generalized lymphangiomatosis is an uncommon entity. It can lead to formation of lymphangiomatous lesions in the bone that appear as osteolytic lesions in x-ray. This can be mistaken for malignant deposits. Histopathological diagnosis is gold standard for confirmation of diagnosis. Thus knowledge of existence of such an entity helps to make accurate clinical diagnosis and avoid extensive preoperative diagnostic tests.

References

1. Yang DH, Goo HW. Generalized lymphangiomatosis: Radiologic findings in three pediatric patients. *Korean J Radiol* 2006;7:287-91.
2. CS Wong, Chu TYC. Clinical and radiological features of generalized lymphangiomatosis. *Hong Kong Med J* 2008;14:402-4.
3. Shaffer K, Rosado-de-Christenson ML, Patz EF Jr, et al. Thoracic lymphangioma in adults: CT and MR imaging features. *AJR* 1994;162:283-9.
4. Black T, Guy CD, Burbridge RA. Retroperitoneal cystic lymphangioma diagnosed by endoscopic ultrasound-guided fine needle aspiration. *Clin Endosc.* 2013;46:595-7.
5. Grasso DL, Pelizzo G, Zocconi E, et al. Lymphangiomas of the head and neck in children. *Acta Otorhinolaryngol Ital* 2008;28:17-20.
6. Kambakamba P, Lesurtel M, Breitenstein S, et al. Giant mesenteric cystic lymphangioma of mesocolic origin in an asymptomatic adult patient. *JSCR* 2012;6:4.
7. Orell RS, Sterrett GF. Orell Sterrett's fine needle aspiration cytology. 5th ed. Philadelphia: Churchill Livingstone, Elsevier publications; 2012.
8. Wick MR. The mediastinum. Mills SE, Editor. *Sternberg's Diagnostic surgical pathology*. 5th ed. Philadelphia: Lippincot Williams and Wilkins; 2010;1120-77.

*Correspondence to:

Dr. Amoolya Bhat
Associate Professor
Department of Pathology
Sapthagiri Institute of Medical Sciences and Research
Centre #15,
Chikkasandra, Hesaraghatta Main road,
Bangalore-90, Karnataka,
India.
Tel: +91-9480315066
E-mail: simpathologist@gmail.com