



Endoscopic grommet insertion our experience

Balasubramanian Thiagarajan¹ Venkatesan Ulaganathan² Seethalakshmi Narashiman¹

Stanley Medical College¹ Meenakshi Medical College²

Abstract:

Grommet insertion the commonest surgical procedure next only to circumcision is usually performed using an operating microscope¹. Authors have been using 4 mm 0 degree nasal endoscopes to perform this procedure during the last 5 years. This is a report of their experience in using endoscope in lieu of microscope in performing this surgery. This study makes a comparative analysis of Endoscopic Grommet insertion viz a viz Microscopic Grommet insertion. For this comparative analysis one year (2009) data base of Government Stanley Medical College Chennai India was used. This study reveals that Endoscopic Grommet insertion compared favorably with Microscopic Grommet insertion in all aspects with certain obvious advantages.

Introduction:

Otitis media with effusion is a common condition affecting children. Incidence rate varying from 20-60%² have been reported by various studies. This disorder causes some amount of conductive hearing loss with rare permanent changes involving the tympanic membrane. Majority of otitis media with effusion are of short duration without any lasting sequelae. Long lasting bilateral otitis media with effusion causes long lasting cognitive and language problem in the affected child⁴. The concept of Grommet insertion in managing these patients with secretory otitis media was first popularized by Armstrong^{3,5}. Since this innovation lots of grommet insertions have been performed world wide in managing this troublesome condition. Usually this procedure is performed along with adenotonsillectomy. A systemic Cochrane review on the topic published in 2005 did not show any significant effect of early grommet insertion on cognitive and speech development when compared to children who had a delay of 9 – 12 months before undergoing the procedure.

Bluestone's guidelines for grommet insertion:

Bluestone and Klein (2004) came out with revised indications for grommet insertion which took into consideration the prevailing antibiotic spectrum.

1. Chronic otitis media with effusion not responding to antibiotic medication and has persisted for more than 3 months when bilateral or 6 months when unilateral.

2. Recurrent acute otitis media especially when antibiotic prophylaxis fails. The minimum episode frequency should be 3/4 during previous 6 months / 4 or more attacks during previous year.
3. Recurrent episodes of otitis media with effusion in which duration of each episode does not meet the criteria given for chronic otitis media but the cumulative duration is considered to be excessive (6 episodes in the previous year)
4. Suppurative complication is present / suspected. It can be identified if myringotomy is performed.
5. Eustachean tube dysfunction even if the patient doesn't have middle ear effusion. Symptoms are usually fluctuating (dyssequilibrium, tinnitus, vertigo, autophony and severe retraction pocket).
6. Otitis barotrauma in order to prevent recurrent episodes.

Objective:

The objective of this paper is to compare the conventional Microscopy Grommet insertion versus Endoscopic Grommet insertion procedures.

Methodology:

This comparative analysis was performed by comparing databases available at Stanley Medical College for the year 2009.

Inclusion criteria:

Only children with secretory otitis media who underwent Grommet insertion either using a microscope or endoscope was included.

Parameters used to compare the procedures:

1. Ease of the procedure – Time taken to complete the procedure
2. Complication rate

Ease of the procedure:

This is graded on a scale of three i.e. :

+ simple, ++ difficult, +++ complicated

+ = Surgery was completed in 5 minutes / less

++ = Surgery was completed in 6 – 10 minutes

+++ = Surgery took more than 10 minutes to complete

Results:

No of children who underwent grommet insertion using microscope: 130

No of children who underwent grommet insertion using endoscope: 260

Table I

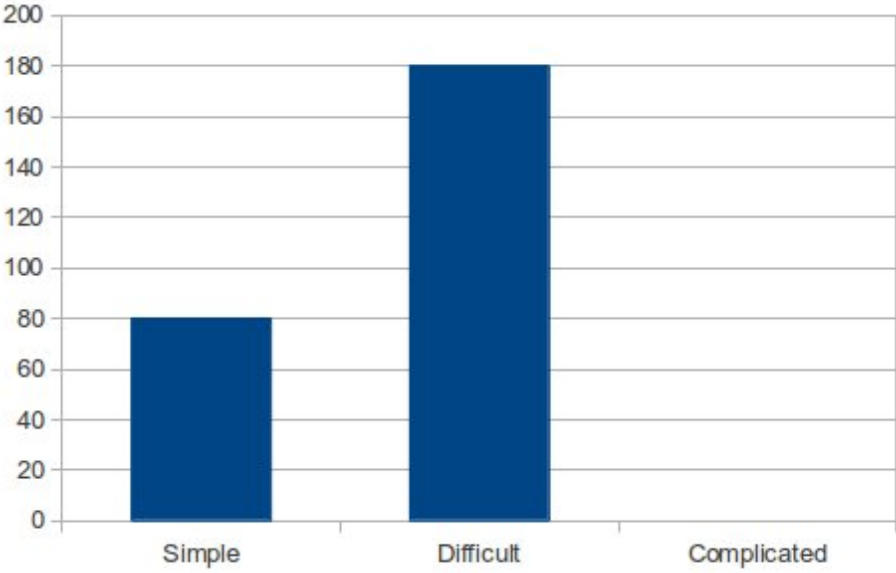
Ease of procedure

Ease of procedure	Microscopic	Endoscopic
+	-	80
++	32	180
+++	98	0

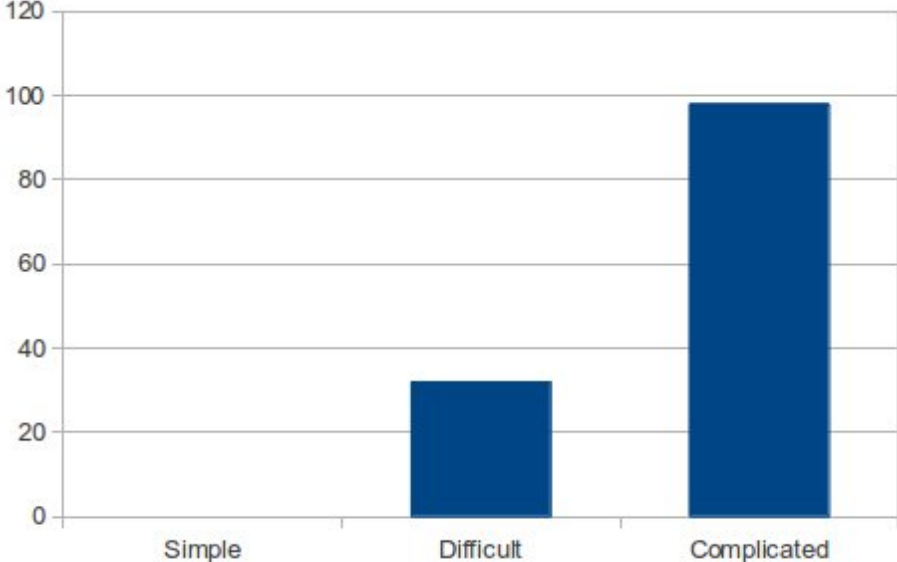
This table shows that in 80 children who underwent endoscopic grommet insertion the surgery was completed within 5 minutes / less. This works out roughly to 30.77% of children. The rest 180 children had their surgery performed endoscopically within 10 minutes.

In comparison when microscope is used none of the procedure could be completed within 5 minutes. 32 children could be operated within 10 minutes span (24.6%), where as surgery of the rest 98 children (75.3%) could be completed in more than 10 minutes.

Endoscopic grommet insertion



Microscopic grommet insertion



Advantages of using an endoscope to perform grommet insertion:

1. Cost effective because of equipment optimization
2. Portable
3. Easy to manipulate (less time is spent on focussing)
4. Video recording is of high quality

Disadvantages:

1. Only one hand is available for performing the surgery
2. Learning curve is steep

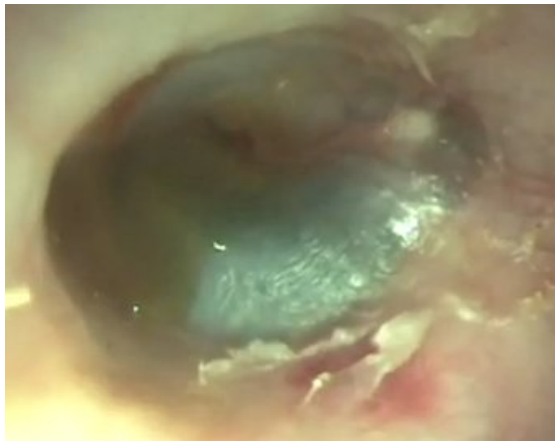


Image showing fluid flowing out of middle ear cavity after ear drum is perforated

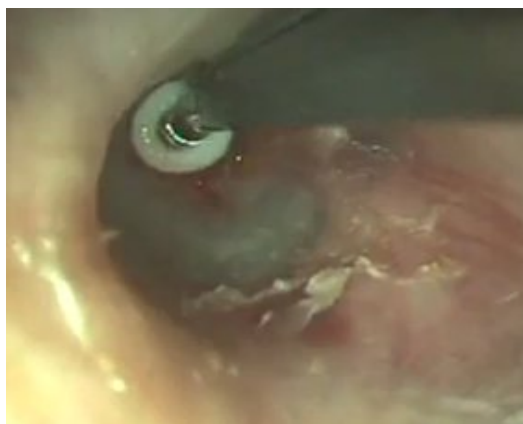

Image showing grommet being inserted

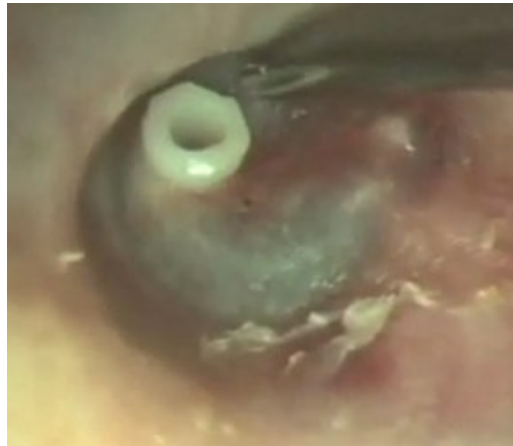

Image showing grommet in situ

Conclusion:

Authors recommend the use of endoscope for performing grommet insertion as it is cost effective and highly portable. The excellent video projection available can be used to train future prospects. Since otolaryngologists who routinely perform nasal endoscopic surgeries are used to manipulate instruments with one hand, this surgery can also be performed with minimal discomfort.

References:

1. A.G. Schilder, W. Lok, M.M. Rovers, International perspectives on management of acute otitis media: a qualitative review, *Int. J. Pediatr. Otorhinolaryngol.* 68 (2004) 29—36.
2. Renvall U, Liden G (1985) Impedance audiometry in detection of secretory otitis media, *Scandinavian audiometry*:4:119-124
3. B.W. Amstrong, A new treatment for chronic secretory otitis media, *Arch. Otolaryngol.* 59 (1954) 653/654.
4. Bluestone CD: Modern management of otitis media. *Pediatr Clin North Am* 36:1371-1387, 1989
5. Gebhart DE: Tympanostomy tubes in the otitis media prone child. *Laryngoscope* 91:849-866, 1981