

EBUS-TBNA Biopsy for Pulmonary Sarcoidosis Diagnosis.

Hui Mai^{1,2}, Yongxiango Zhang², Wei Jias², Yuechuan Li^{2*}

¹Graduate School of Tianjin Medical University, 300070 PR China

²Department of Respiratory and critical care medicine, Tianjin Chest Hospital, Tianjin 300051 PR China

Abstract

Objective: To evaluate the diagnostic efficacy and safety of EBUS-TBNA for biopsy for pulmonary sarcoidosis.

Methods: Seventy eight patients with suspected sarcoidosis were retrospectively included in the present work. The included patients were received either mediastinoscopy (n=491), EBUS-TBNA (n=14), transbronchial biopsy (EBB) (n=102) or EBUS-TBNA+EBBs (n=3) to obtain tissue specimens for pathological diagnosis.

Results: The positive rate of EBUS-TBNA+EBB and Mediastinoscopy was 100% which was significant higher than that of EBUS-TBNA and EBB with statistical difference (p<0.05). The medical expenses during the hospitalization were significantly different among the groups (p<0.05). The average hospitalization costs for mediastinoscopy were significantly higher than those for endoscopy such as EBUS-TBNA (p<0.005). And more than 13 punctures didn't improve the positive rate of diagnosis, but may increase the risk of bleeding.

Conclusion: EBUS-TBNA is a safe and accurate biopsy technique. The diagnostic positive rate is similar to the mediastinoscopy with less postoperative complications, and medical costs.

Keywords: EBUS-TBNA, Biopsy, Pulmonary Sarcoidosis, Diagnosis.

Accepted on December 23, 2019

Introduction

Sarcoidosis is a multisystem granulomatous disease with unclear etiology [1]. Clinically, more than 90% of patients have lung lesions and this disorder often involves the eyes, skin, liver and other organs [2,3]. Histopathological examination is the most important indicator for the diagnosis of sarcoidosis because of the lack of specific clinical manifestations of sarcoidosis [4]. Biopsy reveals non-caseous granuloma, and excludes other granulomatous diseases, in particular with tuberculosis, Hodgkin's lymphoma, and lung cancer.

The diagnosis of sarcoidosis is based on clinical processes, imaging features, histopathological findings, and response to hormone therapy [5-9]. To obtain histological diagnosis is extremely important for clinically suspected sarcoidosis patients. Common techniques for obtaining pathological specimens of the lung, mediastinal and hilar lymph nodes include mediastinoscopy, endobronchial biopsy (EBB), transbronchial lung biopsy (TBLB), and endobronchial ultrasound-transbronchial needle aspiration (EBUS-TBNA) [10]. Clinical applications of TBLB are gradually decreased due to the high incidence of haemorrhage and pneumothorax [11].

This study retrospectively analyzed the clinical data of 78 patients with suspected sarcoidosis in Tianjin Chest Hospital from January 2014 to March 2017, and compared the diagnostic value of mediastinoscopy, EBUS-TBNA, transbronchial biopsy (EBB) and EBUS-TBNA+EBB for pathological specimens of sarcoidosis.

Materials and Methods

Patients inclusion

Patients with thoracic sarcoidosis diagnosed in Tianjin Chest Hospital from January 2014 to March 2017 were selected. All the included patients were clearly diagnosed as sarcoidosis by histopathology, and consistent with the diagnostic criteria of sarcoidosis revised by the Academic Group of the Respiratory Disease of the Chinese Medical Association Respiratory Society in 1994: (1) Clinical manifestations such as coughing and wheezing, or no special clinical manifestations with physical examination revealed enlarged hilar and mediastinal lymph nodes; (2) Characteristic features of chest CT: symmetric enlargement of hilar and mediastinal lymph nodes, or associated with pulmonary nodules, reticulation, infiltrative shadows, etc.; (3) The pathological appearance was non-caseous necrotizing epithelial cell granuloma with negative acid-fast staining. Microbial culture excluded other infectious

diseases; (4) Patients were followed up for at least 3 months. Lymph nodes in the mediastinum and hilum were reduced, and shadows in the lungs were absorbed after hormone therapy.

Finally, 78 patients with sarcoidosis were included. Among the 78 patients with thoracic sarcoidosis, 16 were males and 52 were females, aged 26 to 73 years, with an average of 48.3 ± 1.4 years. Staging based on chest X-ray and/or CT performance, 27 patients in phase I, 21 in phase II, and 1 in phase III. 65 patients had systemic non-specific symptoms such as fever, weight loss, or fatigue. 13 patients had no clinical symptoms and abnormalities were found only on physical examination or occasional chest X-ray examinations.

Imaging staging

The stage of the disease was determined based on the chest X-ray or CT performance. Phase 0: No abnormality; Phase I: Mediastinal, hilar lymphadenopathy, with or without lymphadenopathy in other areas of the lung, and no abnormalities in the lungs; Phase II: Hilar lymphadenopathy with reticular, nodular or lamellar shadows of the lungs; Phase III: Only lung lesions, no hilar lymphadenopathy; Phase IV: Pulmonary fibrosis accompanied by cellular lung formation, pulmonary cyst, emphysema, etc.

Biopsy Procedure

With no abnormalities in ECG and coagulation tests, patients fast solids and liquids for 6 hours before surgery, locally anesthetized using 7% lidocaine in the oropharyngeal cavity and the airways. Conventional bronchoscopy was performed using an Olympus BF 260 electronic bronchoscope. EBB was performed selectively according to imaging and bronchoscopic findings. All patients underwent bronchial brushing for bacterial culture and acid-fast staining. Ultrasonic bronchoscopy was performed using an Olympus UC260 ultrasonic bronchoscope. When performing intra-air ultrasonography till the diameter of the mediastinal or hilar lymph node was smaller than 1 cm, each lymph node was punctured 1 to 3 times for needle biopsy using a 21G needle under ultrasound guidance to obtain visible histopathological specimens, (Figure 1). The smears were fixed with 95% ethanol, sent to cytology smears and acid-fast stained. The specimens were fixed with a neutral formaldehyde solution and sent for histopathological examination. The cytology smear and histopathological diagnosis were performed in both groups. Cytological smear diagnosis and histopathological diagnosis each was performed by a pathologist respectively. The positive diagnostic criteria for cytology smears are epithelioid cells, multinucleated giant cells and lymphocytes under light microscopy. The positive diagnostic criteria for histopathology are non-necrotic epithelial cell granuloma with or without infiltration of lymphocytes and multinucleated giant cells under light microscope.

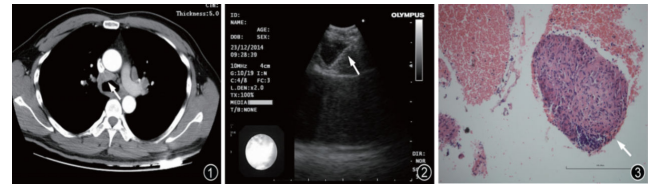


Figure 1. EBUS-TBNA examination and puncture lymph node pathology. Chest CT image of patients with sarcoidosis. The sagittal plane of the pulmonary artery in the mediastinal window of the patient shows the paratracheal 4R lymphadenopathy (arrow). 2) Ultrasound images of ultrasound guided real-time lymph nodes puncture in ultrasound-guided bronchoscopic needle biopsy. The echogenic area in the figure is a 4R enlarged lymph node in the paratracheal site of patients with sarcoidosis. The boundary is clear, the maximum oblique diameter is about 3.0 cm, and the internal blood flow is abundant. The arrow shows a real-time needle biopsy with a needle depth of about 1.5 cm. 3) Pathology of mediastinal lymph node biopsy under ultrasound-guided bronchoscopic needle biopsy in patients with sarcoidosis. The arrow shows the formation of epithelioid granuloma, surrounded by mature small lymphocyte infiltration, negative acid-fast staining

Statistical analysis

SPSS 18.0 statistical software package (IBM, Armonk, NY, USA) was used in dealing with all the data analysis. Measurement data are expressed as mean \pm standard deviation and analyzed by student-t test. The enumeration data was expressed with a relative number, and the comparison between groups was made based on the χ^2 test. $p < 0.05$ was considered statistically significant.

Results

General characteristics of the included patients

There was no statistical difference in the age and gender composition among the groups ($p > 0.05$). However, there was a statistically significant difference in the clinical staging of sarcoidosis ($p < 0.05$) (Table 1).

Table 1. General characteristics of the patients in different groups.

Groups	n.	Age (years)	Gender(M/F)	Sarcoidosis stages		
				I	II	III
Mediastinoscopy	49	46.7 \pm 1.2	10/39	31	16	2
EBUS-TBNA	14	47.6 \pm 0.9	3/11	2	11	1
EBB	12	49.2 \pm 1.1	2/10	9	2	1
EBUS-TBNA+EBB	3	50.3 \pm 1.0	1/2	0	3	0
t/χ^2		0.96	3.520	2.735		

p-value	0.595	0.067	0.007
---------	-------	-------	-------

Positive rates of mediastinoscopy, endobronchial biopsy, and EBUS-TBNA in the diagnosis of sarcoidosis

Forty-nine patients underwent mediastinal lymph node biopsy, and all of them (100%, 49/49) had positive pathological findings. According to lymph node involvement, 14 patients underwent EBUS-TBNA, in which 12 patients (85.71%, 12/14) had positive pathological findings. According to mucosal involvement as revealed by bronchoscopic findings, 12 patients underwent EBB, in which 9 patients (81.82%, 9/12) had positive pathological findings (Figure 2). The positive rate of EBUS-TBNA+EBB and mediastinoscopy was 100% which was significant higher than that of EBUS-TBNA and EBB with statistical difference ($p < 0.05$). The medical expenses during the hospitalization were significantly different among the groups ($p < 0.05$). The average hospitalization costs for mediastinoscopy were significantly higher than those for endoscopy such as EBUS-TBNA ($p < 0.05$) (Table 2).

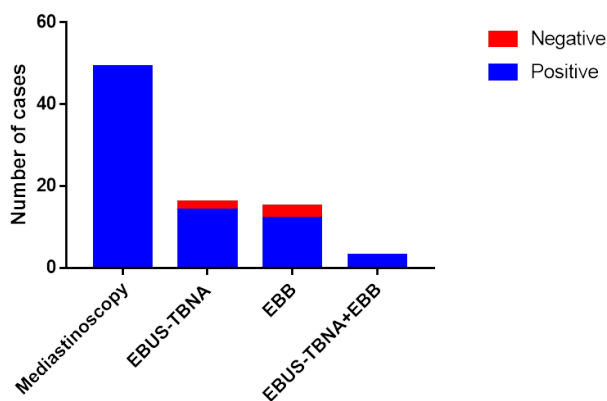


Figure 2. Positive rates of mediastinoscopy, endobronchial biopsy, and EBUS-TBNA in the diagnosis of sarcoidosis.

Table 2. Diagnostic performance comparison.

Groups	n.	No of positive	No. of negative	Diagnostic costs (RMB)
Mediastinoscopy	49	49 (100.0%)	0 (0.0%)	21763.1 ± 4352.2
EBUS-TBNA	14	12 (85.7%)	2 (14.3%)	16132.4 ± 2864.6
EBB	12	9 (75.0%)	3 (25.0%)	10212.7 ± 2065.3
EBUS-TBNA+EBB	3	3 (100.0%)	0 (0.0%)	18315.5 ± 2741.8
t/χ ²		9.69		32.93
p-value		0.02		<0.0001

Relationship between the times of lymph node puncture by EBUS-TBNA and the diagnostic positive rate

In cases where the patient's enlarged lymph node is bigger than 1 cm in diameter, multiple punctures at different sites can help

improve the positive rate of diagnosis. No complications such as bleeding occurred after puncture in 14 patients with EBUS-TBNA within 3 lymph node punctures in the same site; but more than 3 punctures may have no obvious significance for improving the positive rate of diagnosis, and may even have risk of bleeding (Table 3).

Table 3. Comparison of the Number and Positive Rate of Puncture of EBUS-TBNA in Different Parts.

Zone 4 lymph nodes						Zone 7 lymph nodes					
Puncture time	1	Puncture times	2	Puncture times	3	Puncture time	1	Puncture times	2	Puncture times	3
	2		6		1		2		8		1
+	-	+	-	+	-	+	-	+	-	+	-
	1	1	6	0	1	0	1	1	8	0	1

Discussion

Surgical medial techniques such as mediastinoscopy were the first choice for disease diagnosis in patients with mediastinal and hilar lymph node enlargement before the advent of EBUS-TBNA technology [12-15]. However, it is invasive and may have serious complications. Subcarinal lymph nodes, hilar lymph nodes, and even interleaf lymph nodes are difficult to obtain. EBUS-TBNA, which is safe, real-time, accurate, minimally invasive as a diagnostic technology, is to install a micro-ultrasonic probe at the end of the bronchoscope to perform real-time puncture needle biopsy of the medial mediastinal and hilar lymph nodes [15,16]. It is highly accurate and safe in the diagnosis of mediastinal and hilar lymphadenopathy. EBUS-TBNA was primarily used for the staging of mediastinal lymph nodes in lung cancer, while clinical studies had shown that it had high accuracy in the diagnosis of thoracic sarcoidosis [17-19]. EBUS-TBNA is widely used to diagnose sarcoidosis as an important advance in the diagnosis of sarcoidosis in the past decade. A meta-analysis showed that the sensitivity of EBUS-TBNA in the diagnosis of sarcoidosis was 79%, which was higher than other bronchoscopy diagnostic techniques [18]. One study showed that the accuracy of EBUS-TBNA and EBB in the diagnosis of sarcoidosis is 84% and 68%, but when combined, the diagnostic accuracy can reach over 95% [20]. Therefore, Gupta et al. [20,21]. Believe that EBUS-TBNA is the highest diagnostic value for sarcoidosis, and the diagnostic positive rate can be further increased when combined with other operations such as EBB. In addition, EBUS-TBNA can extract the subcarinal lymph nodes, and even the enlarged lymph node tissue between the hilum and the leaves. Recent studies [21-23] have pointed out that the independent factors that affect the positive rate of diagnosis of sarcoidosis by EBUS-TBNA are: (1) The short diameter of lymph nodes is greater than 1 cm; (2) The positive rate of diagnosing sarcoidosis of multiple punctures per lymph node was higher than that of single puncture; (3) clinical stage of sarcoidosis. The puncture of lymph nodes at different sites will not affect the positive rate of diagnosis of sarcoidosis. As lymph nodes with larger diameters

mean epithelial hyperplasia, the positive rate of puncture is much higher. Therefore, the largest diameter lymph node puncture should be given priority in order to improve the positive rate of diagnosis of sarcoidosis by EBUS-TBNA. Our findings have shown that the positive rate of EBUS-TBNA +EBB and Mediastinoscopy was 100% which was significant higher than that of EBUS-TBNA and EBB with statistical difference ($p<0.05$). And the positive rate for diagnosis of sarcoidosis with multiple punctures per lymph nodes is greater than that of single puncture per lymph node. However, when puncturing more than 3 times, the positive rate of diagnosing sarcoidosis does not increase with the number of punctures.

There are several limitations for the present work. First, this was a retrospective study, the clinical evidence level was weak than prospective study. Second, all cases were from one centre with a small samples size. Therefore, the diagnostic value of EBUS-TBNA for benign diseases such as sarcoidosis needs to be further confirmed by a large sample of randomized controlled studies. The period for our department to carry out EBUS-TBNA technical inspection is still short. Compared with the medical institutions that developed the technology earlier in the country, the technical proficiency of the operating doctors is not consistent, which affects the positive rate of pathological diagnosis of the biopsy to some extent.

Conclusion

This study shows that EBUS-TBNA is a safe and accurate biopsy technique. The diagnostic positive rate is similar to the mediastinoscopy with less postoperative complications, higher safety, and reduced medical costs for hospitalization. For biopsy of lymph nodes with diameter >1 cm, EBUS-TBNA may be considered as the preferred diagnostic technique for patients with sarcoidosis.

References

- Llanos O, Hamzeh N. Sarcoidosis. *Med Clin North Am* 2019; 103: 527-534.
- Salah S, Abad S, Monnet D, Brézin AP. Sarcoidosis. *J Fr Ophtalmol* 2018; 41: e451-e467.
- Arkema EV, Cozier YC. Epidemiology of sarcoidosis: current findings and future directions. *Ther Adv Chronic Dis* 2018; 9: 227-240.
- Cavazza A, Harari S, Caminati A, Barbareschi M, Carbonelli C, Spaggiari L, Paci M, Rossi G. The histology of pulmonary sarcoidosis: a review with particular emphasis on unusual and underrecognized features. *Int J Surg Pathol* 2009; 17: 219-230.
- Kirsten D. Pulmonary sarcoidosis: current diagnosis and treatment. *Dtsch Med Wochenschr* 2013; 138: 537-541.
- Stojić J, Vucinić-Mihailović V, Jovanović D, Stojković M, Videnović-Ivanov J, Filipović S. Evaluation of the role of pathology in the diagnosis and differential diagnosis of pulmonary and extrapulmonary sarcoidosis. *Srp Arh Celok Lek* 2011; 139: 481-485.
- Navani N, Booth HL, Kocjan G, Falzon M, Capitanio A, Brown JM, Porter JC, Janes SM. Combination of endobronchial ultrasound-guided transbronchial needle aspiration with standard bronchoscopic techniques for the diagnosis of stage I and stage II pulmonary sarcoidosis. *Respirology* 2011; 16: 467-472.
- Nishino M, Lee KS, Itoh H, Hatabu H. The spectrum of pulmonary sarcoidosis: variations of high-resolution CT findings and clues for specific diagnosis. *Eur J Radiol* 2010; 73: 66-73.
- MCB G, Ost D, Geiger B, Novak C, Nonaka D, Vlahos I, Naidich DP. Utility of virtual bronchoscopy-guided transbronchial biopsy for the diagnosis of pulmonary sarcoidosis: report of two cases. *Chest* 2008; 134: 630-636.
- Trisolini R, Baughman RP, Spagnolo P, Culver DA. Endobronchial ultrasound-guided transbronchial needle aspiration in sarcoidosis: Beyond the diagnostic yield. *Respirology* 2019; 24: 531-42.
- Poletti V, Patelli M, Spiga L, Ferracini R, Manetto V. Transbronchial lung biopsy in pulmonary sarcoidosis. Is it an evaluable method in detection of disease activity. *Chest* 1986; 89: 361-365.
- Sehgal IS, Dhooria S, Aggarwal AN, Behera D, Agarwal R. Endosonography Versus Mediastinoscopy in Mediastinal Staging of Lung Cancer: Systematic Review and Meta-Analysis. *Ann Thorac Surg* 2016; 102: 1747-1755.
- Hegde PV, Liberman M. Mediastinal Staging: Endosonographic Ultrasound Lymph Node Biopsy or Mediastinoscopy. *Thorac Surg Clin* 2016; 26: 243-249.
- Block ML, Tarrazzi FA. Invasive mediastinal staging: endobronchial ultrasound, endoscopic ultrasound, and mediastinoscopy. *Semin Thorac Cardiovasc Surg* 2013; 25: 218-227.
- Medford AR, Bennett JA, Free CM, Agrawal S. Mediastinal staging procedures in lung cancer: EBUS, TBNA and mediastinoscopy. *Curr Opin Pulm Med* 2009; 15: 334-342.
- Vilmann P, Puri R. The complete "medical" mediastinoscopy (EUS-FNA + EBUS-TBNA). *Minerva Med* 2007; 98: 331-338.
- Dziedzic DA, Peryt A, Orłowski T. The role of EBUS-TBNA and standard bronchoscopic modalities in the diagnosis of sarcoidosis. *Clin Respir J* 2017; 11: 58-63.
- Agarwal R, Srinivasan A, Aggarwal AN, Gupta D. Efficacy and safety of convex probe EBUS-TBNA in sarcoidosis: a systematic review and meta-analysis. *Respir Med* 2012; 106: 883-892.
- Nakajima T, Yasufuku K, Kurosu K, Takiguchi Y, Fujiwara T, Chiyo M, Shibuya K, Hiroshima K, Nakatani Y, Yoshino I. The role of EBUS-TBNA for the diagnosis of sarcoidosis-comparisons with other bronchoscopic diagnostic modalities. *Respir Med* 2009; 103: 1796-800.

***Correspondence to**

Yuechuan Li

Department of Respiratory and critical care medicine

Tianjin Chest Hospital

PR China