

Congenital Fibrosarcoma of Foot – A case report

Author(s): G. Chetan, Vishnu Bhat, K.S. Sreerag, S.Jagdish, Jayanthi S

Vol. 12, No. 1 (2008-10 - 2008-12)

Curr Pediatr Res 2008; 12(1 & 2): 9-11

G. Chetan, Vishnu Bhat, K.S. Sreerag*, S.Jagdish*, Jayanthi S**

Departments of Pediatrics, Pediatric Surgery* and Pathology**
Jawaharlal Institute of Post Graduate Medical Education and Research [JIPMER], Puducherry

Key words: Congenital fibrosarcoma, Newborn, Histological changes.

Accepted August 5 2007

Abstract

Congenital fibrosarcoma is an unusual childhood tumour, and only a few of them are pre-sent since birth. A female baby with fibrosarcoma of lower limb has been presented with surgical treatment and histopathological findings.

Introduction

Congenital fibrosarcoma is a rare soft tissue malignancy involving the extremities [1]. Histologically, they are similar to their adult counterparts but differ in their clinical behaviour. Though recurrence is common, metastases are rare and prognosis is good [1,2]. There are only four cases of childhood fibrosarcoma reported from the Indian subcontinent [3]. We report a case of congenital fibrosarcoma of the lower extremity in a newborn infant.

Case report

A preterm (35 weeks of gestation), female weighing 2.8 kg and appropriate for gestational age baby was born to a second gravida mother with a normal first child. The parents were non-consanguineous and antenatal period was uneventful. The mother did not receive any antenatal care and there was no history of any medication, radiation exposure or exanthematous illness. Child was delivered by emergency cesarean section for fetal bradycardia. At birth child did not require active resuscitation and 1 minute and 5 minute APGAR scores were 8/10 and 9/10 respectively.

Child was noticed to have a firm, non-mobile, reddish with ulcerative swelling over the right sole measuring 5X4 cm (Fig. 1). X-ray foot showed thinning of metatarsal bone with erosion. Ultrasound abdomen and cranium, ECHO heart and chest X-ray were normal. Hematological and biochemical parameters were also normal.

Fine needle aspiration cytology was done. It showed round to oval shaped cell in hemorrhagic background. No abnormal cells were seen. Our initial impression was either a sarcoma or hemangioma. The swelling rapidly increased in size over next 10 days. Open biopsy was done which was suggestive of soft tissue sarcoma. Fore foot amputation was done and histopathological examination confirmed the diagnosis. Gross pathological specimen showed skin with underlying tumor tissue. Skin was free of tumor. Tumor tissue was seen infiltrating fat, skeletal muscle, bone and cartilage. It was not involving the resected margins. Microscopic examination confirmed features of infantile fibrosarcoma with Herring bone pattern. Frequent mitosis was seen (Fig.2). Post operatively child was stable. She is on regular follow-up without recurrence (Fig. 3).

Discussion

Paediatric soft tissue sarcomas account for 7% of all childhood tumours. Congenital fibrosarcoma is a rare soft tissue malignancy, and 300 cases have been reported in the world literature.[1] The age groups affected are infants and young children under the age of five (congenital variety), and children between 10 and 15 years of age.[1,4] These tumours originate from the primitive mesenchymal tissue. There is no evidence of increased familial incidence but chromosomal analysis has revealed a non random gain of extra chromosomes, +8, +11, +17, +20 and an abnormal karyotype 48,XY, 11 and 20⁰. These tumours affect children under the age of five with a male preponderance. Clinically, they present with a rapidly enlarging swelling in the soft tissue. Commoner sites of involvement are the extremities, head, neck, trunk, and retroperitoneum. They may be asymptomatic initially or may show symptoms because of local invasion. The local complications include ulceration, haemorrhage and infection.

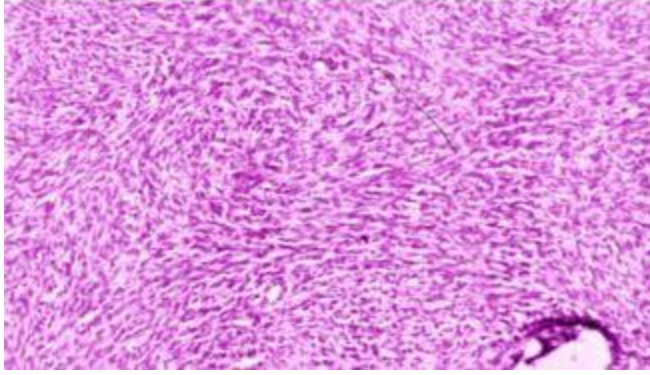
Fig.1: Ulcerated soft tissue swelling arising from sole of Right foot

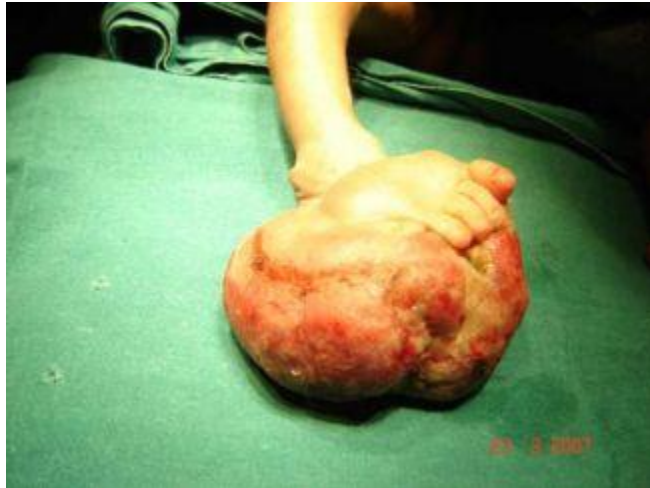

Fig. 2: Post-operative photograph after partial amputation of right foot.

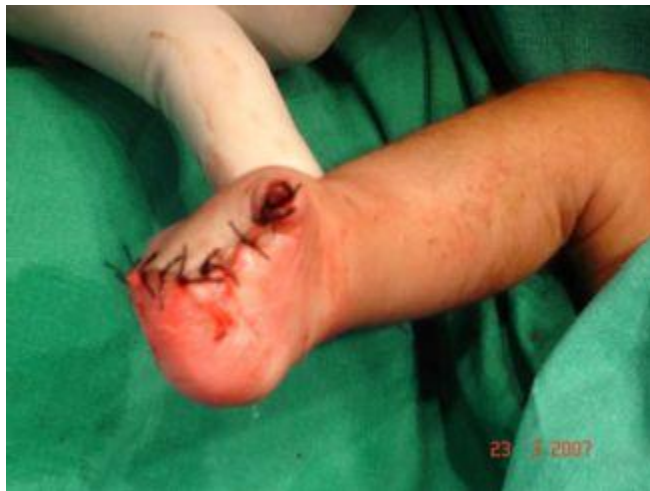

Fig. 3: Photomicrograph showing Herring-bone pattern and myxoid areas with increased mitotic figures suggestive of Infantile Fibrosarcoma. [H & E stain 200X]



These tumours are rapidly growing and are known to attain large sizes. Antenatal or postnatal ultrasound usually shows a poorly circumscribed, heterogenous and vascularised soft tissue mass, which grows very rapidly and causes deformity of the anatomical region involved. Sometimes it causes polyhydramnios. Rest of the fetus is usually normal.

Histologically, the tumours bear a close resemblance to fibrosarcoma in adults, having anaplastic spindle-shaped cells arranged in a herring bone pattern, however, some of the striking features are uniform, well-oriented fibroblasts, scattered round cells, and chronic inflammatory cells like lymphocytes. Multinucleated giant cells are rare. Mitotic figures are a common feature. Rich vascular areas may be seen.

The tumour needs to be distinguished from the richly cellular but benign form of fibromatosis and other types of soft tissue sarcomas like embryonal rhabdomyosarcoma, synovial sarcoma and neurofibrosarcomas.

Treatment is wide local excision or amputation. Chemotherapy and radiotherapy are reserved for unresectable tumours and for recurrences or metastases. Congenital fibrosarcoma has an excellent prognosis. Chung and Enzinger reported a 5-year survival rate of 84% in a series of 53 cases [2]. One case of spontaneous regression of congenital fibrosarcoma is reported.[7]

There are higher metastatic and mortality rates for axial lesions, indicating a more aggressive behaviour. The relatively benign course of such tumours may be due to a significantly lower proliferative index coupled with enhanced apoptosis. The favourable clinical course and biological features of congenital-infantile sarcomas have raised a question about its nomenclature as sarcoma rather than a borderline tumour.[5,6]

References

1. Enzinger FM, Sharon WW. Congenital and infantile fibrosarcoma. Soft Tissue tumours 1983; Volume ?: 115-122
2. Chung EB, Enzinger FM, Infantile fibrosarcoma. Cancer 1976; 38: 729-739
3. Gonda P. Congenital fibrosarcoma: A case report with review of literature. Indian J Surg 2003; 65: 510-511.
4. Schofield DE, Flether JA, Grier HE, Yunis EJ. Fibrosarcomas in infants & children. Application of new techniques. Am J Surg Pathol 1994; 18: 14-24.
5. Wilson MB, Stanley W, Sens D, Garvin AJ. Infantile Fibrosarcoma-a misnomer? Paed Pathol 1990; 10: 901-907. Congenital Fibrosarcoma of Foot- A case report
6. Coffin CM, Jaszoz W, Oshea PA, Dehner LP. So called infantile fibrosarcomas. Does it exist and what is it? Paed Pathol 1994; 14: 133-150
7. Madden NP, Spicer RD, Allibone EB, Lewis IJ. Spontaneous regression of neonatal fibrosarcoma. Br J Cancer Suppl. 1992; 18: S72-S75.

Correspondence:

B. Vishnu Bhat

Department of Pediatrics,
JIPMER, Pondicherry 605006 India
Phone: +91-413-2273139

Fax: +91_413-2272067

e-mail: drvishnubhat (at) yahoo.com