

## Condylomata acuminata in an infant: A case report.

Josephat M Chinawa<sup>§</sup>, Obu H

Department of Paediatrics, Faculty of Medical Sciences, University of Nigeria, Nigeria

### Abstract

We report a case of Condylomata acuminata (CA) in an infant, a rare presentation of a fleshy, painful, soft and grayish mass (warts). In presenting this report, we wish to highlight the distinctive manifestation of CA and to provide a concise report of this disorder in infancy with the hope that such information will aid early recognition and treatment of this condition, especially in infancy and children. It needs to be mentioned that a high index of suspicion should be maintained to be able to make this diagnosis in early life.

**Keywords:** Condylomata acuminata; Infancy; Distinctive; Manifestation

Accepted April 27 2013

### Introduction

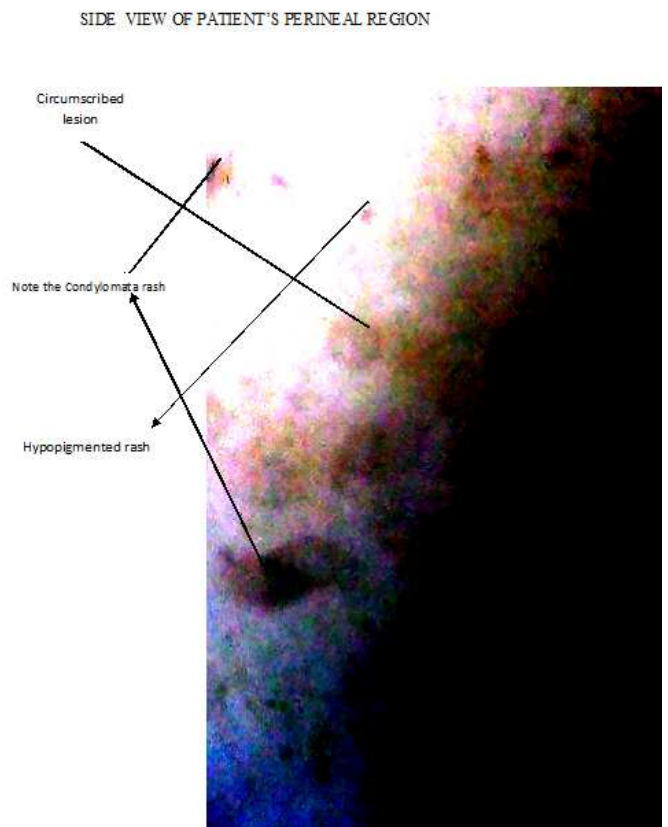
We present a rare case of CA in an infant. The purpose of presenting this case is to highlight the distinctive manifestation and the possibility of its occurrence in infancy.

CA presents as soft skin coloured warts and are caused by Human Papilloma Virus (HPV). The disease is highly contagious, can appear singly or in groups, and may be small or large. [1] Although common in adults, it is rare in children. It is usually transmitted sexually in adults but mainly from maternal genital tract during delivery, auto-inoculation and sometimes sexual abuse in children. [2] They are the most common viral sexually transmitted disease in the USA. Although CA affects both genders, data from office visits for warts obtained from the National ambulatory medical care survey showed that women accounted for 67% of patients population.[3] in Nigeria, it accounts for 38.9% of all biopsy skin lesions.[4] Diagnoses are primarily clinical.[4] As malignant transformation of CA is known to occur, it is of utmost importance that such lesions in children are treated promptly.[5]

### Case presentation

NF is a 14 month old child who presented with a mass protruding from the anus for 6 months. This was insidious in onset with a history of pain and difficulty in defecating. Mother had no such growth in pregnancy. The child had never been sexually assaulted. Examination revealed an apprehensive child with an anal growth, grayish, non tender and non fungating. A clinical diagnosis of Condylomata Acuminata was made. Pod-

Phyllin resin was used to burn the masses for about 4 days and this cleared



### Discussion

The infectious cause of condyloma acuminata was demonstrated in 1917 by the experimental transmission of the disease from penile condyloma tissue.[6] Topical podophyllin was first reported to be effective in 1942 by Kap-

lan.[7]. The first modern study demonstrating the sexual route of transmission of HPV was in 1954, when Barrett and colleagues observed 24 women with genital warts, all of which had appeared within 4 to 6 weeks of the patients' husbands return from the Korean War. All of these men admitted to sexual contact with women in the Far East, and all of them had recently had penile warts. [8] In this case, however, there was no history of sexual contact. CA is caused by the HPV which is a small DNA virus that does not grow in tissue culture but can be identified by electron microscopy [9] Presentation in paediatric age group (though rare) is from one to six months of age.[10] Our patient presented at 6 months of age. This is in keeping with the commonly observed pattern in children.

Pregnant women infected with CA can pass the infection to their newborns. [11] In children less than two years, the mode of transmission is vertical (from mother to child during child birth). [11] This is not likely the case in this patient since the mother did not notice any wart during pregnancy.

The commonest complaint in patients with CA is pain [6] as was noted in this patient.

Topical treatment of children with CM includes the application of caustic or irritating agents such as liquid nitrogen trichloroacetic acid, cryotherapy or podophyllin resins. Carbon (IV) oxide laser is the current mode of treatment with advantage of covering a large area. We used topical podophyllin two times a day in this patient with very good response.

Other masses can present as CA. For instance, Molluscum Contagiosum may protrude from the genitals but it is often painless and umbilicated. Squamous cell carcinoma in situ is initially painless, rare in children and can cause weight loss

### Consent

An informed consent was obtained from the parents of care-giver.

### Conclusions

CA though common in adults is rare in children. Careful history, good examination and a high index of suspicion are needed to make the diagnosis in children. Podophyllin has been found to be an effective treatment.

### Acknowledgements

We are grateful to all the nurses that work at Blessed Children Hospital, Enugu for their co-operation. Our gratitude also extends to the care-giver and patient who were very cooperative. Finally, we thank the almighty God

whose assistance and ideas through the course of this work is priceless.

### References

1. Mybara F, Antigona G, Laura P, Yaurane B, Auma K, Sohkyendye D. Condylomata Acuminata in a child with laser therapy. *Cases journal* 2009; 2:123
2. Gustavo S, Stanley M, Linda C. Condylomata acuminata in children. *J paediatr Surg* 2006;20:499-501
3. Fleisher AB, Parrish CA, Glenn R, Feldman SR. Condylomata acuminata: Patients demographics sex and treating physician. *Sex Transm Dis* 2001; 28:643
4. Ndahu A, Gadzema G, Nggada H. Skin Warts in Maiduguri, Nigeria: A Pathological Review. *The Internet J of Dermatology* 2008; 6:2.
5. Alexander K, Ulrike W. Giant condylomata Acuminatum of Buschke and Lowenstien. *N Eng J Med* 2011;365:1624
6. Oriol JD: Natural history of genital warts. *Br J Vener Dis* 1971 ;47:1-3
7. Kaplan I: Condyloma acuminata. *New Orleans Med Surg J* 1942; 94:388-390.
8. Barrett TJ, Silbar JD, McGinley J: Genital warts-a venereal disease. *JAMA* 1954; 154:333-34.
9. Mikio I, Hiroshi N. Condylomata acuminata in three year old girl. *Urology* 1992; 39:484-8610. Turing S. Human Papilloma virus infections; Epidemiology, Pathogenesis, and host immune response. *J Am Acad Dermatology* 2000;43: 18-26.
10. Shelton TB, Jerkins GR, Noe HN. Condylomata Acuminata in the paediatric patient. *J Urol* 1986; 135:9- 548

### Correspondence to:

Josephat M Chinawa  
Department of Paediatrics  
Faculty of Medical Sciences  
University of Nigeria  
Ituku-Ozalla, Enugu  
Nigeria