



COMBINED SUBCILIARY AND ENDOSCOPIC DACRYOCYSTORHINOSTOMY – A NOVEL APPROACH

¹ Rajesh.R.Yadav ¹ Ameya Asarkar ² Girish Surlikar ³ Dhond

¹ Rajawadi Municipal Hospital, Ghatkopar, Mumbai ² Private Consultant ³ Bhagwati General Hospital, Borivili

ABSTRACT

INTRODUCTION: There are various techniques of dacryocystorhinostomy for treating chronic nasolacrimal duct obstruction like endonasal dacryocystorhinostomy (DCR), external DCR. Here, authors have discussed about a combined subciliary endoscopic technique.

MATERIALS & METHODS: Prospective interventional study reporting 5 patients with chronic dacryocystitis undergoing subciliary endoscopic DCR.

RESULTS: Pre-operative diagnosis was primary acquired nasolacrimal duct obstruction in all cases. No other nasal procedures were performed at the time of surgery. In all patients nasolacrimal duct was patent at 6 months follow up.

CONCLUSIONS: Our combined technique of endonasal dacryocystorhinostomy and subciliary approach has certain advantages over both endonasal and external dacryocystorhinostomy. A prospective comparative study to further evaluate the efficacy and safety of this surgical technique is under way.

KEY WORDS: dacryocystorhinostomy, endoscopic, endonasal, osteotomy

INTRODUCTION

Chronic dacryocystitis is defined as the chronic inflammation of the lacrimal sac due to stricture of the nasolacrimal duct secondary to chronic inflammation, which is usually nasal in origin. The essential symptom is epiphora. There may be swelling at the site of the sac (mucocele), and the neighboring parts of the conjunctiva are frequently inflamed.

It was Toti, who in 1904, reported this procedure for external dacryocystorhinostomy. He made a hole in the lacrimal sac and another hole in the nose and approximated the two with a tight pressure bandage.[1]

Endoscopic approach for dacryocystorhinostomy was introduced by Caldwell,¹ almost one hundred years ago but failed due to difficulties in visualization. In 1974 Jokinen and Karza² revived the endonasal approach for the lacrimal system.

Both endoscopic as well as external DCR have their own advantages and disadvantages, hence we propose a combined technique involving a subciliary incision and an endoscopic approach thus circumventing certain disadvantages of both endoscopic as well as external DCR

MATERIALS & METHODS

6 patients with chronic dacryocystitis were operated. The technique used was a combined subciliary incision with endoscopic DCR. All patients were questioned about the history of their current symptoms as well as other relevant history. Thorough clinical examination was also performed including sac syringing which confirmed nasolacrimal duct obstruction.

No other specialized investigations were needed. Only the ones for routine anaesthetic considerations were ordered.

RESULTS

All patients underwent sac syringing on table to confirm the patency of the lacrimal sac. Also the patients were asked to follow up every month for the first 6 months and sac syringing done at every sitting.

None of the 6 patients reported any scar related problems. Also all the patients had patent lacrimal system at the end of 6 months.

DISCUSSION

The technique used by the authors is a combination of two approaches which help us to combine advantages of both external as well as endoscopic approach.

INDICATIONS OF COMBINED SUBCILIARY AND ENDOSCOPIC DACRYOCYSTORHINOSTOMY

- Routinely done for nasolacrimal duct obstruction and recurrent dacryocystitis.
- In case of a failed first surgery, as revision surgery.
- In a case, where endonasal DCR is anticipated to be difficult, e.g. Down's syndrome having a thick bone plate, suspected diverticulum of sac.

The surgical procedure in brief is as follows.

The initial steps are same as any endonasal DCR.

Positions

Head high position (about 30°) to decrease venous return, thereby decrease bleeding.

Decongestion

- Nasal patty or cottonoids soaked with 4% lignocaine with adrenaline is used.

Infiltration

- Two percent lignocaine with adrenaline is injected intranasally, anterior to the attachment of middle turbinate.
- Infraorbital and Infratrochlear block is given.

Incision

H-shaped incision is taken 8 mm anterior and superior to the attachment of middle turbinate

Flap Elevation

Two flaps are raised and the lacrimal bone is exposed

Osteotomy

Removal of frontal process of maxilla uncovers anteroinferior portion of sac. Maximum bone is removed and thereby sac is exposed

Exposure of Sac

Methylene blue is injected through punctum to stain and enlarge the sac.

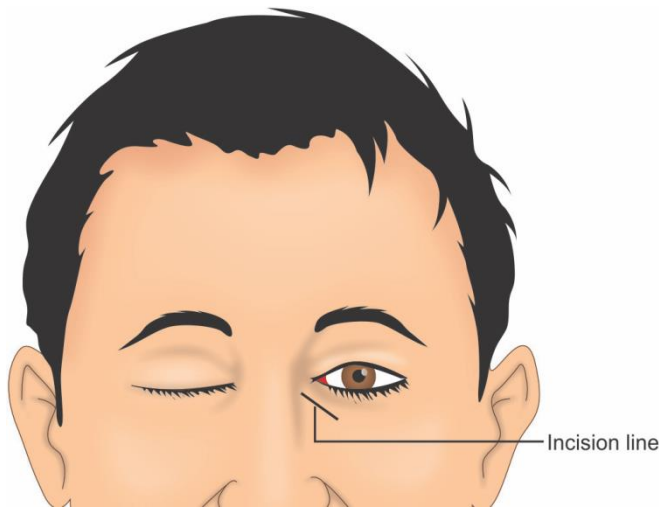


Fig 1 SUBCILIARY INCISION

Subciliary Incision

10-15 mm incision is taken lateral to medial canthal tendon with BP knife (11) (Fig. 1). Injury to medial canthal tendon is avoided.

Dissection

Myocutaneous dissection (suborbicularis) is continued inferomedially till sac and lacrimal crest is exposed.

Damage to orbital septum is avoided to prevent prolapse of fat. Sac is dissected away from lacrimal fossa. An opening in the bone, which was made Intranasally (with the help of endoscope), can be located.

This opening can be enlarged with help of 2 mm Kerrison bone punch, thereby creating bony ostium of around 15 mm × 15 mm size (Fig 2).

Soft Tissue Anastomosis

The sac is cut into anterior large flap and posterior small flap. With the help of endoscope, nasal mucosal flap is directed toward the sac (subciliary wound).

The anterior flap is anastomosed to nasal mucosa with 5.0 vicryl. The same procedure is repeated for posterior flap. Syringing is done. With the help of endoscope, water is seen coming out from the anastomosis (Figs 3 to 5).

Wound Closure

Subciliary incision is closed in layers by 6.0 vicryl.

Nasal Packing

Netcell is used for nasal packing and kept in place for 24 hours

Patient is followed up every month and evaluated with sac syringing for sac patency for first six months and the Following are the advantages over endonasal and external approaches:

ADVANTAGES

- With this technique, we get advantages of both endonasal and external DCR.
- A large osteotomy can be made.
- The flap can be sutured so that healing is achieved by primary intention, thereby decreasing chances of contracture formation of final soft tissue anastomosis.
- In this approach, lacrimal sac is approached from lower aspect, at nasolacrimal duct entrance, and ostotomy site is quite low, preventing any degree of Stump's syndrome.

Advantages over External Dacryocystorhinostomy

- Scar is not seen, as incision is subciliary. Subciliary DCR provides an excellent functional cosmetic scar outcome while retaining the access and advantages of external DCR procedure.³
- No chance of accidentally damaging nasal mucosa while making osteotomy.
- Bigger and planned nasal flap is available for suturing.
- Less chances of hemorrhage, epistaxis postoperatively.
- Less chances of injury to medial canthal ligament and angular vein.

Advantages over Endonasal Dacryocystorhinostomy

- Bigger bony ostium can be made so that bone can be removed externally also, through the subciliary wound.
- Flap can be sutured so that primary healing is achieved, thus less chances of fibrosis.

Fig 2 Suborbicularis oculi dissection & Sac exposure

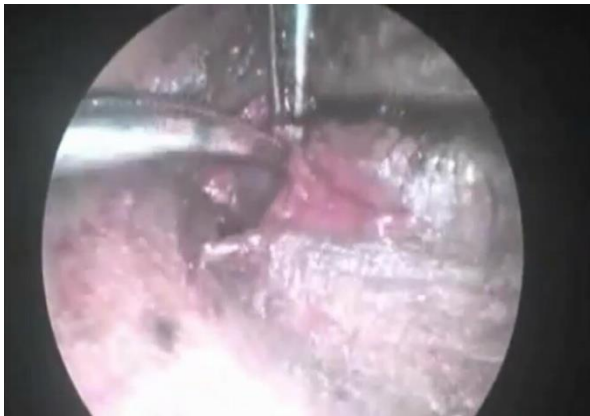
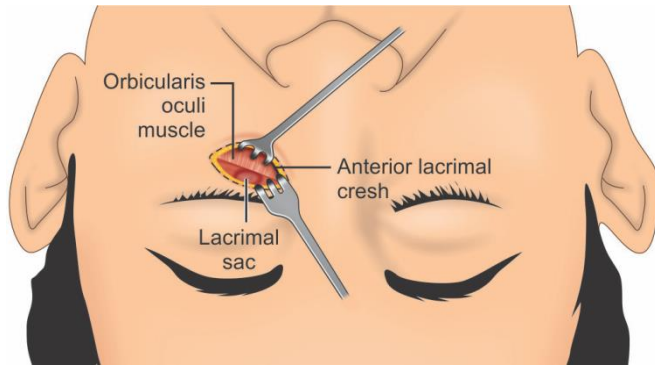


Fig 3 showing the incision

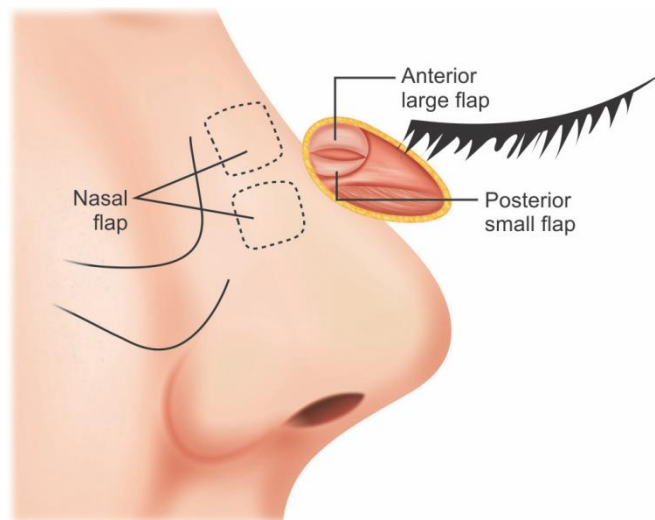


Fig 4 Anterior larger sac flap and posterior smaller sac flap are created

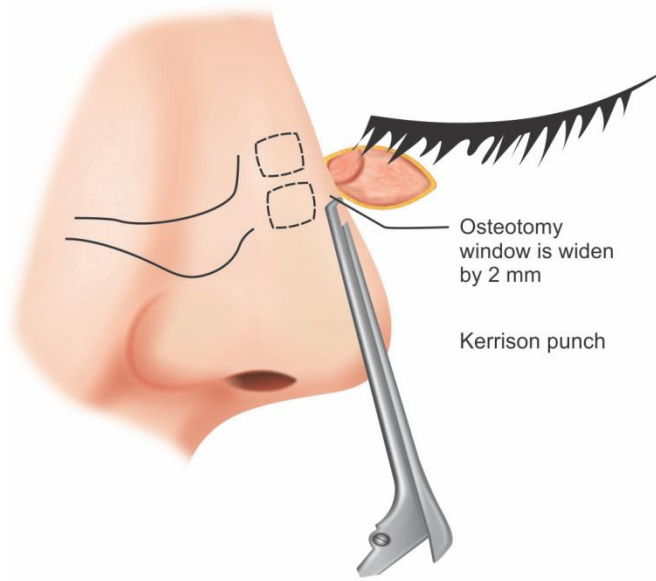


Fig 5 Ostium is further widened

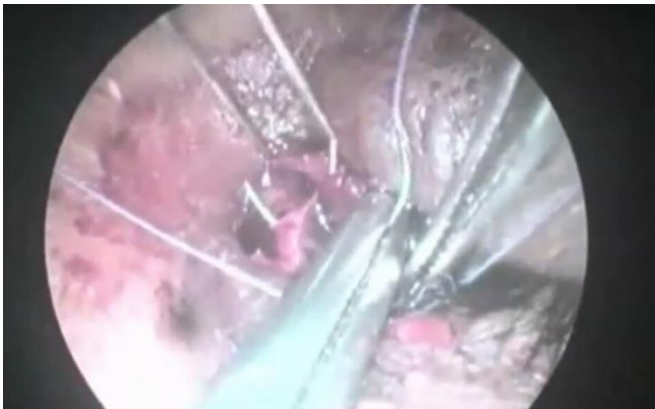

Fig 6 Suturing of the flaps

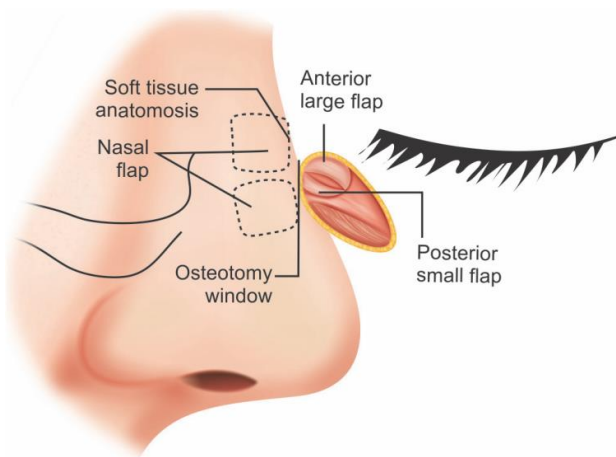


Fig 7 Final soft tissue anastomosis

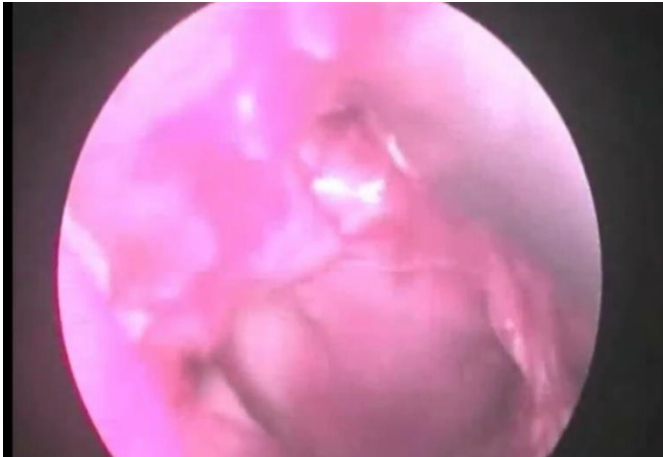


Fig 8 Final outcome

CONCLUSION

The common problems associated with DCR are recurrence. Endonasal DCR was four times more likely to fail compared to external DCR.⁴ Scar formation is seen in cases of external DCR, which have been tried to be minimized if a subciliary incision is used for the exposure of the lacrimal sac, thus helping to take a suture to keep the sac patent. Also as it is a subciliary incision, the scar healing is also cosmetically better than the traditional incision for external DCR.

Also combining the advantages of endoscopic DCR as well to the procedure makes this technique a valuable tool to tackle the problems of both the types of DCR.

This technique needs to be used extensively and patients followed up over a longer period to give substantial evidence of its efficacy and a study regarding the same is underway.

BIBLIOGRAPHY

- 1) Caldwell GW. Two new operations for obstruction of the nasal duct with preservation of the canaliculi and an incident description of a new lacrimal probe. *NY Med J* 1893; 57:581; *Am J Ophthalmol* 1893; 10:189.
- 2) Jokinen K, Karja J. Endonasal dacryocystorhinostomy. *Arch Otolaryngol* 1974; 100:41-44.
- 3) Dave TV, Javed Ali M, Sravani P, Naik MN: Subciliary incision for external DCR. *Ophthal Plast Reconstr Surg*; 2012 Sep-Oct;28(5):341-5
- 4) Anijeet D, Dolan L, MacEwen CJ. Endonasal versus external dacryocystorhinostomy for nasolacrimal duct obstruction. *Cochrane Database of Systematic Reviews* 2011, Issue 1. Art. No.: CD007097. DOI: 10.1002/14651858.CD007097.pub2

