



Coblation adenoidectomy our experience

Balasubramanian Thiagarajan Vrinda Balakrishnan Nair

Stanley Medical College

Abstract:

Aim of our study is to compare the efficacy and safety of coblation adenoidectomy versus conventional cold steel adenoidectomy. The study design included 40 children between age groups 4 – 8. Twenty of these children underwent coblation adenoidectomy while the other group of 20 underwent conventional cold steel adenoidectomy. The parameters taken into consideration for comparison included Post operative pain, operating time, intraoperative bleeding and presence of residual adenoid tissue 6 weeks after surgery.

In this study the coblation group demonstrated less post operative pain, less intraoperative bleeding and more complete removal of adenoid tissue. Operative time was found to be significantly higher in coblation group when compared to conventional cold steel adenoidectomy group.

Introduction:

Adenoid is the lymphoid aggregation seen in the nasopharynx. This tissue is a component of inner Waldeyer's ring. This tissue undergoes hypertrophy till the child reaches the age of 4 after which the proportional increase of the size of nasopharynx makes it appear reduced in size which

is followed by a reduction of symptoms. Adenoidectomy is the commonly performed surgery in children. As with any other surgical procedure there are complications associated with adenoidectomy. These complications are fortunately rare ².

Various methods of performing adenoidectomy include:

1. Conventional cold steel technique using curette
2. Bipolar coagulation under endoscopic vision
3. Adenoidectomy using microdebrider ³
4. Coblation adenoidectomy

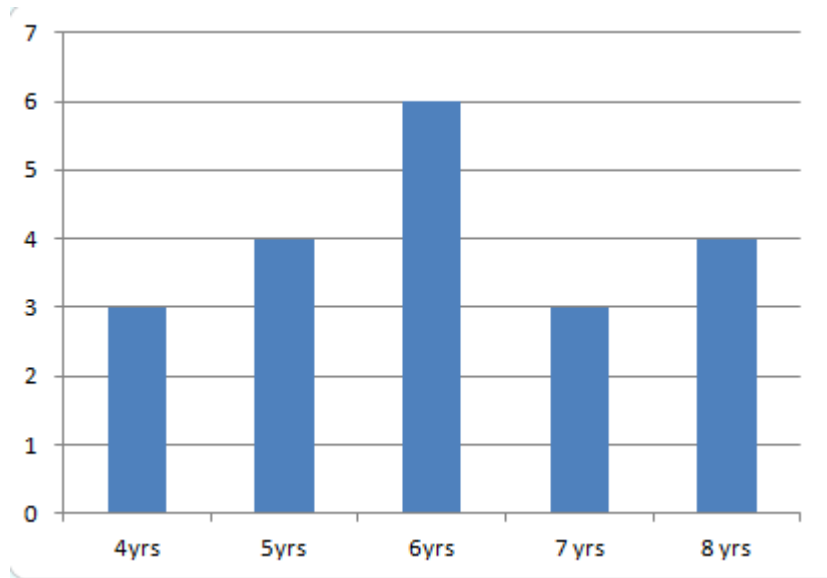
For purposes of classification and management adenoid hypertrophy has been graded according to the size of the tissue taking into consideration the relationship of the hypertrophied tissue with vomer, soft palate and torus tubaris ⁴.

Grade	Anatomical structure in contact with adenoid tissue
Grade I	None
Grade II	Torus tubaris
Grade III	Torus tubaris, Vomer
Grade IV	Torus tubaris, Vomer and soft palate at rest

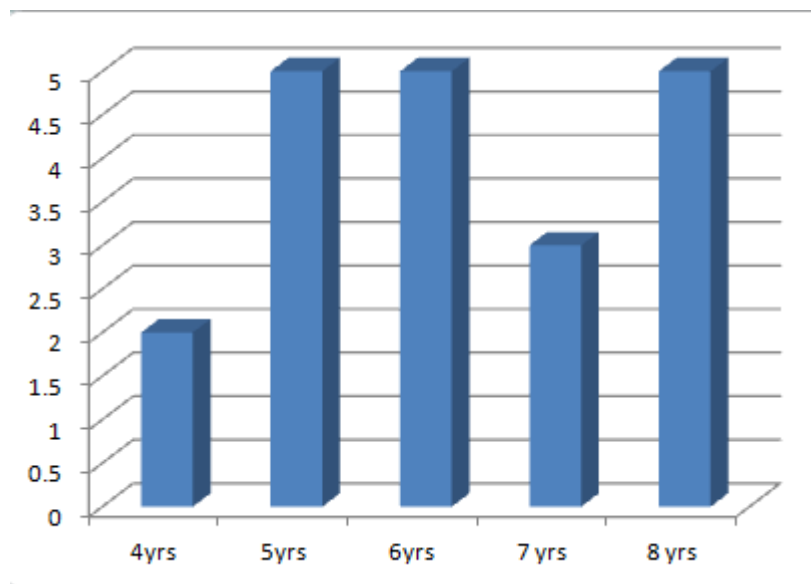
Materials and methods:

Pediatric patients of age group ranging between 4 and 8 were included in the study. Parents of the children taken up for study were not aware of the procedure followed during surgery. Patients were chosen randomly for the procedure by an intern by draw of lots. This random choice averted surgeon bias ⁵⁶. All the surgical procedures were performed by the same surgeon. Children with co morbid conditions like anemia, upper and lower respiratory infections were excluded from the study.

The size of adenoid tissue was graded using the grading system discussed above. Size of adenoid is assessed by performing diagnostic nasal endoscopic examination under topical anesthesia.



Age distribution of patients who underwent coblation adenoidectomy



Age distribution of patients who underwent cold steel adenoidectomy

Procedure:

Cold steel adenoidectomy was performed in a classic manner using conventional instruments. Blood loss is calculated by weighing the gauze pre operatively and post operatively. Gauze should be weighed before sending them for autoclaving.

Coblation adenoidectomy was performed by putting the patient in head up position. Soft palate is retracted by passing a soft rubber catheter via the nasal cavity. Adenoid tissue is visualized by passing a 0 degree 2.7 mm nasal endoscope. Oral cavity is kept open by using a Boyles Davis mouth gag. Tonsillectomy wand is bent in such a way that it could be passed under the soft palate. Coblation of adenoid tissue is performed under visualization. Adenoid is ablated till the prevertebral fascia becomes visible. Adenoid tissue behind the tubal orifice can also be ablated.

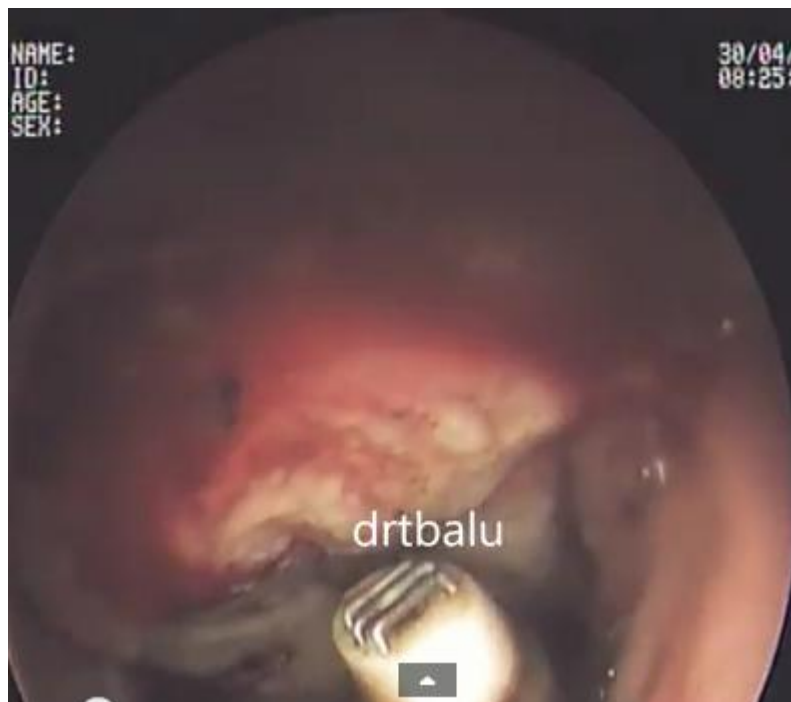


Image showing ablation of adenoid tissue using coblation

Result:

Bleeding after conventional adenoidectomy was higher than that of bleeding after coblation tonsillectomy. On an average blood loss following conventional adenoidectomy was 50 ml while it was 20 ml for coblation adenoidectomy.

Operating time of coblation adenoidectomy was significantly higher than that of conventional adenoidectomy. On an average it took 20 minutes to perform coblation adenoidectomy while it took just 5 – 7 minutes to perform conventional adenoidectomy.

Amount of residual adenoid tissue was assessed in both categories of patients by performing nasal endoscopy using 2.7 mm 0 degree nasal endoscope in all these patients. The amount of residual adenoid tissue was significantly higher in conventional adenoidectomy when compared to that of coblation technique.

Conclusion:

Coblation technique ensures complete removal of adenoid tissue with minimal bleeding. This helps in early resolution of secretory otitis media. Adenoid tissue present behind the tubal tonsil can also be removed safely using coblation technique. Coblation technique does not exert undue pressure over atlanto occipital joint because the patient is not put in Rose position and the wand also does not exert pressure over the area. Incidence of Grisel syndrome in both these groups will make an interesting study provided it includes a large study group.

References:

1. Gallagher TQ, Wilcox L, McGuire E, et al. *Analyzing factors associated with major complications after adenotonsillectomy in 4776 patients: comparing three tonsillectomy techniques*. *Otolaryngol Head Neck Surg* 2010;142:886-92
2. Regmi D, Mathur NN, Bhattarai M. *Rigid endoscopic evaluation of conventional curettage adenoidectomy*. *J Laryngol Otol* 2011;125:53-8
3. <http://www.ncbi.nlm.nih.gov/pmc/articles/PMC3266095/>
4. *Validation of a new grading system for endoscopic examination of adenoid hypertrophy* Sanjay R. Parikh, MD, Mark Coronel, MD, James J. Lee, MD, and Seth M. Brown, MD, New York, New York *Otolaryngology–Head and Neck Surgery* (2006) 135, 684-687
5. <http://www.ncbi.nlm.nih.gov/pubmed/18650626>
6. Horwitz RI, McFarlane MJ, Brennan TA, et al. The role of susceptibility bias in epidemiologic research. *Arch Intern Med*. 1985;145:909-912.