



**CHOLESTEROL GRANULOMA: AN UNCOMMON CLINICAL ENTITY OF THE  
MAXILLARY SINUS**

**Sunita Singh Sonia Chhabra Pansi Gupta Priya Malik**

Pt B.D. Sharma PGIMS, Rohtak, Haryana

***ABSTRACT***

Cholesterol granuloma (CG) is a foreign body reaction to the deposition of cholesterol crystals, usually found in association to chronic middle ear diseases, and highly uncommon in the paranasal sinuses. This article reports a case of a 30 year-old man, with complaints of postnasal discharge, cough and itching in bilateral ears. CT imaging showed polypoidal mass in left maxillary sinus. Endoscopic sinus surgery was performed, the cholesterol granuloma was removed from left maxillary sinus and tissue was submitted in our department for histopathological examination. It microscopically showed foreign body giant cell reaction to cholesterol crystals.

***INTRODUCTION***

Cholesterol granuloma is a histopathologic term describing numerous clefts after cholesterol crystals have dissolved during processing, with surrounding foreign body giant cells, foam cells and macrophages filled with hemosiderin, embedded in fibrous granulation tissue (1). Cholesterol granuloma (CG) can be found in several areas of the body, including middle ear (its most common site, usually associated to chronic middle ear diseases), mastoid process, breast, sella turcica, pontocerebelline angle, testis, lungs, brain, and kidneys and in the apex of the temporal bone pyramid (2). It has been considered a rare entity in the maxillary sinus. The diagnosis is difficult because the symptoms are usually non-specific (facial pain, yellow rhinorrhea, unilateral nasal obstruction) and endoscopic signs (a polyoid mass emerging from the ostio-meatal complex) and radiological features (a cyst-like or massive opacification of the maxillary sinus, bony erosion) cause problems in the differential diagnosis with other pathologies such as mucocele, non-secreting cysts, chronic sinusitis and in rare cases a malignant pathology of the maxillary sinus (3). The purpose of this paper is to report a case of

Cholesterol granuloma (CG) in the maxillary sinus of an adult, emphasizing the rarity and differential diagnosis of this lesion.

### ***CASE REPORT***

A 30 year old male presented with complaints of postnasal discharge, irritation throat, cough and headache, which was on and off in nature. CT imaging showed a polypoidal mass in left maxillary sinus (Fig.1). Endoscopic sinus surgery was performed on left maxillary sinus. Biopsy was sent for histopathological examination. Grossly, a grey brown polypoidal soft tissue piece measuring 1.2 x 0.8 x 0.4cm was received. Cut surface was solid and grey white to grey yellow. On microscopy, it revealed the cholesterol clefts surrounded by multinucleated foreign body giant cells in presence of neovascularisation and haemosiderin within a fibrous connective stromal tissue. Foam cells, macrophages and chronic inflammatory cells embedded in fibrous granulation tissue and respiratory epithelial remnants were also found (Figs. 2,3 and 4). These pathologic findings were consistent with those of cholesterol granuloma. The postoperative course was favourable.

### ***DISCUSSION***

There is a prominent male gender predilection for cholesterol granuloma, with a male to female ratio of 3:1, and it is more common in middle-aged patients (mean age = 38 years old; age range from 27 to 56 years). The patients usually present nonspecific symptoms, such as headache, facial pain, nasal discharge, rhinorrhea and sinusitis (2). It has been suggested that the pathogenesis of maxillary sinus cholesterol granuloma is due to three factors, namely, impairment of drainage, disturbed ventilation and hemorrhage into the sinus with hemolysis (4). The source of cholesterol is considered to be the cell membrane of erythrocytes destroyed during bleeding, that precipitates in a crystalline form, due to inadequate drainage. These crystals stimulate foreign body reaction that causes migration of leukocytes and macrophages, which will further give rise to foreign body giant cells (5,6). Additionally, connective tissue degeneration due to reduction of the ventilation, caused by osteomeatal complex obstruction by trauma and inflammatory products, can also contribute to form cholesterol crystals. Due to its pathogenesis, maxillary sinus cholesterol granuloma is often associated to a history of rhinitis, sinusitis, trauma and paranasal sinus surgery, especially because they can cause local bleeding focuses (2). Differential diagnosis of cholesterol granuloma should include allergic and inflammatory sinusoidal diseases, mucoceles, pyomucocele, and sinusoidal odontogenic and non-odontogenic cysts and tumors (2). Cholesterol granuloma is considered a non specific histopathological reaction to cholesterol crystals rather than a clinical or pathological entity. Histopathological analysis is essential for the final diagnosis of maxillary sinus cholesterol granuloma, as its clinical and radiographic characteristics are non-specific, but are important to complement diagnosis and treatment planning. Each sinonasal disease require specific approach. Apart from this, there is also the possibility of secondarily or primarily inflamed odontogenic lesions that show a foreign body reaction to cholesterol crystals in their capsule, possibly extending to the maxillary sinuses due to anatomical continuity (2).

The treatment of choice for maxillary sinus CG is surgical excision, usually through a Caldwell-Luc approach, but now the transnasal endoscopic technique has also been reported to be useful. Prognosis is good and recurrences are rare with effective treatment (2).

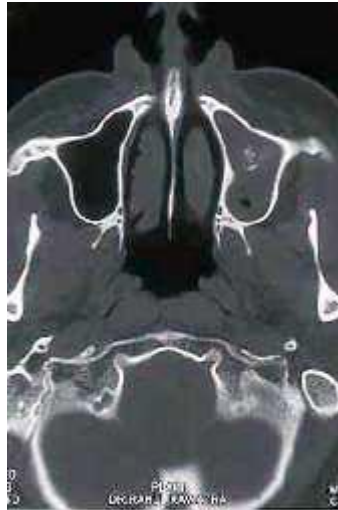

FIGURE I. Computed Tomography (CT Scan) showing opacification of the left maxillary sinus.

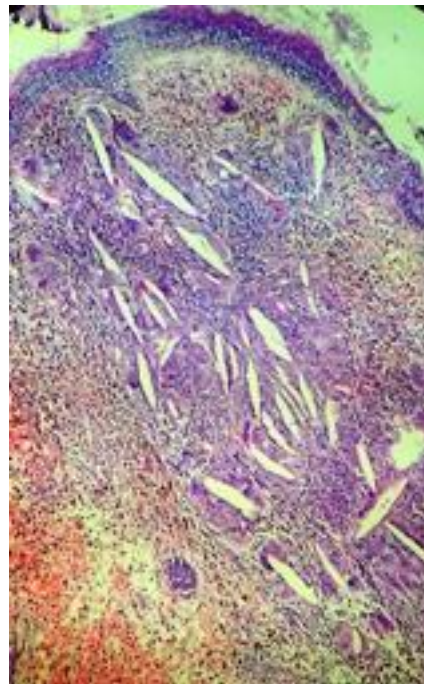


FIGURE II. Histopathology of cholesterol granuloma showing a dense connective tissue containing cholesterol clefts and intense chronic inflammatory infiltrate. HE. (original magnification x10).

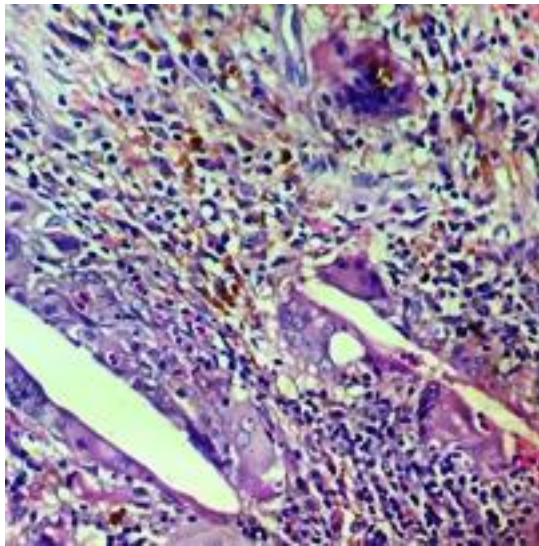


FIGURE III. Detail of histopathology of cholesterol granuloma highlighting cholesterol clefts surrounded by multinucleated foreign body giant cells. HE. (Original magnification x40).

#### **REFERENCES**

1. Kikuchi T, So E, Ishimaru K, Miyabe Y, Abe K, Kobayashi T. Endoscopic sinus surgery in cases of cholesterol granuloma of the maxillary sinus. *Tohoku J Exp Med* 2002;197:233-7.
2. Almada CB, Fonseca DR, Vanzillotta RR, Pires FR. Cholesterol granuloma of the maxillary sinus. *Braz Dent J* 2008;19(2):171-4.
3. Cassano M, Pennella A, Taranto FD, Limosani P, Simone M. Cholesterol granuloma of the maxillary sinus in a young patient with associated neurosurgical pathology. *Int J Ped Otorhinolaryngol* 2009;4(3):129-33.
4. Leon ME, Chavez C, Fyfe B, Nagorsky MJ, Garcia FU. Cholesterol granuloma of the maxillary sinus. *Arch Pathol Lab Med* 2002;126:217-9.
5. Milton CM, Bickerton RC. A review of maxillary sinus cholesterol granuloma. *Br J Oral Maxillofac Surg* 1986;24:293-9.
6. Bella Z, Torkos A, Tiszlavicz L, Iván L, Jóri J. Cholesterol granuloma of the maxillary sinus resembling an invasive, destructive tumor. *Eur Arch Otorhinolaryngol* 2005;262:531-3.

