

Case Reports: Gastrointestinal basidiobolomycosis in children.

Saleh M. Al-Qahtani, Ali M. Alsuheel, Ayed A. Shati, Nihal I. Mirza¹, Abdulwahab A. Al-Qahtani², Ahmad A. Al-Hanshani, Ahmed A. Al-Jarie³, Ibrahim A. Al-Zaydani³

Department of Child Health, College of Medicine, King Khalid University, Abha, Saudi Arabia

¹Department of Histopathology, Aseer Central Hospital, Arabia

²Department of Child Health, College of Medicine, Najran University, Saudi Arabia

³Pediatric Department, Aseer Central Hospital, Saudi Arabia

Abstract

Basidiobolus ranarum is a fungus found in the dung of amphibians, reptiles and insectivorous bats. It usually causes chronic subcutaneous infection of the trunk and limbs. Gastrointestinal basidiobolomycosis (GIB) is a rare disease. We report three children with this condition from the Southwestern of Saudi Arabia. All of them were treated with antifungals. One of them died and others recovered. All these patients had leukocytosis, marked eosinophilia and high erythrocyte sedimentation rate and the diagnosis of GIB was confirmed based on characteristic histopathological findings. GIB is an emerging disease in the Southwestern Saudi Arabia especially in children. Increasing awareness of GIB among healthcare professionals in areas of endemicity and appropriate specimen processing may lead to enhanced case detection and reporting.

Keywords: *Basidiobolomycosis, Gastrointestinal infection, children.*

Accepted July 15 2012

Introduction

Basidiobolomycosis is a rare fungal infection caused by *Basidiobolus ranarum*, an environmental saprophyte found worldwide. *B. ranarum* is a member of the order Entomophthorales of the class Zygomycetes. Basidiobolomycosis is usually cause subcutaneous infection that affects mostly young males, and it is transmitted through traumatic inoculation. Most cases have been reported from tropical and subtropical regions. While the diagnosis of subcutaneous disease is easy, the diagnosis of gastrointestinal basidiobolomycosis (GIB) is more difficult and its clinical presentation, risk factors and treatment are poorly understood [4]. Most of the cases of pediatric gastrointestinal basidiobolomycosis worldwide have been reported from Saudi Arabia [1-3, 6-8]. Here we are reporting three cases of GIB in Saudi patients with literature review.

Patients and Methods

Health records of three patients with basidiobolomycosis were retrospectively reviewed. These three patients were diagnosed between November 2009 and May 2012 at

Aseer Central Hospital, Abha, Saudi Arabia. Data collected included: demographic information, symptoms, signs, laboratory and radiological studies, procedures, treatment and outcome.

In all cases, the diagnosis was established based on the characteristic histopathologic findings. Specimens are received fixed in 10 % buffered formalin solution. The tissue can remain in it for long periods without deterioration and it is compatible with most special stains including immunohistochemical techniques. Formalin fixative, when used, must be 10 times the volume of specimen [5]. The specimen is carefully examined so as not to miss any of the material received. *Basidiobolus ranarum* form nodular masses at the gastrointestinal wall or even as separate abdominal masses which are usually confused by lymphoma, carcinoma or tuberculosis [1]. On cut section, these masses are grayish white and homogenous. Representative sections are taken from different parts of the masses and submitted in plastic cassettes for tissue processing. During tissue processing, the tissue is appropriately dehydrated and finally embedded in paraffin wax. Sections of 4µm are cut with a Leica sliding microtome. Slides are stained with haematoxylin and eosin stain [16]. Special histochemical

stains for highlighting fungi routinely used are Periodic Acid Schiff stain (PAS) and Grimelieus methamine silver (GMS) stain. Fungi stain magenta with PAS and black with GMS [5].

Pathologic tissues were examined for evidence of granulomatous inflammation, tissue eosinophilia, necrosis, fungal elements consistent with zygomycosis and structures showing the Splendore-Hoeppli phenomenon (radiating, intensely eosinophilic granular material surrounding the fungal elements) [17].

Results

Clinicopathologic Features

All our patients were healthy with insignificant past medical history. Case 1 is from Jazan province (Southwestern of Saudi Arabia) and the other cases are from Aseer province, Tohama area (Southwestern of Saudi Arabia) and these areas are known to be hot and humid.

The clinical, laboratory and surgical features of all patients are presented in Table 1.

Table 1: Clinicopathologic features of patients with gastrointestinal basidiobolomycosis

Case	Age (yrs)	Symptoms	WBC $\times 10/mm^3$	Eosinphils %	ESR mm/h	Radiological findings	Treatment	Follow-up
1	12	Abdominal pain Constipation Fever	17.60	35	99	Mass attached to the cecum and adjacent part of the terminal ileum	Hemicolectomy Itraconazole	Improved but Still under follow up
2	1 & 1/2	Fever	24.52	10.2	150	Liver abscesses	Itraconazole	Died shortly after admission
3	9	Abdominal pain Constipation Vomiting	17.8	14	76	Transverse colon mass	Itraconazole	Followed for 8 months and improved

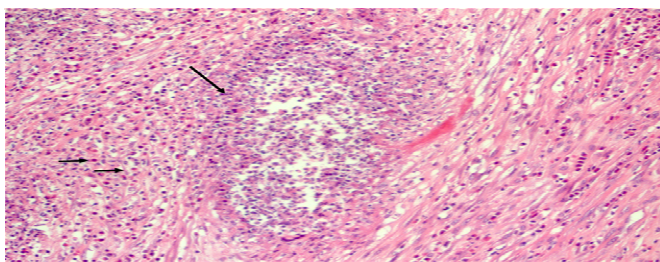


Figure 1. Microabscess (long arrow) surrounded by fibrosis and dense inflammatory infiltrate with marked increase of esinophils (short arrows). Original magnification x 200, haematoxylin and eosin stain.

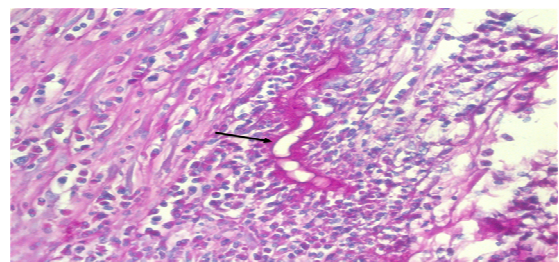


Figure 3. Fungal hyphae and zygosporangia of basidiobolomycosis. (original magnification x400, haematoxylin and eosin stain).

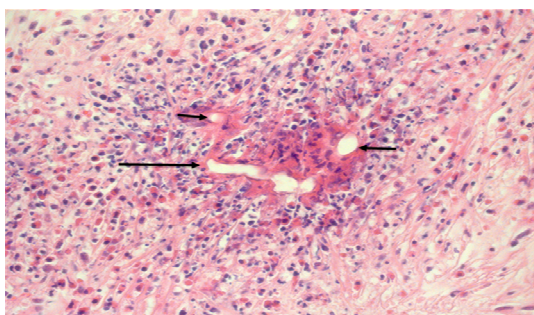


Figure 2. Fungal hyphae (long arrow) and zygosporangia (short arrows) of basidiobolomycosis. Note the eosinophilic amorphous material (Splendore- Hoeppli phenomenon) surrounding the fungal elements (original magnification x400, haematoxylin and eosin stain).

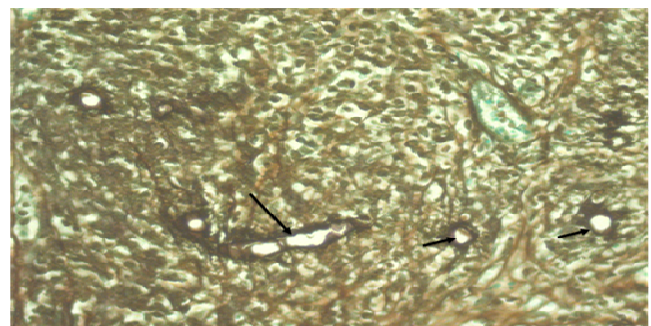


Figure 4. Basidiobolous ranarum hyphae (long arrow) and zygosporangia (short arrows) are stained black by Grimelieus methanamine silver stain, a histochemical stain. Original magnification x 400.

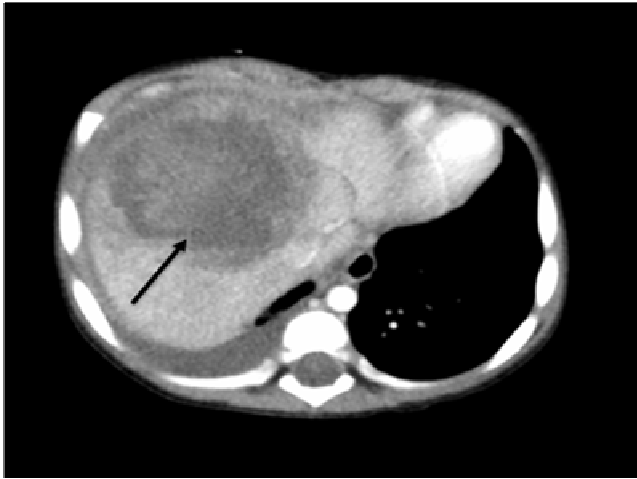


Figure 5. Contrast-enhanced CT scan of abdomen showed a large semi-liquid mass in the right lobe of the liver, suggestive of liver abscess.

Case 1

A 12 year old Saudi girl from Jazan area presented with constipation for one week and abdominal pain and distention for one month with loss of weight and poor appetite, associated with high grade fever in the last 2 weeks. She presented to private hospital and found to have a large mass in the right iliac fossa. Abdominal CT scan was done and showed large pelvic heterogeneous soft tissue density mass attached to the cecum and adjacent part of the terminal ileal loops and multiple enlarged regional lymph nodes. Her complete blood count showed the following, WBC $17600/\text{mm}^3$, with very high eosinophilia which was around 35%, she was anemic Hb 7.5 g/dL and had thrombocytosis $746 \times 10^3/\text{mm}^3$. Her erythrocyte sedimentation rate (ESR) was 99 mm/hour.

The patient was referred to our hospital and was taken to operation room for exploratory laparotomy as a case of intestinal obstruction with suspicion of lymphoma. A large mass was attached to the cecum and terminal ileum measured around 12 cm by 10 cm and right hemicolectomy was done. The resected part was sent to the histopathology department and the diagnosis of basidiobolomycosis was confirmed (Figure 1, 2, 3 & 4). She was started on intravenous itraconazole 100mg twice daily and the general condition of the patient improved few days after surgery and she was started on oral itraconazole then discharged to be followed at the outpatient clinic

Case 2

A 18 month old infant from Aseer province, (Tohama area) presented with fever for 3 weeks. He was spiking fever on daily basis reached 39°C . There were no other symptoms. He was admitted in local hospital for 2 weeks with neither improvement nor clear diagnosis. The parents left against medical advice and presented to our hos-

pital. He had tenderness in the right upper quadrant of the abdomen with hepatomegaly. His complete blood count showed the following; WBC $24,520/\text{mm}^3$ with 42.6% neutrophils, 39.5% lymphocytes, eosinophils 10.2% and monocytes 7.7%, Hemoglobin 7.4 g/dL and platelets $851 \times 10^3/\text{mm}^3$. His ESR was 150 mm. Broad spectrum intravenous antibiotics were started and abdominal ultrasound was done which showed picture of hepatic abscess. Abdominal CT scan was done and it showed a large semi-liquid - mass in the right lobe of the liver which has concentric wall compressed liver tissue, appearances highly suggestive of a liver abscess (Figure 5).

Percutaneous liver abscess drainage was done under ultrasound guidance, but there was no pus. A biopsy was taken from the mass and sent to the histopathology laboratory. On histology, transmural granulomatous inflammation composed of abundant eosinophils, and giant cells was seen. Histochemical stains revealed broad, non-septate, hyphae-like structures surrounded by an eosinophilic sheath (Splendore \pm Hoeppli phenomenon). Based on these specific histopathological features, the diagnosis of basidiobolomycosis was established. Immediately, he was started on intravenous itraconazole but his condition started to deteriorate and developed severe acute respiratory distress syndrome required intensive care management and high frequency ventilation. Unfortunately, with maximum cardiopulmonary support, he died shortly after. All of his sepsis screening was negative and the impression was multi-organ failure due to disseminated basidiobolomycosis infection.

Case 3

A 9 year old Saudi female from Aseer region (Tohama area) presented to medical attention with history of recurrent right hypochondrial pain and non bilious vomiting for four months. It was associated with on and off constipation. She was neither having fever nor weight loss. There was no diarrhea or jaundice. Her past medical history was unremarkable. She was looking unwell, afebrile and average body built. Systemic examination was normal. Initial laboratory workup showed WBC $17.8 \times 10^3/\text{mm}^3$, eosinophils 14%, Hb 9.7g/dL, Platelets $407 \times 10^3/\text{mm}^3$ and ESR 76 mm/hour with normal liver function tests. Abdominal CT-scan showed thickened walls of the colon in hepatic flexure region. She underwent colonoscopy which was suggested by the radiologist and was found to have a mass at the end of transverse colon fungating but couldn't be examined because it was oozing blood (Figure 6). A biopsy was sent, which was lately showed granulomatous inflammation around fungal structure that appear as empty spaces with thin wall surrounded by eosinophilic material (Spendore-Hoeppli phenomenon) with several multinucleated giant cells, which was characteristic for basidiobolomycosis. She was

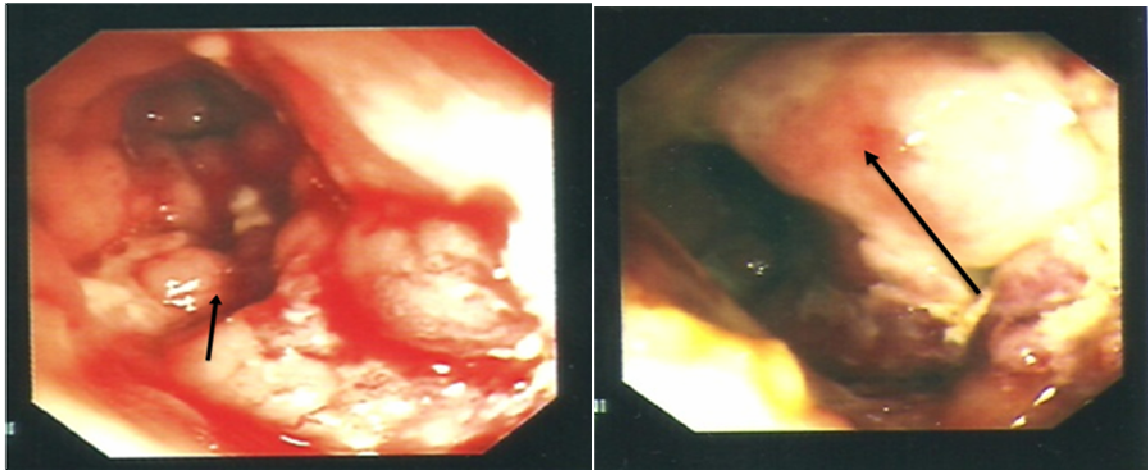


Figure 6. Colonoscopy study; a mass at the end of transverse colon fungating to the lumen and bleeding.

started on itraconazole. During outpatient follow up, she was responding completely with no symptoms and her ESR dropped to 12 mm/hour. After complete clinical and radiological improvement, itraconazole was discontinued after 8 months of treatment.

Discussion

Entomophthoromycosis is a rare form of zygomycosis. Two principal species responsible for the majority of these infections are *Conidiobolus coronatus* and *B. ranarum*. Historically, they have been known to cause skin and soft-tissue infections in otherwise healthy individuals in tropical areas of Africa, South America and Asia [10]. Visceral involvement is extremely unusual and so far has been reported only in association with *Basidiobolus*. *B. ranarum* was first isolated in 1955 from decaying plants in the United States and subsequently has been found in soil and vegetation throughout the world. *B. ranarum* may also be present as a commensal in the intestinal tracts of frogs, toads, turtles, chameleons, horses, and dogs. The first human case of infection caused by *B. ranarum* was one of subcutaneous mycosis, reported in 1956 in Indonesia and other cases subsequently occurred in India, Africa and South America [9].

Over 160 cases of subcutaneous mycosis have been described in the literature. It is presumed that many more cases have occurred and continue to occur but are not recognized or reported. The disease is widely prevalent in tropical and subtropical regions though it is sporadically reported from all parts of the world including Africa, Asia, the USA and Latin America [10]. The disease has been reported from most countries of Africa; where the majority of the cases have been described from Uganda in East Africa and from Nigeria in West Africa. Infections occur usually in children, less often in adolescents and

seldom in adults. About 90% of the cases have been seen in individuals under the age of 20 years, the youngest patient recorded being one year old and the oldest 60 years. The exact mode of transmission is not understood. It is postulated that *B. ranarum* on vegetation and organic debris is consumed by insects and other arthropods, which in turn are devoured by frogs, lizards and other animals. These animals then disseminate the fungus in the environment from where other animals and humans could be infected. Infections usually begin as small papules following a scratch or puncture by an insect, plant, or other fungus bearing object. Considering the ubiquity of the fungus in the environment, the prevalence of disease is very low. This may be due to widespread immunity resulting from previous subclinical infections or to the paucity of pathogenic strains of the fungus. The exposed parts of the body are most commonly affected but the neck and the head may be occasionally involved [10].

In 1978, the first culture-proven case of invasive basidiobolomycosis of the maxillary sinus and the palate was reported in the United States, and reports of visceral involvement followed. Before our report, there have been 46 cases of gastrointestinal basidiobolomycosis reported in the world [1, 2, 3, 7, 12, 13, 16].

Among these patients, 19 cases were pediatric mostly from Saudi Arabia (13 cases), Iran (3 cases), Brazil (2 cases) and others (1). Lyon et al reported 7 cases of GIB in adults and he mentioned that potential risk factors included prior ranitidine use and longer residence in Arizona [12]. Al-Jarie A, et al reported six cases of pediatric GIB, most of them where originating from the same area of our patients, Aseer-Tohama and Jazan provinces at the southwestern of Saudi Arabia [1]. In his conclusion, he mentioned that GIB is an emerging disease which should be included in the differential diagnosis of abdominal mass with eosinophilia. Also, he concluded that surgical

Gastrointestinal basidiobolomycosis in children.

resection of the infected tissue and prolonged treatment with itraconazole offer the best chance for curing the disease. In another study 5 cases of basidiobolomycosis in pediatric age group were reported, 3 cases were GIB, 1 case was pulmonary basidiobolomycosis and the last was nasal subcutaneous basidiobolomycosis [2]. All the 3 patients with GIB were treated surgically and given itraconazole and all showed good improvement on follow up. Of note, only 2 cases of nasal subcutaneous basidiobolomycosis were reported, one by Al-Jarie, A. et al. [2] and the second case was from India, 11 year old girl presented with bilateral nasal obstruction and discharge[15].

Table 2. *Clinical Manifestations, Sites of Involvement, and Preliminary Diagnoses in 19 children with Gastrointestinal Basidiobolomycosis*

Characteristic	Patients
Fever	15
Abdominal pain	14
Abdominal mass	6
Abdominal distension	5
Diarrhea	5
Constipation	4
Vomiting	4
Weight loss	3
Hepatomegaly	2
Organ involvement	
Colon/rectum	12
Liver/gallbladder	6
Small bowel	4
Stomach	1
kidney	1
Preliminary diagnosis	
Appendicitis/ appendicular mass	6
Malignancy	4
Crohn's disease	1

Another case of GIB was reported from Saudi Arabia, 2 year old presented with abdominal pain, vomiting, diarrhea, fever and palpable right iliac fossa mass. Laboratory investigations revealed elevated inflammatory markers and peripheral eosinophilia. Colonoscopy showed severely inflamed mucosa of the terminal ileum, cecum and ascending colon. CT scan of the abdomen demonstrated an inflammatory mass with wall thickening of the terminal ileum and colon. This case was mimicking fistulising Crohn's disease, which was treated surgically with voriconazole and he did well [3]. Three cases of pediatric GIB were reported from Iran. 1st case was 1.5 year old presented with diarrhea, abdominal pain, tenesmus, and hematochezia for 2 months, the 2nd presented with constipation and rectal bleeding and the 3rd was presented with Abdominal distention [4, 11]. All these 3 cases had leu-

kocytosis, eosinophilia, high ESR and same histopathological findings typical for basidiobolomycosis and all were treated with itraconazole after surgery and they did well [4, 11]. The 1st reported cases of pediatric GIB were from Brazil (two cases) and Nigeria (one case). Unfortunately all died possibly because of lack of information about the disease at that time [1, 7]. It is clear that most of those patients are previously healthy with no underlying diseases.

The clinical manifestations of childhood GIB include abdominal pain, fever, vomiting, diarrhea and weight loss. Most of pediatric GIB cases presented with fever and abdominal pain (Table 2), and may be this is the cause of suspicion of acute appendicitis or appendicular mass in 6 cases. The presence of abdominal mass was a common finding, either observed during abdominal examination, demonstrated by imaging or during laparotomy. Table 2 summarizes the clinical manifestations, sites of involvement and preliminary diagnoses in 19 children with gastrointestinal basidiobolomycosis [1, 2, 3, 4, 6, 7, 11].

All patients with GIB manifested with leukocytosis and striking eosinophilia. The mean of WBC was (20.68×10³/uL). The average eosinophil's percentage in 19 cases was 17.1% which mean that all have severe eosinophilia. The average ESR (mm/hr) in 16 patients was 99.9 which mean that, it was a characteristic in all cases of GIB. Such lab results should alert people in the medical fields to suspect basidiobolomycosis especially in the presence of clinical presentation suggesting the disease. In patients with GIB, the diagnosis was uncertain initially and was confused with malignancies, appendicitis or appendicular mass, Crohn's disease or liver abscess. However, the histopathological examination was the key in the diagnosis of all cases and fungus culture in some cases. This means that, in case of lacking lab capability to diagnose such rare disease, the diagnosis will be missed for sure and such patients are at risk of mortality and morbidity.

The special histopathologic characteristics of the disease are: marked tissue eosinophilia; granulomatous inflammation, microabscesses, necrosis and giant cells, presence of thin walled, broad, septate, irregularly branching hyphae and rounded zygosporoes and eosinophilic material (Splendore-Hoeppli phenomenon) surrounding fungal elements [17].

Definitive diagnosis is based on isolation of fungus from tissue specimens. The organism should be inoculated immediately because it does not survive at 4⁰C [1].

Serodiagnosis with immunodiffusion can be employed as an adjunctive diagnostic method; it is helpful both in diagnosis and in follow up of the patient. This test is very

specific for *B. ranarum* with no cross reactivity with other species of the order Entomophthorales, but its sensitivity, however, has not been determined [12]. Most patients were treated surgically which help to debulk the mass and make the medical treatment more successful. Most patient were treated with itraconazole with good outcome [1, 7, 12].

To conclude GIB is an emerging disease in Saudi Arabia. Most of pediatric GIB reported cases were from South-western of Saudi Arabia which mandate further researches to explore disease risk factors and nature towards better understanding of GIB. Increased awareness of GIB among healthcare professionals in areas of endemicity and appropriate specimen processing may lead to enhance case detection and reporting. Awareness of its clinical presentation, radiographic, endoscopic findings and characteristic histopathologic findings can facilitate prompt diagnosis and initiation of effective antifungal therapy.

Acknowledgement

We gratefully acknowledge the review of the manuscript by Prof. Mohammed Y. Khan (Professor of Family and Community Medicine, College of Medicine, King Khalid University) and Dr. Ahmad Al-Jarie (Consultant of Pediatric Infectious Diseases, Aseer Central Hospital) for his great effort in reporting most of pediatric GIB cases from Saudi Arabia which has great impact on patients care and increasing the knowledge and awareness for such rare disease. Also, we are indebted to Mr. Allan Agaton for typing the manuscript.

References

1. Al Jarie A, Al-Mohsen I, Al Jumaah S, Al Hazmi M, Al Zamil F, Al Zahrani M, et al. *Pediatr Infect Dis J*, 2003;22:1007-1013.
2. A. Al Jarie A, Al Azraki T, Al Mohsen I, Al Jumaah S, Almutawa A, Mohd Fahim Y, et al. *Basidiobolomycosis: Case series. Journal de Mycologie Médicale* 2011; 21, 37-45.
3. Saadah OI, Farouq MF, Al Daajani N, Kamal JS, Ghanem AT. *Gastrointestinal basidiobolomycosis in a child; an unusual fungal infection mimicking fistulising Crohn's disease Journal of Crohn's and Colitis*, 2012; 6: 368–372.
4. Fahimzad A, Karimi A, Tabatabaei SR, Zadeh MG. *Gastrointestinal Basidiobolomycosis as a Rare Etiology of Bowel Obstruction. Turk J Med Sci* 2006; 36(4): 239-241.
5. Imwidthaya P, Srimuang S. *Immunodiffusion test for diagnosing basidiobolomycosis. Mycopathologia* 1992; 118:127-131.
6. El-Shabrawi MHF, Kamal NM. *Gastrointestinal basidiobolomycosis in children: an overlooked emerging infection? Journal of Medical Microbiology*, 2011; 60: 871–880.
7. Vikram HR, Smilack JD, Leighton JA, Crowell MD, De Petris G. *Emergence of Gastrointestinal Basidiobolomycosis in the United States, With a Review of Worldwide Cases. Clinical Infectious Diseases Advance Access published March 22, 2012. http://cid.oxfordjournals.org/ at Saudi Digital Library on May 6, 2012.*
8. Wasim Yusuf N, Assaf HM, Rotowa NA. *Invasive gastrointestinal Basidiobolus ranarum infection in an immunocompetent child. Pediatr Infect Dis J* 2003; 22: 281-282.
9. Zavasky DM, Samowitz W, Loftus T, Segal H, Carroll K. *Gastrointestinal Zygomycotic Infection Caused by Basidiobolus ranarum: Case Report and Review Clinical Infectious Diseases* 1999; 28:1244-1248.
10. Gugnani HC, A review of zygomycosis due to *Basidiobolus ranarum*. *European Journal of Epidemiology*, 1999;15: 923-929.
11. Dworzack DL, Pollock AS, Hodges GR, Barnes WG, Ajello L, Padhye A. *Zygomycosis of the maxillary sinus and palate caused by Basidiobolus haptosporus. Arch Intern Med* 1978;138:1274-1276.
12. Marshall Lyon G, Smilack JD, Komatsu KK, Pasha TM, Leighton JA, Guarner G, et al. *Clinical Infectious Diseases* 2001; 32:1448–55.
13. Bigliazzi C, Poletti V, Dell'Amore D, Saragoni L, Colby TV. *Disseminated Basidiobolomycosis in an Immunocompetent Woman. J Clin Microbiol* 2004; 42(3): 1367-1369.
14. Khan ZU, Khoursheed M, Makar R, Al-Waheeb S, Al-Bader I, Al-Muzaini A. *Basidiobolus ranarum as an Etiologic Agent of Gastrointestinal Zygomycosis J Clin Microbiol*, 2001; 39 (6): 2360–2363.
15. Singh R, Xess, Ramavat AS, Arora R. *Basidiobolomycosis: a rare case report. Indian J Med Microbiol*, 2008; 26(3): 265-279.
16. Nemenqani D, Yaqoob N, Khoja H, Al Saif O, Amra NK, Amr SS. *Gastrointestinal Basidiobolomycosis: An Unusual Fungal Infection Mimicking Colon Cancer. Arch Pathol Lab Med*. 2009; 133: 1938-1942.
17. Hussein MR, Musalam AO, Aseery MH, Eid RA, El Motawa AM, Gamel AM. *Histological and ultrastructural features of gastrointestinal basidiobolomycosis. Mycol Res* 2007; 111(8): 926-930.

Correspondence to:

Saleh Al-Qahtani
Department of Child Health
College of Medicine, King Khalid University
Abha, Kingdom of Saudi Arabia