

Caroli's syndrome: A case report

Author(s): Rupali Bavikar and Rajesh Kulkarni

Vol. 15, No. 1 (2011-01 - 2011-06)

Rupali Bavikar and Rajesh Kulkarni*

Department of Pathology, SMT. K.N.Medical College, Pune, India

*Department of Pediatrics, B.J.Medical College, Pune, India

Abstract

We report a case of caroli's syndrome presenting at one year of age. The child had multiple cystic lesions in the liver communicating with intrahepatic bile ducts and multiple bilateral small cysts in kidney with congenital hepatic fibrosis diagnostic of caroli's syndrome.

Key words: Multiple cystic lesions; liver; kidney; congenital hepatic fibrosis

Acceptance August 13 2010

Introduction

Caroli's disease and caroli's syndrome are rare congenital disorders of the intrahepatic bile ducts. They are both characterized by dilatation of the intrahepatic biliary tree. The term caroli's disease is applied if the disease is limited to ectasia or segmental dilatation of the larger intra-hepatic ducts. In caroli's syndrome, malformations of small bile ducts and congenital hepatic fibrosis are also present. This process can be either diffuse or segmental and may be limited to one lobe of the liver, more commonly the left lobe. Caroli's disease is sporadic, whereas caroli's syndrome is generally inherited in an autosomal recessive manner.

Case report

A one year old child, born of non-consanguineous marriage, presented with history of fever and loose motions for 3 days and lump in abdomen noticed since 3 months. The lump was noted 3 months ago in left upper abdomen and had gradually increased in size since then. There was no history of icterus or any bladder bowel complaints. General examination revealed mild pallor, icterus was not present. On systemic examination, child was noticed to have splenomegaly (6 cm, firm) and hepatomegaly (3 cm, hard).rest of the systemic examination was normal.

Haemogram revealed hb of 6.6 gm/dl with normal differential wbc and platelet count. Peripheral blood smear was suggestive of microcytic hypochromic anaemia. Liver function tests including prothrombin time, serum albumin, and serum bilirubin were within normal limits. Serum ceruloplasmin was 35mg% (normal).kidney function tests were within normal limits. Oesophagogastroduodeno (ogd) scopy could not be done due to technical reasons. Ultrasound and ct abdomen showed multiple cystic lesions in the liver and multiple bilateral small cysts in kidney suggestive of caroli's disease.

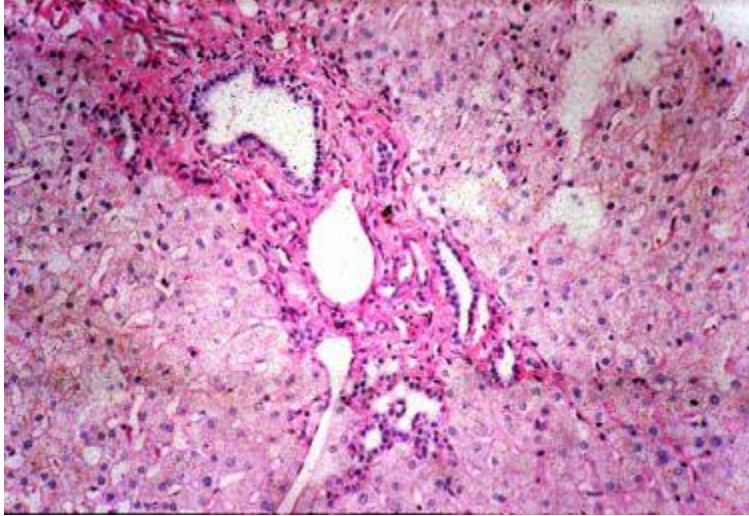


Figure 1. Dilated interlobular bile ducts with portal fibrosis.

Liver biopsy showed broad fibrocollagenous bands dissecting liver parenchyma into irregular lobules with hyperplastic and dilated bile ducts showing concretions or thrombi. Hepatic lobules showed islands of dilated bile ducts with surrounding fibrosis suggestive of congenital hepatic fibrosis with caroli's disease (Fig.1).

In view of the combination of caroli's disease (multiple cystic lesions in the liver communicating with intra-hepatic bile ducts and multiple bilateral small cysts in kidney) and those of congenital hepatic fibrosis the final diagnosis of caroli's syndrome was made.

Child was given intravenous fluids, vitamin k, broad spectrum antibiotics (pending cultures) and supportive treatment. Child was started on oral supplements of vitamin a, d, e and haematinics. Fever and loose motions resolved within 48 hours. Child was discharged home with advice to follow up every month.

Discussion

Caroli's disease was first known as a distinct clinical entity after Jacques Caroli reported a case in 1958. Caroli described two forms of this disease: the so called "pure form" of caroli's disease which occurs in a focal or diffuse manner, characterized by saccular, communicating intrahepatic bile duct dilatation and the second form, called as caroli's syndrome which has relatively less bile duct dilatation but is associated with hepatic fibrosis that results in portal hypertension and terminal liver failure. It is unclear whether the two types described by Caroli represent separate entities or a single disorder distinguished by hepatic fibrosis. Most (75%) of the patients are males and asymptomatic. If symptomatic, they present in childhood or early adulthood, generally less than 30 yrs of age due to the various complications associated with it. Depending on whether duct dilatation or portal hypertension is the predominant pathology, patients present with recurrent cholangitis or haematemesis respectively. Associated cystic dilatation of kidneys is seen in 60-80% of the cases (renal tubular ectasia, medullary sponge kidney, cortical cyst, recessive polycystic kidney disease or rarely autosomal dominant polycystic kidney disease). These patients are usually asymptomatic (as far as renal disease is concerned) but may develop renal stone disease and infections.

In our case, the child was diagnosed at a relatively young age. The physical examination findings of hard hepatomegaly and firm splenomegaly made us suspect the diagnosis which was then confirmed by ultrasound abdomen, CT abdomen and liver biopsy findings.

Caroli's syndrome is a developmental anomaly. It is related to ductal plate malformation at different levels of the intrahepatic biliary tree. On a genetic level, unbalanced translocation between chromosome 3 and 8 or the structural rearrangement of genes located therein seems to be responsible. This explains the familial clustering and its association with polycystic kidney disease (1). The natural history of caroli's disease diagnosed antenatally is unclear and there is an instance of regression of antenatally diagnosed localized caroli's disease. Hence a period of observation appears warranted (2).

Ultrasonography (us) is the initial investigation of choice.

The pure form shows diverticulum like sacculi of intra-hepatic biliary tree, more pronounced towards the center and can be segmental or generalized. One finding considered almost diagnostic of caroli's disease is "intraluminal portal vein sign" which consists of portal vein radicles surrounded by the dilated bile duct (3). Kidney may be normal or of variable echogenicity, depending on the extent of involvement by polycystic renal disease. In our case, us and ct abdomen showed multiple cystic lesions in the liver and multiple bilateral small cysts in kidney.

Ct scan is an invaluable adjunct that complements ultra-sound. It can identify cholangiocarcinoma and hepatic masses not identified by ultrasound. The diagnosis is more difficult to establish in the case of fusiform dilations of the biliary tracts and endoscopic retrograde cholangiopancreatography (ercp) is the gold standard in this situation. Ercp shows communication between the sacculi and bile ducts and diverticulum-like sacculi of the intra-hepatic biliary tree. In our case, ercp was not required.

Congenital hepatic fibrosis is a histopathological diagnosis. Histopathological intrahepatic bile duct ectasia and proliferation are associated with severe periportal fibrosis and confirm the congenital hepatic fibrosis component of "caroli's syndrome".

The treatment is primarily aimed at managing the associated complications of recurrent cholangitis, hepatic abscesses, biliary calculi and carcinoma. Recurrent cholangitis requires drainage which can be done by open surgery, positioning of an open stent or by percutaneous drainage. However this treatment is just palliative. Our patient had none of these complications during the current illness and hence did not require any treatment for the same. If the disease is confined to one lobe, partial lobectomy is the surgical treatment of choice (4).

In view of development of cholangiocarcinoma in 7% of these patients, the patients with bilobar disease should have regular clinical follow-up with ultrasound, and biopsy if required. Orthotopic liver transplantation appears to be an effective curative option for the treatment of these patients who cannot be operated radically (5).

References

1. Parada la, hallen m, hagerstrand i, tranberg kg. Clonal chromosomal abnormalities in congenital bile duct dilatation. Gut 1999; 45: 780-782.
2. Bratu i, laberge jm, khalife s,insky a. Regression of antenatally diagnosed localized carolis disease. J pediatric surg 2000; 35: 1390-1393.
3. Seth ak, chawla y, dhiman rk ,gupta s, suri s, dilawari jb . Carolis disease: a central dot means a lot. Trop gas-troenterol 1997; 18: 165-166.
4. Ammori bj, jenkins bl, lim pc, prasad kr, pollard sg, lodge jp . Surgical strategy for cystic diseases of liver in a western hepatobiliary centre. World j surg 2002; 26: 462-469
5. Waechter fl, sampaio ja, pinto rd ,vares-da-silva mr, cardoso fg, francisconi c, et al.. The role of liver transplantation in patients with carolis disease. Hepatogastroenterology 2001; 48: 672-674.