



## Broken tracheotomy tube: a case report

Sandeep Kumar Jha Jothiramalingam SB Jagadheesh Marthandam Thirunavukarasu

Chettinad Health Research Institute Chennai India

### Abstract:

A 24 year old boy was brought to the emergency department with the complaint that a piece of tracheotomy tube was missing. He had undergone tracheotomy 4 years back after a road traffic accident and has been quadriplegic and in altered sensorium since then. Chest x-ray revealed a piece of the tracheotomy tube in the right main bronchus which was subsequently removed with the aid of rigid bronchoscope. Post operative period was uneventful. The main aim of presenting this case report is to emphasize the importance of proper training of "at home" caregivers and adequately motivating them to continue doing so in long run.

### Introduction:

With the increased use of tracheotomy for airway control and management in patients having road traffic accident, cerebrovascular accidents, chronic obstructive pulmonary diseases, the onus of maintaining the tracheotomy tube in proper functioning condition is shifting greatly on the people who provide care at the home.

Such caregivers may not always be professional nurses. Many a times this work, voluntarily or out of compulsion is performed by the parents, siblings and relatives of the patient who usually are from non medical background with little or no knowledge of the subject.

In conscious, oriented patients, management is usually easier as they can express their problems and are able to seek out for help as and when required. Furthermore, such patients themselves learn to manipulate the tracheotomy tube to their convenience.

The problem arises in patients with quadriplegia and altered sensorium. Here we are presenting a case report where due to improper care one flange of the tracheotomy tube broke and was lodged in the right bronchus. The aim of the presentation is to highlight the importance of sensitizing the home care providers about the risks associated with tracheotomy care and to make them take care of such patients in a more responsible way.

#### Case report

A 24 year old male was brought to the Emergency room of Chettinad Health Research Institute, Kelambakkam, at 12:00 noon with the complaint of dislodgement of tracheostomy tube and dyspnoea since morning.

On enquiry the patient's father told that his son had an accident 4 years back when he suffered a subdural haematoma. He underwent a craniotomy for that and was tracheotomised subsequently for the maintenance of the airway. He has remained in a state of altered sensorium since then with the airway being managed on the tracheotomy tube. He was being nursed at home by his parents and relatives.

On the day of presentation the father noticed his son to be breathing with unusually extra effort. He tried to check the tracheotomy tube and found it to be dislodged with one of the flanges missing. The man was rushed to the hospital at this instant.

On examination a 24 year old man in altered sensorium with laboured breathing marked by subcostal retractions was seen. His pulse rate was 100/min, regular and blood pressure was 100/70 mm Hg. Pulse oximetry showed SpO<sub>2</sub> of 95%, with respiratory rate of 24 min.

An urgent X-ray chest was performed in the emergency room which showed a metallic density foreign body to be lodged in the right bronchus [fig.1].

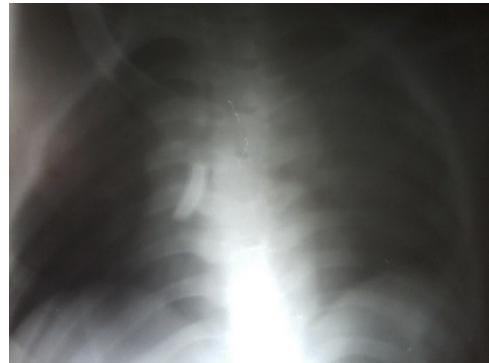


Fig. 1: A radiopaque shadow in the area of the right bronchus. The Xray film taken is not of a good quality due to inability to hold the patient in a steady position.

At this point anaesthetic consultation was sought. Intravenous fluid support was started. Foreign body was removed with the aid of rigid bronchoscope under minimal sedation with midazolam through the tracheotomy opening [fig 2]. Post removal, a portex size 7.5 cuffed tracheotomy tube was inserted and secured.



Fig. 2: The Broken Tracheostomy tube with the broken piece remove from the right bronchus.

The patient was thereafter kept under observation for next few days. Intravenous Ceftriaxone and Metronidazole were administered for 2 days. The patient subsequently stabilized but there was no improvement in his sensorium. He was subsequently discharged in a hemodynamically stable condition.

Before discharge the father and brother were counselled in detail about the requirement of proper tracheostomy care in such patients and offered professional help in the form of a trained nurse for home care. They were also explained and trained in proper care and periodic changing of tube.

#### Discussion

With the increased use of tracheotomy to maintain airway in a diverse group of patient with risk of airway compromise, the requirement for proper education of attendees has also emerged. A lack of proper care by attendees results in a variety of complications like infections, dislodgement, and fractures of tracheotomy tube as reported in this case report.

One of the earliest published records for a similar complication was reported by Howarth W in 1913 [1]. In this case the patient just walked into the hospital asking for a tube replacement. On examination it was noticed that a flange of the tube was missing. It was located in the right bronchus by X-ray and removed under cocaine anaesthesia. A similar case was also reported by Bassoe in 1960 [2].

Majid in 1989 [3], Malhotra and Kallan [4], and Patorn et al [5] reported similar cases. They used fibre optic bronchoscopes to remove the dislodged flanges. They evaluated the various causes that may be the potential trigger factors for such catastrophe. It was suggested that tracheotomy tube due to its manufacturing design had some weak points like junctions between the tube and the neck plate, the distal end of the tube and the fenestration site. In our case the tube broke at the point where the two flanges start [fig 2]. Prolonged wear, ageing of the tubes and repeated sterilization were proposed as risk factors of a fractured tracheostomy tube [6, 7]. Furthermore the corrosive action of tracheo-bronchial secretions on the tube was implicated to cause weakening of the tube which may lead to its breakage [8, 9]. On repeat enquiries patient's fathers revealed the patient didn't have a tube cleaning or change for past 3 months. This may have exposed the tube to corrosive tracheal secretions which may have subsequently led to its breakage.

Considering the various causes of breakage of tracheostomy tube recommendations were made by various authors to avoid it [4, 10, 11]:

1. Periodic change of tracheostomy tube, preferably 3 monthly.
2. Daily or alternate day cleaning of inner cannula depending on nature of the patient's secretions.
3. Keep the tube site clean.
4. Tube ties should be changed weekly.
5. Alternative use of two sets of inner cannula may reduce wear and tear of the tube.
6. Patients should be periodically followed up at the nearest hospital.
7. Proper training should be provided to the caregivers. This is especially important in case of patients like the one in this case report because such quadriplegic patients with altered sensorium are unable to seek help when in distress and are therefore at a greater risk of ending up with a fatal complication of such misadventures.
8. In the case of an emergency, immediate hospital contact and a good referral system are critical for the early detection and management of these complications.

Apart from these points the psycho socioeconomic aspect of such caregivers needs to be emphasized. Though it may be easy to provide proper care for such patients in hospital, it may not be that easy for the caregivers to do the same at home.

Furthermore a quadriplegic patient like this demands more time consuming care from his caregivers, which may at times may not be feasible due to various social and economic obligations.

So it is very important to evaluate these aspects and chose a proper caregiver who can devote adequate time for this. In case it is difficult to find such a person, alternative arrangement in the form of a nurse, or admission to a hospice may have to be looked into.

#### Conclusion

Tracheotomy, though a life saving procedure in many cases is a potential life threatening condition if not managed and followed up carefully as it directly involves the airway. This especially holds true in the patients like the one reported here who are physically and mentally unable to seek help in case of impending disastrous complications. Furthermore socioeconomic condition of the caregivers at home may not always allow for a dedicated care to be given as required by current medical standards.

It therefore becomes imperative on the part of the doctor who is discharging the patient from the hospital to clearly and carefully explain and train the home caregivers in proper management of such patients on prolonged tracheotomy. Furthermore, the doctor should feel duty bound in such cases to assess the socioeconomic profile and capability of the caregivers to be able to provide adequate care. In case of any doubt alternative arrangements like a nurse, care under supervision or prolonged stay at the hospital or hospices may be suggested so that such dramatic tragedies are avoided.

## References

1. Howarth W. Piece of Broken Tracheotomy Tube removed from the Right Bronchus. *Proc R Soc Med.* 1913; 6(Laryngol Sect):99.
2. Basoe HH, BOE Broken tracheotomy tube as a foreign body. *JLancet.* 1960 May 7; 1(7132):1006-7.
3. Majid AA. Fractured silver tracheostomy tube: a case report and literature review. *Singapore Med J.* 1989 Dec; 30(6):602-4.
4. Malhotra B, Kallan BM. An unusual foreign body in tracheobronchial tree: removed by fiberoptic bronchoscope. *Indian J Chest Dis Allied Sci.* 1993 Apr-Jun;35(2):85-8.
5. Patorn P, Pirochchai, Piyawadee Lertchanaruengrit, Patravoot Vatanasapt, Teeraporn Ratanaanekchai, and Sanguansak Thanaviratananich. Fractured metallic tracheostomy tube in a child: a case report and review of the literature. *J Med Case Reports.* 2010; 4: 234.
6. Okafor BC. Fracture of tracheostomy tubes. Pathogenesis and prevention. *J Laryngol Otol.* 1983;97:771-774.
7. Gupta SC, Ahluwalia H. Fractured tracheostomy tube: an overlooked foreign body. *J Laryngol Otol.* 1996;110:1069-1071.
8. Gana PN, Takwoingi YM. Fractured tracheostomy tubes in the tracheobronchial tree of a child. *Int J Pediatr Otorhinolaryngol.* 2000;53:45-48. doi: 10.1016/S0165-5876(00)00291-3.
9. Srirompotong S, Kraitrakul S. Fractured inner tracheostomy tube: an unusual tracheobronchial foreign body. *Srinagarind Med J.* 2001;16:223-225.
10. Krempl GA, Otto RA. Fracture at fenestration of synthetic tracheostomy tube resulting in a tracheobronchial airway foreign body. *South Med J.* 1999 May;92(5):526-8.
11. Irfan Iqbal, M. Lateef, Asif A. Wani, and Sheikh Rafiq. A Rare Case of Foreign Body Bronchus: A Case Report. *Indian J Otolaryngol Head Neck Surg.* 2011 July; 63(Suppl 1): 81-82.