



Black Hairy Tongue: A Case Report

Isabel Gonçalves A*, Carção A, Duarte D, Vilhena D

Otorhinolaryngology Service of Pedro Hispano Hospital, Matosinhos, Portugal

***Corresponding author:** Isabel Gonçalves A, Otorhinolaryngology Service of Pedro Hispano Hospital, Matosinhos, Portugal, Tel: +351932792516; E-mail: gc.anaisabel@gmail.com

Received date: January 29, 2020; **Accepted date:** March 05, 2020; **Published date:** March 12, 2020

Abstract

Black hairy tongue is a benign clinical condition, usually asymptomatic and with an excellent prognosis. It is characterized by a black/brownish pigmentation of the filiform papillae of the lingual dorsum, which are hypertrophied. We describe a case of hairy tongue in a 65-year-old male, referred to the otorhinolaryngology consultation for presenting, with 1 month of evolution, notion of alteration of the tongue pigmentation, as well as complaints of oral discomfort and xerostomia. He was an active smoker of 42 pack-years and used a dental prosthesis. At the objective examination, the evident elongation of the filiform papillae of the posterior two thirds of the lingual dorsum, with black colour, hairy appearance and not detachable, was highlighted. The patient was advised to strengthen oral hygiene, combined with smoking cessation, as well as adjunctive oral nystatin. He was evaluated after 5 weeks of medical treatment and smoking cessation, with complete resolution of the hairy tongue. The diagnosis of black hairy tongue, as a clinical diagnosis, involves anamnesis and clinical examination of the oral cavity. Although the aetiology is not clear, multiple factors that predispose to its onset are known, the most frequent being smoking and alcohol, tea and coffee consumption. In the suspicion of black hairy tongue it is essential to explore the existence of any predisposing factors. In most cases, the avoidance of causative agents associated with an enhanced oral hygiene is sufficient to resolve this clinical condition. In the absence of clinical improvement, lingual biopsy and surgical treatment are indicated.

Keywords:

Black hairy tongue, Hairy tongue, Black tongue, Tongue diseases, Mouth diseases

Introduction

Black hairy tongue is a benign clinical condition, usually asymptomatic and with an excellent prognosis [1,2]. It has a prevalence ranging from 0.15% to 11.3% in the general population and its incidence increases with age, so that in children and young adults the prevalence is around 8.3%, while in other groups, as in the case of drug addicts, the prevalence can reach 57% [1-8]. It is more frequently reported in males [6,8]. A black hairy tongue is characterized by a black/brownish pigmentation of the filiform papillae of the lingual dorsum, which are hypertrophied [1-8]. This elongation of the filiform papillae appears to be associated with the absence of an adequate peeling of the keratin layer on them, with consequent hyperkeratosis [1,6]. The filiform papillae, with an usual average length estimated to be less than 1 mm, can reach between 12-18 mm in length and a width of about 2 mm. The diagnosis of hairy tongue is established with a papillary length >3 mm. Hypertrophy of the papillae creates an environment conducive to the growth of microorganisms (most often bacteria or fungi), by facilitating the retention of food debris and of bacteria and/or fungi in the interpapillary space [6]. There are no bacteria or fungi specifically associated with this condition, but *Candida* spp. and *Aspergillus* spp. can exacerbate it [5,6]. The dark colour of the tongue, which is associated with the intrinsic oral environment,

combined with an increase in the papillary size, gives the lingual dorsum a hairy appearance [6].

Usually, being mostly an asymptomatic condition, patients seek medical attention exclusively for aesthetic reasons [1,3,6]. When symptomatic, the most frequently reported complaints are glossodynia, dysgeusia and halitosis [1,3,6,7].

The pathogenesis of black hairy tongue is not fully understood yet, but it is associated with some factors that interfere, in some way, with the environment of the oral cavity [1,3,6,8]. The most frequently associated factors are smoking and alcohol, tea and coffee consumption. The use of oral mouthwashes with hydrogen peroxide has also been implicated, the abuse of intravenous drugs through a mechanism that has not yet been clarified, as well as immunosuppression states such as oncological pathologies and HIV infection [2,6,8]. Pasty diets, especially in elderly patients or in cases of dysphagia, can also be associated, since there is a lower rate of flaking of the lingual dorsum in these patients due to the absence of roughly textured foods, with the accumulation of keratin on the lingual surface [6]. Likewise, the association between trigeminal neuralgia and hairy tongue is also described in the literature, due to the chewing difficulty caused by the pain, thus reducing the mechanical stimulus for the normal peeling of the tongue's surface [2,6]. Conditions that cause xerostomia, as post-radiotherapy states and certain autoimmune pathologies, such as Sjogren's Syndrome, also predispose to the appearance of black hairy tongue [6]. It is common in the literature the description of cases of black hairy tongue that appear after taking certain antibiotics and antipsychotics and that resolve after its suspension, but the pathophysiological mechanisms are not fully known [1,4,9-12].

Case Report

A 65-year-old male patient presented to an otorhinolaryngology consultation due to the notion of alteration in tongue pigmentation, with about 1 month of evolution and associated complaints of oral discomfort and xerostomia. Previously it was observed in a dental medicine consultation, having completed 15 days of oral topical nystatin, without any perceived improvement and still without an

established clinical diagnosis. He denied any other symptoms, namely tongue pain, halitosis, heartburn, odynophagia or dysphagia.

As a medical background, he had dyslipidemia and psoriasis. As a surgical history, he had undergone tonsillectomy in childhood and inguinal hernioplasty about 20 years earlier. He was medicated with atorvastatin. Regarding habits, he was a smoker of 1 pack/day for 42 years (42 pack-years) and he reported drinking 2 glasses of red wine per day, about 2-3 coffees and 1 cup of tea daily at bedtime.

The objective examination of the oral cavity revealed the total absence of teeth and the use of a total dental prosthesis in the upper and lower dental arches, according to the patient for about 10 years. It was evident the significant elongation of the filiform papillae of the posterior two thirds of the lingual dorsum, with a black colour and not detachable, giving the tongue a hairy appearance (Figure 1). No lesions were identified in the oral cavity. The remaining ENT examination was normal.

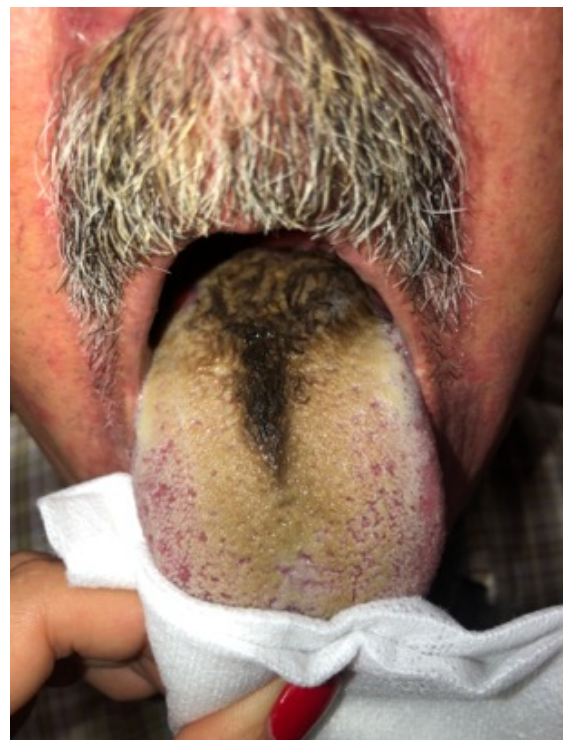


Figure 1: Characteristic appearance of black hairy tongue before medical treatment

The medical treatment consisted of an oral hygiene strengthening, through the use of an antimicrobial mouthwash (without hydrogen peroxide in the composition) 2 times a day and the use of a tongue

scraper during tooth brushing, performed with a frequency of 3 times a day, after the main meals. The eviction of agents that predispose to the clinical condition, in this case smoking, alcohol, coffee and tea, was another measure instituted, as well as an increase in the daily water intake. Oral topical nystatin was also prescribed as an adjuvant treatment.

Two weeks after the beginning of the treatment and the cessation measures, all fulfilled by the patient, he noticed an improvement in oral discomfort and xerostomia. On objective examination, a slight decrease in the hairy appearance was noted, with improvement in the anteroposterior direction (Figure 2). The patient was encouraged to maintain the medical therapy, as well as the measures of smoking, alcohol, tea and coffee avoidance, and was reassessed again after 5 weeks of treatment, when it was possible to notice a normal appearance of the tongue, with no longer a black and hairy appearance (Figure 3). The patient was asymptomatic.

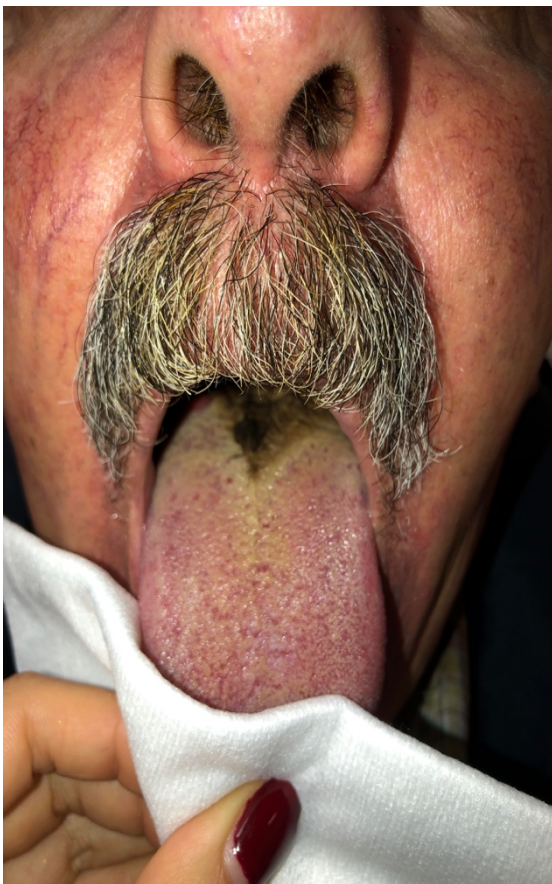

Figure 2: Improvement of black hairy tongue after 2 weeks of treatment

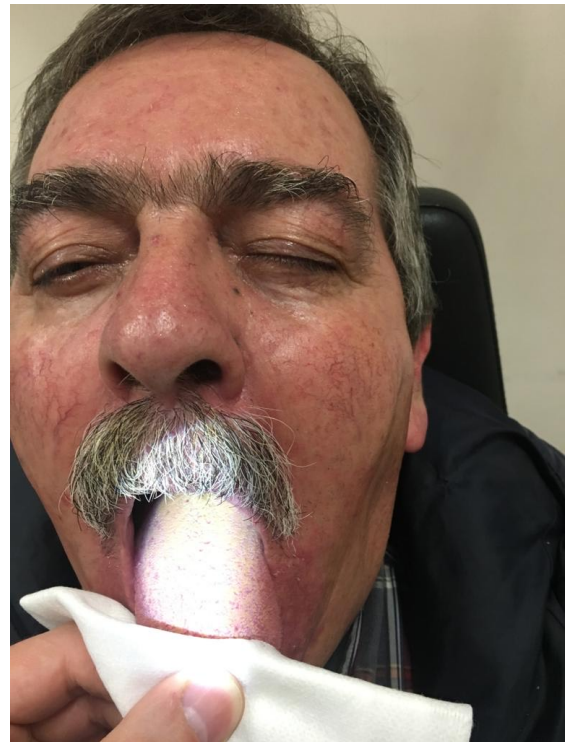

Figure 3: Tongue with a normal appearance after 5 weeks of treatment

Discussion/Conclusion

Black hairy tongue consists of a clinical diagnosis, established, as in this case, through anamnesis and objective examination of the oral cavity [1-8]. Although the appearance of black hairy tongue is quite characteristic, as in the case described, whenever the objective examination is not so clear or there is not an aspect of lingual hairiness it is important to establish the differential diagnosis, especially with some pathologies that can be associated with dark pigmentation of the tongue, such as the pseudo-black hairy tongue caused by bismuth subsalicylate, melanoma, oral melanoacantoma, smoker's melanosis (melanocytic pigmentation), Addison's disease, hemochromatosis, acanthosis nigricans, Peutz-Jeghers syndrome, Laugier-Hunziker syndrome, as well as metals' deposition if the clinical history is suggestive of this possibility [3,6,8]. In children, the pathologies most frequently associated with a black colour of the tongue are congenital lingual melanocytic macules and congenital melanocytic nevus [6]. Although hairy tongue is more often associated with blackish or brownish coloration of the tongue, pigmentation can, in rare cases, be yellowish or greenish [3,6]. In these situations, it can

be difficult to differentiate from oral leukoplakia, characterized by white, adherent and hardened plaques [6]. In addition, patients with potentially premalignant or malignant pathology of the oral cavity often present risk factors similar to those involved in the black hairy tongue, such as tobacco and alcohol consumption. Since there is a 2-3% risk of malignant transformation of oral leukoplakia, lingual biopsy should be performed in case of diagnostic doubts [6].

First-line medical treatment involves a good oral hygiene, with daily brushing of the tongue with a tongue scraper, in order to promote the desquamation of the hyperkeratotic papillae. There must be an avoidance of all potential agents involved, such as tobacco, alcohol, coffee, tea and oxidizing mouthwashes, which should be replaced by antimicrobial mouthwashes without oxidizing constituents [1-8]. Topical application of sodium bicarbonate or 3% sodium peroxide is also described as beneficial [6]. The maintenance of a good hydration with increased water intake and the consumption of foods with solid consistency and rough texture are also associated with an improvement [1,6]. As a second therapeutic line, we advocate the use of oral topical antifungals, keratolytic agents and retinoids. In the case described, oral topical nystatin was prescribed due to the possibility of fungal superinfection in the interpapillary space. The resolution of this clinical condition is described in the literature in variable periods ranging from 4 days to 2-4 weeks [2-5]. In this case, the resolution of black hairy tongue was verified when the patient was reevaluated after 5 weeks of medical treatment, having occurred in a

variable period between the previous evaluation at 2 weeks and the last evaluation at 5 weeks. In the absence of improvement with medical therapy, surgical excision of the hypertrophied filiform papillae can be performed using CO2 laser techniques, hot dissection techniques or even cold dissection [1,3,8].

References

1. Oliveira EH, Rodrigues Coelho IL, Bezerra MM, et al. Diagnóstico de língua pilosa negra durante campanha de prevenção ao câncer de boca. *Int J Dent*. 2010;9(1):44-7.
2. Del Barrio-Díaz P, Meza-Romero R, Vera-Kellet C. Black hairy tongue. *J Gen Intern Med*. 2017;32(11):1266.
3. Boleto D. Pêlos na língua - um caso de língua pilosa negra. *Rev Port Med Geral Fam*. 2013;29:255-7.
4. Hamad Y, Warren DK. Black hairy tongue. *N Engl J Med*. 2018;379(10).
5. Kriem S, Peretz A, Blum A. Língua villosa nigra. *IMAJ*. 2017;19:131.
6. Schlager E, St Claire C, Ashack K, Khachemaune A. Black hairy tongue: predisposing factors, diagnosis and treatment. *Am J Clin Dermatol*. 2017;18(4):563-9.
7. Nisa L, Giger R. Black Hairy Tongue. *Am J Med*. 2011;124(9):816-7.
8. Handler MZ. Hairy Tongue. *Medscape*. 2018 [acedido a 8 de novembro de 2019].
9. Balaji G, Maharani B, Ravichandran V, et al. Linezolid induced black hairy tongue. *Indian J Pharmacol*. 2014;46(6):653-4.
10. Kanodia S, Giri VP, Shankar VN. Black hairy tongue with olanzapine: A rare case report. *Indian J Psychiatry*. 2017;59(2):249-50.
11. Pigatto PD, Spadari F, Moroni L, et al. Black hairy tongue associated with long-term erythromycin use. *J Eur Acad Dermatol Venerol*. 2008;22:1269-70.
12. Tamam L, Annagur BB. Black hairy tongue associated with olanzapine treatment: a case report. *Mount Sinais J Med*. 2006;73:891-4.