



Atypical clinic of foreign objects in the Maxillary Sinus ; Cluster-Type Head- ache

YAZICI ZM., GÜLÜSTAN F., ALAKHRAS W., ÇELİK M., ACIPAYAM H., KAYHAN FT.

Department of Otorhinolaryngology ,Bakırkoy Dr. SadiKonuk Training and Research Hospital, Istanbul,
Turkey

ABSTRACT

Cluster-type headaches often seen in men, which might be a different intensity, around the eyes and in the temporal region, a type of primary headache that may continue approximately between 15 and 180 minutes. In the literature, a lot of reasons of cluster-type headache had been defined . Many systemic diseases may carry this symptom . Besides, belong the interest field of ear, nose and throat physician, it can be seen in the paranasal sinus pathology. In the literature, Headache by the foreign bodies of maxillary sinus is considered extremely rare.

In this article, in the light of the literature, we present a patient refer to our clinic with symptoms of cluster headache, at paranasal sinus CT scanning, in the maxillary sinus fungus ball was thought, that's why caldwell-luc operation was performed and we extracted 11 pieces of glass from maxillary sinus.

Case report

51-year-old male patient, refer to us because of a complaint of headache in the last 10 years at the left eye area and face half, each attack continue about 3 hours and decreasing with use of analgesic use. Patient also have complaints of watering eyes and nasal congestion in the same side. It was learned that about 10 years ago in-vehicle traffic accident and after an accident due to a variety of skin, subcutaneous incision, our patient had an external intervention in the emergency room. There was no known history of a systemic disease and surgical operations. The patient's ear, nose and throat examination made and it was normal.

The patient was consulted to noroloji clinic and it was confirmed that patient's headache had the same criteria of diagnosis of cluster headache. central pathology hadn't been intended and sinusitis as a preliminary diagnosis had thought. At patient's paranasal sinus (PNS) computed tomography (CT) scanning, at left maxillary sinus, fully-expanded retention cyst and multiple focus millimetre radio-opaque foreign bodies had seen.

Endoscopic Sinus Surgery Caldwell-Luc operation and its risks were explained to the patient, we received the necessary consent from the patient. Under general anesthesia, from the left canine with the help of trocar, we entered maxillary sinus and window had opened and expanded with help of bone puch kerrison.

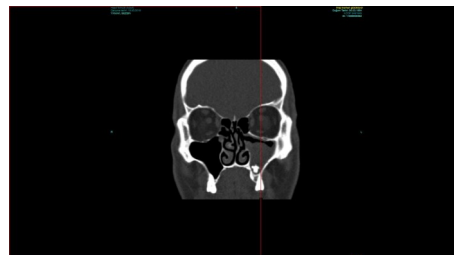


Fig 1 CT paranasal sinuses coronal cut showing radio dense foreign body inside maxillary sinuses with evidence of mucosal edema

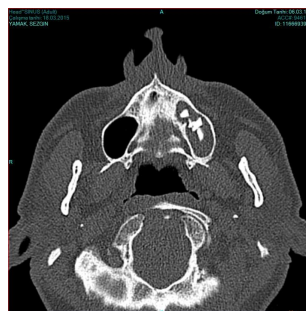


Fig 2 CT paranasal sinuses axial cut showing radio dense foreign body within maxillary sinus



Fig 3 Showing glass pieces removed from the maxillary sinus

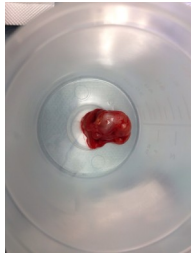

Fig 4 showing the removed mucous retention cyst from the maxillary sinus

With the help of zero degree endoscope and by forceps the retention cyst and glass foreign bodies were removed from the sinus. After bleeding control, drain was placed and without any complication we end the operation. After operation, the complaints of headaches and other ones regressed and patient had taken under rhinology clinic follow-up. We didn't see any postoperative complication along patient's six-month follow-up.

Discussion

After tension and migraine type headaches, Cluster-type headaches, is considered the most common primary headache. Like other types, cluster type headaches can be seen at any group of age. More often appears between the ages of 20 and 40. Unlike other headaches, cluster type headaches are seen more often in men. Cluster headache diagnosis is defined with headache diagnostic criteria that set in the international headache society in 2004.

There are five criteria for diagnosis. These criteria; A- B and D into account exactly matches with at least 5 of the features, B-15-180 minutes if untreated, severe or very severe unilateral orbital, supraorbital and/or temporal pain, C-at least one of the following headache must be accompanied by;

1-ipsilateral conjunctival redness, watering eyes, redness and/or

2-ipsilateral nasal congestion and/or discharge

3- ipsilateral eye edema,

4- ipsilateral forehead and facial sweating

5- ipsilateral miosis and/or ptosis,

6-restlessness and agitation.

D-the frequency of acting can change from 1 up to 8 in one day, E-these findings should not be connected to another systemic or neurological disease.

In our case for nearly a decade, each attack lasted for about 3 hours in addition to the ipsilateral nasal congestion and eye tearing in the absence of the antral or neurological disease, fit the criteria of cluster-type headaches.

The foreign bodies of maxillary sinus can cause cluster-type headaches rarely (3).

The base of the maxillary sinus is covered by thin bone, that why after dental procedures and post traumatic easier to damage, and foreign object leads to more easily reach the maxillary sinus (2). In our case the complaints were advanced post-traumatically and the objects reached the maxillary sinus after trauma.

Conclusion:

Cluster headache is diagnosed more by noroloji physicians. Patients that have pathologies of paranasal sinuses may suffer from cluster-type headache. Clinical suspicion is quite important in detecting rare pathologies. It should be kept in mind that the maxillary sinus foreign bodies may be etiology of cluster-type headaches.

References:

- 1- Top H, Aygit C, Sarikaya A, Karaman D, Firat MF. Evaluation of maxillary sinus after treatment of midfacial fractures. *J Oral Maxillofac Surg* 2004;62:1229-36.
- 2- Hasegawa J, Watanabe K, Kunitomo M, Ymauchi Y, Kurosaki S, Higa I, Aoki H, Yagi T. Foreign body in the maxillary sinus-possible plastic tube:a case report. *Auris Nasus Larynx* 2003;30:299-301.
- 3- Scorticati MC, Raina G, Federico M. Cluster-like headache associated to a foreign body in the maxillary sinus. *Neurology* 2002;59:643-4.

4- Dodick DW, Rozen TD, Goadsby PJ, Silberstein SD. Cluster headache. *Cephalgia*.2000;20:787-803.

5- Headache Classification Committee of the International Headache Society 2003. The International Classification of Headache Disorders. *Cephalgia*.Vol.24,Supp.1,2004.

