



Antrochoanal polyp in anterior nasal cavity

Rana Alramyan^{1,2}, Abdullah Alkarni^{1,2}, Mohammed Alkraidees^{1,2},
Buthaina Yahya^{1,2}, Faisal bin Talib^{1,2}, Yazeed Alghonaim^{1,3}

¹King Saud Bin Abdulaziz for Health Sciences, Saudi Arabia

²King Abdullah International Medical Research Center, Saudi Arabia

³King Abdulaziz Medical City, National Guard Health Affairs, Saudi Arabia

Abstract

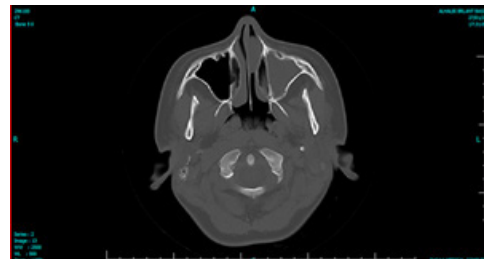
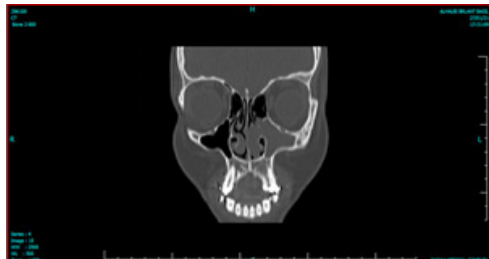Purpose: To report a case of a 15-year-old female with antrochoanal polyp, that has unusual presentation according to the location of the polyp.

Setting: The patient attained to an outpatient clinic in Riyadh, Saudi Arabia.

Design: Case report.

Case: A young patient presented complaining of nasal obstruction, headache and postnasal drip for two weeks period. CT imaging demonstrate a total opacified left maxillary sinus, maxillary ostium with widening of the left maxillary ostium by polypoid mucosal thickening suggesting an antrochoanal polyp obstructing the left anterior nasal cavity. The antrochoanal polyp measured 2.5 x 2 cm in the left maxillary sinus and extended to the anterior part of the nasal cavity. Functional Endoscopic Sinus Surgery (FESS) is the appropriate treatment of antrochoanal polyp in contrast to more severe invasive open procedures that are reserved for cases that cannot be managed endoscopically.

Conclusions and Importance: As the Antrochoanal polyp usually presents from the antrum and grows through its ostium into the middle meatus, after that it extends into the posterior choana. We present a case with unusual location as the polyp originated from the maxillary sinus through the ostium and went anteriorly to the anterior part of the nasal cavity against gravity without any obvious reason.



Biography

An interested and enthusiastic medical intern, who enjoys working in otolaryngology department and hopes to be future ENT surgeon.

Recent Publication

Canji K, Mitrovic S. Giant antrochoanal polyp: Case report and literature review. Medical review. 2014;67(11-12):410–2.

Cetinkaya EA. Giant antrochoanal polyp in an elderly patient: case report [Internet]. Acta otorhinolaryngologica Italica : organo ufficiale della Societa italiana di otorinolaringologia e chirurgia cervico-facciale. Pacini Editore SpA; 2008 Available from: <https://www.ncbi.nlm.nih.gov/pmc/articles/PMC2644989/>

Frosini P, Picarella G, De Campora E. Antrochoanal polyp: analysis of 200 cases [Internet]. Acta otorhinolaryngologica Italica : organo ufficiale della Societa italiana di otorinolaringologia e chirurgia cervico-facciale. Pacini Editore SpA; . Available from: <https://www.ncbi.nlm.nih.gov/pmc/articles/PMC2689564/> .

11th International Conference on Otorhinolaryngology and ENT Surgery
Webinar | February 09, 2022

Citation: Rana Alramyan et al., *Antrochoanal polyp in anterior nasal cavity*, Otorhinolaryngology 2022, 11th International Conference on Otorhinolaryngology and ENT Surgery | February 09, 2022