

# Anaesthesia and post-operative analgesia for a patient with traumatic mid arm amputation with a continuous infraclavicular nerve block: A case report.

Welikala ND<sup>1\*</sup> and Kulasiri RDS<sup>2</sup>

<sup>1</sup>Department of Anesthesiology, Post-graduate Institute of Medicine, University of Colombo, Sri Lanka

<sup>2</sup>Department of Anesthesiology, National Hospital of Sri Lanka, Sri Lanka

## Abstract

**Post operative care following traumatic upper limb amputation includes provision of adequate analgesia, infection control and rehabilitation. Continuous Peripheral Nerve Block (CPNB) has been reported to provide sufficient intraoperative anaesthesia and postoperative analgesia. The use of ultrasound guidance has improved the success rate, safety and the ease of performance of peripheral nerve blocks. We present a 35-year-old man who suffered from a stable odontoid fracture and a traumatic amputation of the left arm where ultrasound-guided infraclavicular block was used to provide analgesia and anaesthesia for wound toilet completely avoiding general anaesthesia. Continuous bupivacaine infusion through a catheter provided high quality postoperative analgesia.**

**Keywords:** Neuropathic pain, Trauma, Cervical spine, Anaesthesia, Post-operative analgesia.

**Abbreviations:** CPNB: Continuous Peripheral Nerve Block; VAS: Visual Analogue Scale.

*Accepted on November 29, 2018*

## Introduction

Post amputation pain involves both nociceptive and neuropathic pain. Inadequate control of pain may lead to increased stress response, impact on patient's psychology, poor functional recovery and increase the risk of chronic stump pain or phantom limb pain [1-3]. Use of regional anaesthesia either with central neuraxial blocks or with perineural blockage is the gold standard for management of post-amputation acute stump pain. It effectively controls pain, alleviates distress and decrease opioid requirement [3]. The introduction of ultrasound guidance has rendered neural block technique more easy, reliable and safe [2]. Continuous peripheral nerve blocks can provide prolonged, good quality analgesia, with minimal monitoring requirements and systemic side effects [3]. Use of prolonged perineural blockage significantly reduced the incidence of phantom limb pain [3].

## Case Presentation

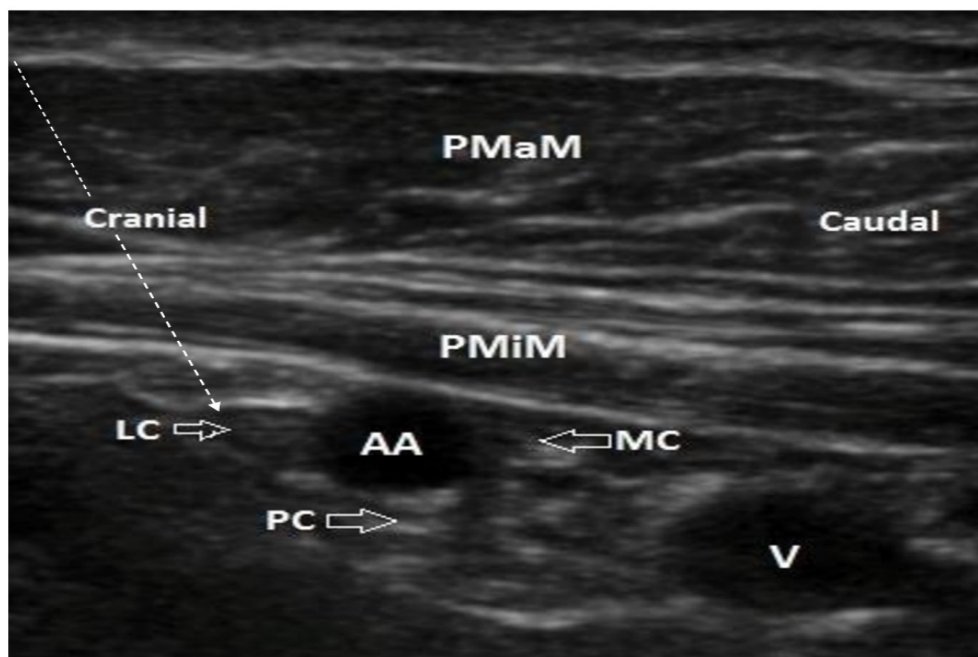
A 35-year-old male suffered a traumatic amputation of left upper limb at mid arm level following a fall from 30 feet height. He was initially managed according to Adult Trauma Life Support guidelines. On admission, the patient was drowsy but maintained the airway. Cervical neck was immobilized using a Philadelphia collar. Bilateral chest expansion and air entry was equal. He was tachycardic, but blood pressure was stable. His Glasgow Coma Scale was 13/15. There were no other significant external wounds. Focused Assessment Sonography in Trauma was negative. Non-contrast computer tomography of the cervical spine revealed a type 3 undisplaced odontoid fracture which was managed non-operatively with external immobilization using the Philadelphia collar.

Patient was tachycardic, hypertensive and complained of

severe acute pain inspite of intravenous morphine infusion, oral paracetamol, sublingual ketamine and oral gabapentin. He was too drowsy to assess visual analogue scale (VAS) on presentation. Emergency replantation was abandoned due to severely crushed and heavily contaminated wound. Urgent wound debridement was planned. Response to intravenous opioids, sublingual ketamine and oral paracetamol was not satisfactory. We decided to continue under a regional block to avoid airway manipulation during general anaesthesia. Ultrasound guided infraclavicular block was performed to achieve anaesthesia for the wound debridement and an 20 gauge catheter was inserted to provide post operative analgesia using continuous local anesthetic infusion.

High-frequency 5-10 MHz linear transducer was used for the ultrasound-guided infraclavicular brachial plexus block. Axillary artery was visualized. Three cords of the brachial plexus were visualized posterior to the pectoralis minor muscle (Figure 1). 18 Gauge Tuohy needle was used in-plane with the ultrasound probe. The tip of the needle was kept under visualization throughout the procedure. A total dose of 0.25% bupivacaine 15 ml was administered around the three cords. 20 gauge epidural catheter was introduced anterior to the posterior cord through the epidural needle with ultrasound visualization to provide continuous infusion of 0.1% bupivacaine 5 ml/hour.

Post operatively his VAS score at rest was 1-2 and on motion was 3. Oral paracetamol and gabapentin were continued as regular doses for five days. Sublingual ketamine was used 6 hourly for 48 hours. His pain was effectively controlled and did not require opioid analgesics afterwards. He received infraclavicular infusion up until 6 days after surgery. His pain was controlled with oral analgesics. Infraclavicular 0.1% bupivacaine 5 ml boluses were given for break through pain and wound dressings



**Figure 1.** Infraclavicular brachial plexus.

**Abbreviations:** PMaM: Pectoralis Major Muscle; PMiM: Pectoralis Minor Muscle; AA: Axillary Artery; V: Axillary Vein; LC: Lateral Cord; MC: Medial Cord; PC: Posterior Cord; Arrow: Needle pathway

until 10 days. Catheter was removed once patients' pain was controlled without infraclavicular analgesia for 48 hours.

## Discussion

This case reports the use of continuous peripheral nerve block for anaesthesia and post operative analgesia following a traumatic mid arm amputation. Brachial plexus block provided a safe alternative to general anaesthesia where the airway manipulation can potentially aggravate the cervical spine injury. The brachial plexus block can be performed with the use of ultrasound or the peripheral nerve stimulator. Anatomical landmark technique with blind insertion of the needle has increased risk of complications such as failure, pneumothorax and vascular puncture. Adequate knowledge of the anatomy and sonoanatomy is essential when performing peripheral nerve blocks. Selection of an appropriate level of access to the brachial plexus is essential to accomplish a successful block [4]. Supraclavicular, infraclavicular and axillary plexus blocks can provide enough analgesia to cover the mid to lower arm region [5].

The supraclavicular approach was avoided in this patient due to the difficulty in placing CPNB catheter in the supraclavicular fossa with the limitation of neck movements and the likelihood of catheter displacement by the cervical collar. Axillary block was difficult to perform as severe pain limited the positioning. Infraclavicular block can be used for surgical procedures below mid humerus level. It is easy to perform, and it anaesthetizes the axillary, musculocutaneous, median, radial and ulnar nerves. The block has only a minimal risk of pneumothorax, phrenic nerve or stellate ganglion blockage [6].

Ultrasound-guided nerve block offers direct visualization of the anatomical landmarks and the needle trajectory. It reduces the risk of vascular puncture, nerve damage, improve sensory and motor block, minimize discomfort to the patient during insertion

by avoiding multiple puncture and reduce complications associated with nerve blocks. Catheter tip placement and drug distribution can also be directly visualized. Ideal positioning may reduce the total dose of drug given and decrease the risk of local anesthetic toxicity [4]. The sympatholytic effects of CPNB may improve the perfusion of the amputated limb [4]. CPNB provide good post-operative analgesia, analgesia for multiple wound dressings, has minimal hemodynamic side effects, reduced incidence of post-operative nausea, sedation, vomiting and thromboembolism, facilitate early mobility, and assistance in physiotherapy [7,8]. Acute pain of the stump should be controlled well to avoid phantom limb and chronic stump pain [3]. Long-term indwelling catheters potentially have a risk of developing local and deep tissue infection. But it is found that the incidence of serious infection is low and CPNB can be used safely [9,10]. Subcutaneous tunneling of the catheter [10] and use of a chlorhexidine-impregnated dressing [11] has been suggested to decrease the incidence of infectious complications.

## Conclusion

We used a continuous infraclavicular brachial plexus block to effectively control acute stump pain in this patient. Insertion of an indwelling catheter under ultrasound guidance improves accuracy and safety of the procedure. We managed to reduce the doses of sublingual ketamine and completely stopped opioids.

## References

1. Plunkett AR, Brown DS, Rogers JM, et al. Supraclavicular continuous peripheral nerve block in a wounded soldier: when ultrasound is the only option. *Brit J Anaesth.* 2006;97(5):715-7.
2. Sandhu NS, Capan LM. Ultrasound-guided infraclavicular brachial plexus block. *Brit J Anaesth.* 2002;89(2): 254-9.
3. Neil MJ. Pain after amputation. *BJA Edu.* 2015;16(3):107-12.

4. Chiu CH, Kuo YW, Hsu HT, et al. Continuous infraclavicular block for forearm amputation after being bitten by a saltwater crocodile (*Crocodylus porosus*): A case report. *Kaohsiung J Med Sci.* 2009;25(8):455-9.
5. Marhofer P, Greher M, Kapral S. Ultrasound guidance in regional anesthesia. *Brit J Anaesth.* 2004;94(1):7-17.
6. Bigeleisen P, Wilson M. A comparison of two techniques for ultrasound guided infraclavicular block. *Brit J Anaesth.* 2006;96(4):502-7.
7. Ahmad H, Yadagiri M, Macrosson D, et al. Above elbow amputation under brachial plexus block at supraclavicular and interscalene levels. *Anesthesiol and Pain Medi.* 2015;5:6.
8. Anghelescu DL, Harris BL, Faughnan LG, et al. Risk of catheter-associated infection in young hematology/oncology patients receiving long-term peripheral nerve blocks. *Pediatr Anesth.* 2012;22(11):1110-6.
9. Cuvillon P, Ripart J, Lalourcey L, et al. The continuous femoral nerve block catheter for postoperative analgesia: bacterial colonization, infectious rate and adverse effects. *Anesthes Analges.* 2001;93(4):1045-9.
10. Pacenta HL, Kaddoum RN, Pereiras LA, et al. Continuous tunneled femoral nerve block for palliative care of a patient with metastatic osteosarcoma. *Anaesth Intens Care.* 2010;38(3):563.
11. Kerwat K, Eberhart L, Kerwat M, et al. Chlorhexidine gluconate dressings reduce bacterial colonization rates in epidural and peripheral regional catheters. *Biomed Res Int.* 2015.

**\*Correspondence to:**

Welikala ND  
Registrar, Department of Anesthesiology  
Post-graduate Institute of Medicine  
University of Colombo  
Sri Lanka  
Tel: +94-775940272  
E-mail: nadeeshya@yahoo.com