



## An Infant with Cut Throat A Case Report

\*Chandrakant \*Vishwambhar singh \*Choudhary \*Tiwari

\*Rajendra Institute of Medical Sciences

### Abstract:

A 10 month old infant with severe injuries in zone I of neck reported to emergency was managed accordingly and survived. It was a rare incidence of homicidal assault by a father on child with a piece of glass. Father is a regular user of ganja(cannabis). In post-operative period there were complications which were taken care of. Proper and timely intervention is what that is needed in such injuries.

Keywords: cut throat, anterior neck injury, penetrating neck injury, zone I neck injury, tracheostomy.

Introduction: In today's developed and modern world with increased rate of literacy and improvement in quality of human life, the incidences of cut throat has decreased significantly though other modes of injury to neck are on rise especially due to trauma. In this scenario the assault by a father on his 10 month old male infant is rare and after sustaining such a barbarous assault the child survived, is also rare.

### Case report:

A 10 month old male infant was brought to our emergency at RIMS Ranchi (Rajendra Institute of Medical Sciences) with alleged history of cut throat injury inflicted by his father. The weight of child was 8 kg, belonged to low socioeconomic status; his father is a regular user of ganja (cannabis). Patient was referred to our hospital after a superficial bandage from Sadar Hospital of Hazaribagh district. On removal of bandage there was an injury on anterior aspect of neck (zone I).

The extent of the injury was from right sternocleidomastoid to left sternocleidomastoid. It was superficial in initial 3 cm on right side of neck. But on moving left from midline it was a deep incised looking wound cutting the trachea on left lateral side in half of its circumference. This injury on left side was deep and reached the left sternocleidomastoid. It was 1.5 cm deep. There were three more superficial cuts on neck each of around 1 to 2 cm. The injuries appeared to be inflicted by some irregular cutting object which on further inquiry revealed that it was made by a piece of glass.

The patient was managed under general anaesthesia without passing endotracheal tube. A Fuller's type tracheostomy tube was passed in the injured left lateral portion of the trachea itself as there was no further space for creation of new midline tracheostoma[1]. After securing the airway further exploration of injury was started which showed presence of thyroid gland of child just one cartilage above the injured trachea. The Thyroid gland was totally safe. On further exploration of inner turned margin of wound there was a sudden gush of blood which was identified as from external jugular vein, secured haemostasis achieved. The main wound was closed in two layers and other superficial wounds were also repaired.

In the beginning of the procedure the saturation was 85% which was 100% 15 minutes post operatively. A nasogastric tube was passed, though there was no injury to oesophagus or pharynx. One unit of whole blood was transfused. Proper care of tracheostomy tube and aseptic dressing was done regularly. Breast feeding was started on post op day seven.

Patient developed cough which was productive on post-operative day 5 and associated with fever of moderate grade (101 F). Chest X ray showed patchy consolidation of upper mid zone of right lung, which was treated accordingly. The repeat chest X ray on post-operative day 12 showed patchy consolidation on left upper mid zone also, which was managed with antibiotics. Patient also had an episode of antibiotic induced diarrhoea, managed symptomatically.

CT scan of trachea was done to rule out any stenosis[2]. Graded extubation of child started, which was uneventful. Now the child is having a normal cry, is otherwise healthy. Bronchoscopy was done to rule out any stenosis. Patient is on follow up at every 3 weeks.

**DISCUSSION:** Most of anterior neck injuries as cut throat emergency are fatal, if major blood vessels are involved, due to haemorrhage and hypovolemic shock or if there is aspiration of blood or severe airways obstruction from oedema or fractured laryngeal structures [3-7]. If cervical spine injury is suspected neck stabilization and immobilization is required as these injuries are often associated with other injuries[ 8]. In our case there was no associated injury to the infant.

Evaluation of airways should be the first priority for all the patients and airways should be maintained by cricothyroidotomy or urgent tracheotomy[9]. The infant in our case already had a laterally cut trachea in which Fuller's tracheostomy tube was inserted and airway secured.[1]

Ezeanolue(2001) carried out tracheostomy in all his patients with cut throat injury patients[10]. Okoye favours tracheotomy in all patients. Ladapo also did tracheotomy in all his patients. In 15 out of 26 cases tracheostomy was carried out by Bhattacharyagee et al.[11].

In the modern era with availability of fiberoptic intubation and airway management the need of tracheostomy has decreased considerably, as it has its own complications. In our view each and every case should be assessed based on the extent of injury.

The hypo pharynx, larynx and trachea from cut throat injury require timely and meticulous surgical layer by layer repair to restore the continuity of the aero digestive tract without complications. The laryngeal, hypo pharyngeal and tracheal mucosal lacerations should be ideally repaired within 24 hours [12,13,14], as it may have effect on both airway stenosis and voice. Significant glottic and superaglottic lacerations, displaced and fractured cartilages need immediate surgical care [12,13,14]. Laryngotracheal stenosis has been noted as long term morbidity in some of the studies [10].

In severe penetrating injuries from gunshot, the endoscopy and CT scan will differentiate between the patients that need only observation (small lacerations, shallow laceration, non-displaced fracture) and those who require thyrotomy or open reduction with mucosal approximation [2,16]. A soft laryngeal stent may be needed for badly macerated mucosa.

Pharyngo –cutaneous fistula must be prevented as much as possible while carrying out pharyngo-hypopharyngeal repair. This requires meticulous approximation of the tissues, use of NG tube and nil oral feeding for a minimum of 7 -9days. Should there be a pharyngo-cutaneous fistula, NG tube feeding must continue for as long as possible until the fistula closes as a conservative approach to management. If the fistula persists for more than 6weeks, one must exclude the possibility of presence of a foreign body, wrong surgical technique, malnutrition or a concomitant underlying concealed malignancy especially in the elderly. Such extreme cases may need flap closure using local, regional or distant flaps after excision of the fistula.[17].

Continuous psychiatric monitoring is essential in all cases of attempted suicide and homicide otherwise a repeat incidence may reoccur which may be fatal. Ladapo reported a case that was ready to commit suicide again if given another opportunity [3]. Bhattacharjee et al mentioned family troubles, psychiatric illness and poverty as the triggering factors in suicidal attempts [11]. According to Harrison et al, cannabis is known (often at small dose levels) however to impair memory function, distort perception, impede judgement and reduce motor skills [18]. Such effects are most often likely to manifest their negative consequences upon the young. Shedler et al in a longitudinal survey of adolescents reported that adolescents who used illicit drugs (cannabis) frequently were maladjusted, showing distinct personality syndrome marked by interpersonal alienation, poor impulse control, and manifest emotional distress [19]. Spunt et al reported that marijuana (cannabis) was the most common illicit drug (86%) used by a sample of 268 murderers incarcerated in New York state correctional facilities for homicides that occurred in 1984[20]. About one-third of the prisoners (33%) had used marijuana in the 24-hour period before the homicide and that almost three-quarters (70%) of those respondents were experiencing some type of effect from the drug when the homicide occurred. Eighteen respondents (7% of the total sample) said the homicide was related to their marijuana use [20]. In our case father of the child is a regular user of cannabis (ganja) from more than 5 years and in last 18 months the social behaviour has deteriorated a lot.

Complications of Anterior neck injuries could be classified as immediate, intermediate and delayed [1, 2, 3, 5, 6, 7, and 20]. Immediate complications include:

1. Respiratory obstruction from:

- A) Fractured hyoid bone, thyroid, cricoid or tracheal cartilages pushed posteriorly.
- b) Slit base of tongue falling over the laryngeal inlet.
- c) Oedema or haematoma in or around the larynx.
- d) Flooding of the air passages and patient drowning in his blood.

2. Air aspiration into the neck veins and embolization

3. Profuse haemorrhage and hypovolumic shock.

Intermediate complications include:

1. Respiratory obstruction due to surgical emphysema
2. Non-specific infections like cervical cellulitis, perichondritis anterior mediastinitis.
3. Tetanus and gas gangrene in contaminated wounds.
4. Aspiration pneumonitis due to loss of laryngeal afferents or motor control in the protective cough reflex or tracheo-oesophageal fistula.
5. Pharyngo-cutaneous or trachea-oesophageal fistula.
6. Chyle or lymph fistula.

Delayed complications include:

1. Aphonia, dysphonia or hoarseness
2. Stenosis of the aero digestive tract.
3. Aneurysmal formation or arterio-venous fistula.
- 4 Hypertrophic neck scars.
5. Psychological trauma

So it may be concluded that for all cut throat injuries there may be various aetiology, extent, and depth. With prompt meticulous layer by layer surgical repair within 24hours of the injury and stepwise post-operative management with NG tube feeding is advocated to avoid long term complications of Pharyngo- cutaneous fistula, aero digestive tract stenosis which requires series of long term reconstructive measures to restore normal function of the aero digestive tract and closure of the fistula. The psychiatric monitoring of the accused in case of homicide or the patient himself in cases of suicide is a must. Use of illicit drugs must also be looked for.

## REFERENCES

1.Vivek Sasindran, Antony Joseph: management of penetrating zone II neck injuries. Indian Journal Of Otolaryngol Head Neck Surgery.(October-December) 2009;61:313-316.

2. AbhaySinha, Savitri Gupta: Computed Tomography in the evaluation of Laryngotracheal Stenosis.. Indian Journal Of Otolaryngol Head Neck Surgery. (april-june)2004;56:104-107.
3. Ladapo AA: Open injuries of anterior aspect of the neck. Ghana Med Journal 1979;4:182-6
4. Okoye BC, Oteri AJ. Cut throat injuries in PortHarcourt. Sahel Med Journ 2001;4:207-209.
5. Kendall JL, Anglin D, Demetriades D. Penetrating neck trauma. Emergency Medicine Clinics of North America 1998; 16:85-105.
6. Biffl WL, Moore EE, Rehse DH, Offner PJ, Franciose RJ, Burch JM. Selective management of penetrating neck trauma based on cervical level of injury. American Journal of Surgery 1997;174:678-82.
7. Demetriades D, Asensio JA, Velmahos G, Thal E. Complex problems in penetrating neck trauma. Surgical Clinics of North America 1996;76:661-83.
8. B. Vishwanatha, A, Sagayaraj, Shalini G Huddar, Prashanth Kumar, R.K. Dutta. Penetrating neck injuries: . Indian Journal Of Otolaryngol Head Neck Surgery. (july- September )59 ;221-224.
9. Bumpous JM, Whitt PD, Ganzel TM, McClane SD. Penetrating injuries of the visceral compartment of the neck. American Journal of Otolaryngology. 2000;21:190-194.
10. Ezeanolue BC. Management of the upper airway in severe cut throat injuries. African Journal of medicine and medical sciences 2001;30:233-5.
11. Bhattacharjee N, Arefin SM, Mazumder SM, Khan MK. Cut throat injury :a retrospective study of 26 cases. Bangladesh Med Res councl. Bull 1997;23:87-90.
12. Pradipta Kumar Parida, Ashok kumar Gupta: Management of Laryngotracheal stenosis-our experience :. Indian Journal Of Otolaryngol Head Neck Surgery. (October-december)2009;61:306-312.
13. Davies JR. The fiberoptic laryngoscope in the management of cut throat injuries. British journal of Anaesthesia 1978;50:511-514.
14. Leopold DA: Laryngeal trauma, Arch Otolaryngol 1983; 109:106-109.
15. Cherian TA, Rupa V, Raman R. External laryngeal trauma: analysis of 30 cases. JLO 1993;107:920-923.
16. Naaeder SB .The neck. In: Badoe EA, Archampong EQ and da Rocha-Afodu JT eds. Principles and Practice of surgery including Pathology in the Tropics, 3<sup>rd</sup> edition. Tema, Ghana: Ghana Publishing Corporation Publishers 2000;339.
17. S. Sett, D.K. Isser: Laryngotracheal stenosis and pharyngocutaneous fistula in cut throat injuries – how we managed them.. Indian Journal Of Otolaryngol Head Neck Surgery. (july – september)2000;52:315-318.
18. Harrison LD, Backenheimer M, Inciardi JA, Cannabis use in the United States: Implications for policy. In: Cohen P & Sas A (eds). Cannabisbeleid in Duitsland, Frankrijk en de Verenigde Staten. Amsterd Centrum voor Drugsonderzoek, Universiteit van Amsterdam 1996:198-205.
19. Shedler J, Block J. Adolescent drug use and psychological health: A longitudinal inquiry. American Psychologist 1990;45(5):612-630.
20. Spunt B, Goldstein P, Brownstein H, Fendrick M. The role of marijuana in homicide. International Journal of the Addictions 1994;29(2):195-213.

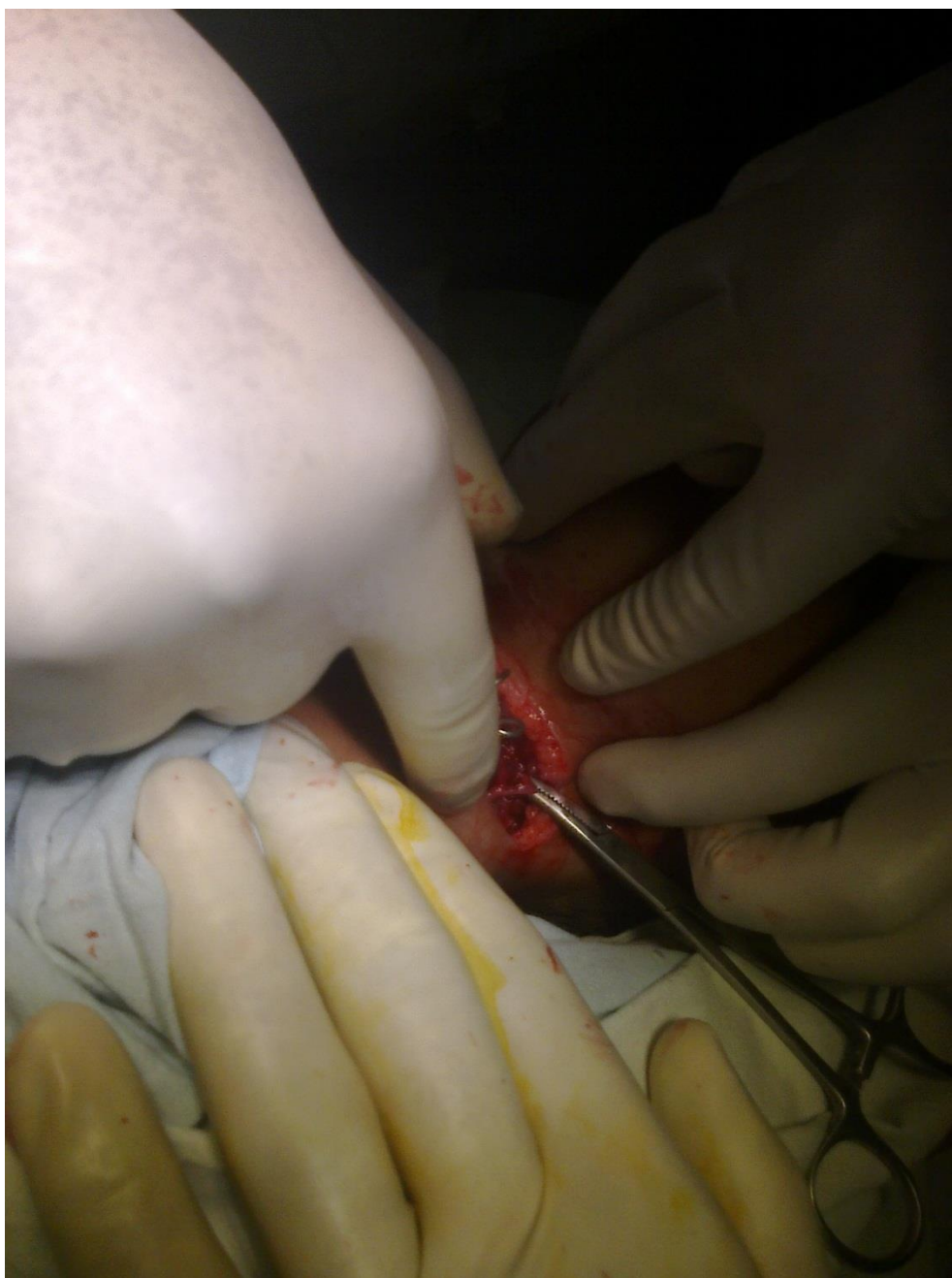


Figure 1: securing the airway and bleeding.

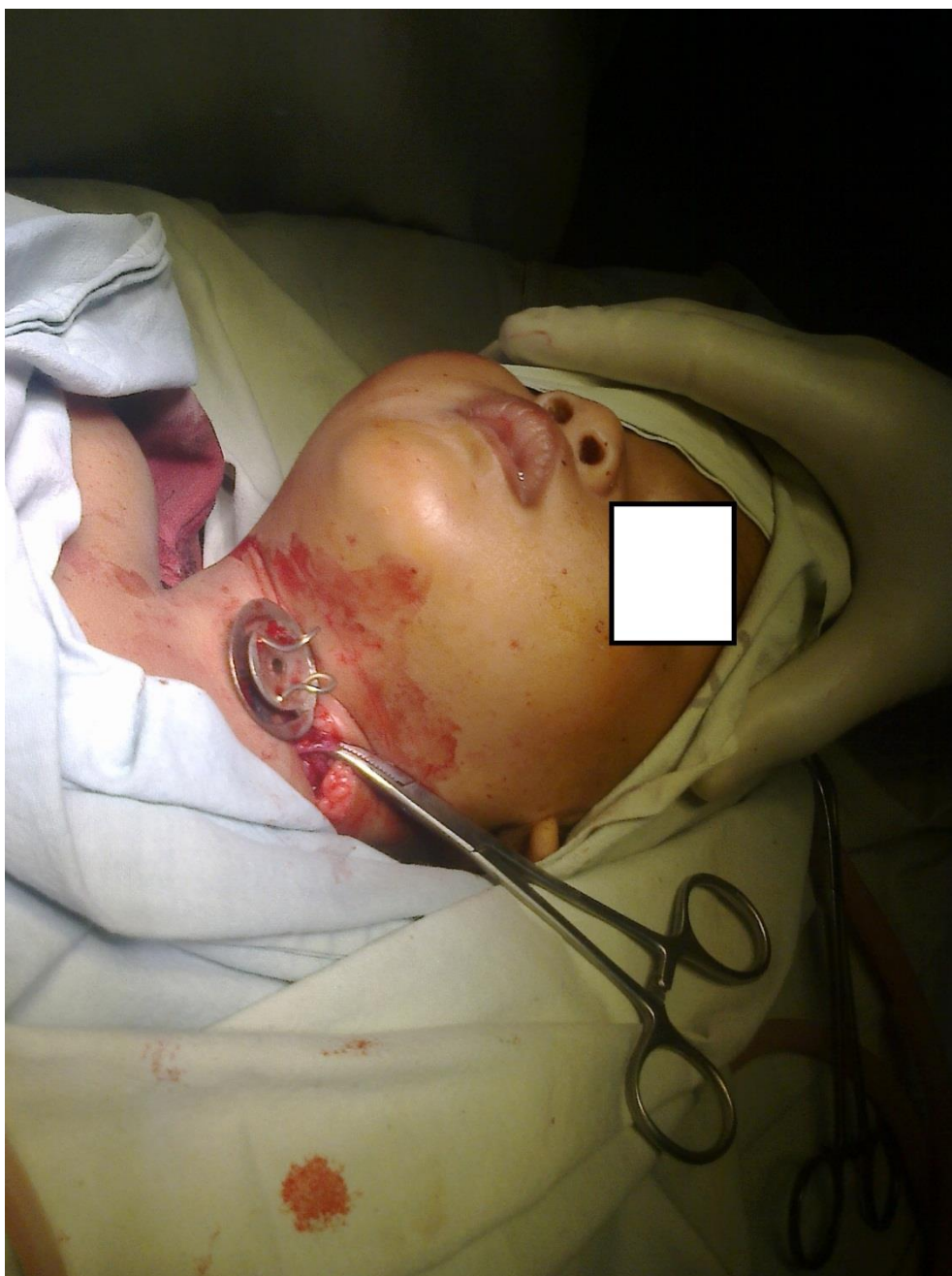

Figure 2 : airway and haemostasis secured.



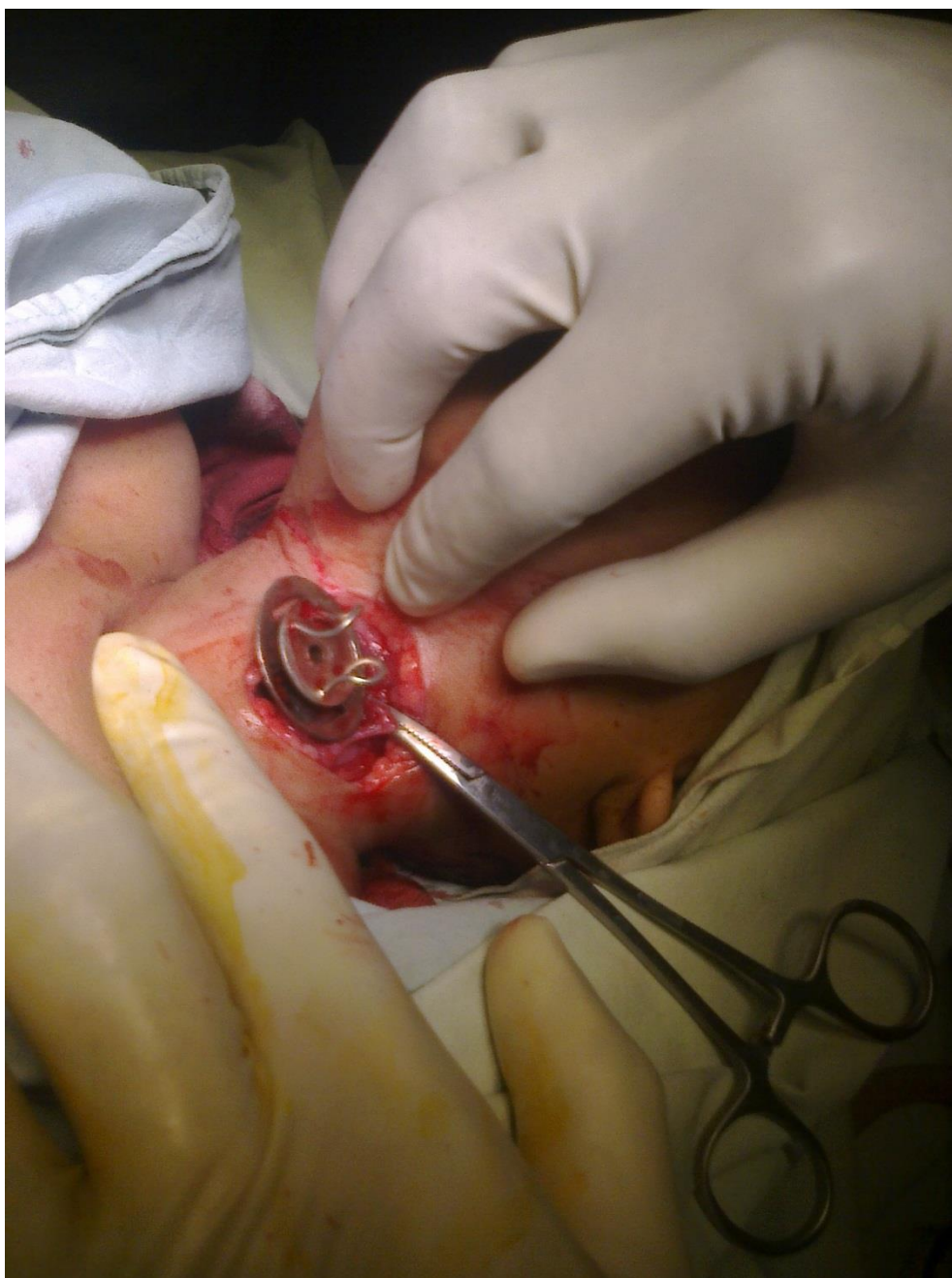


Figure 3 : airway and haemostasis secured



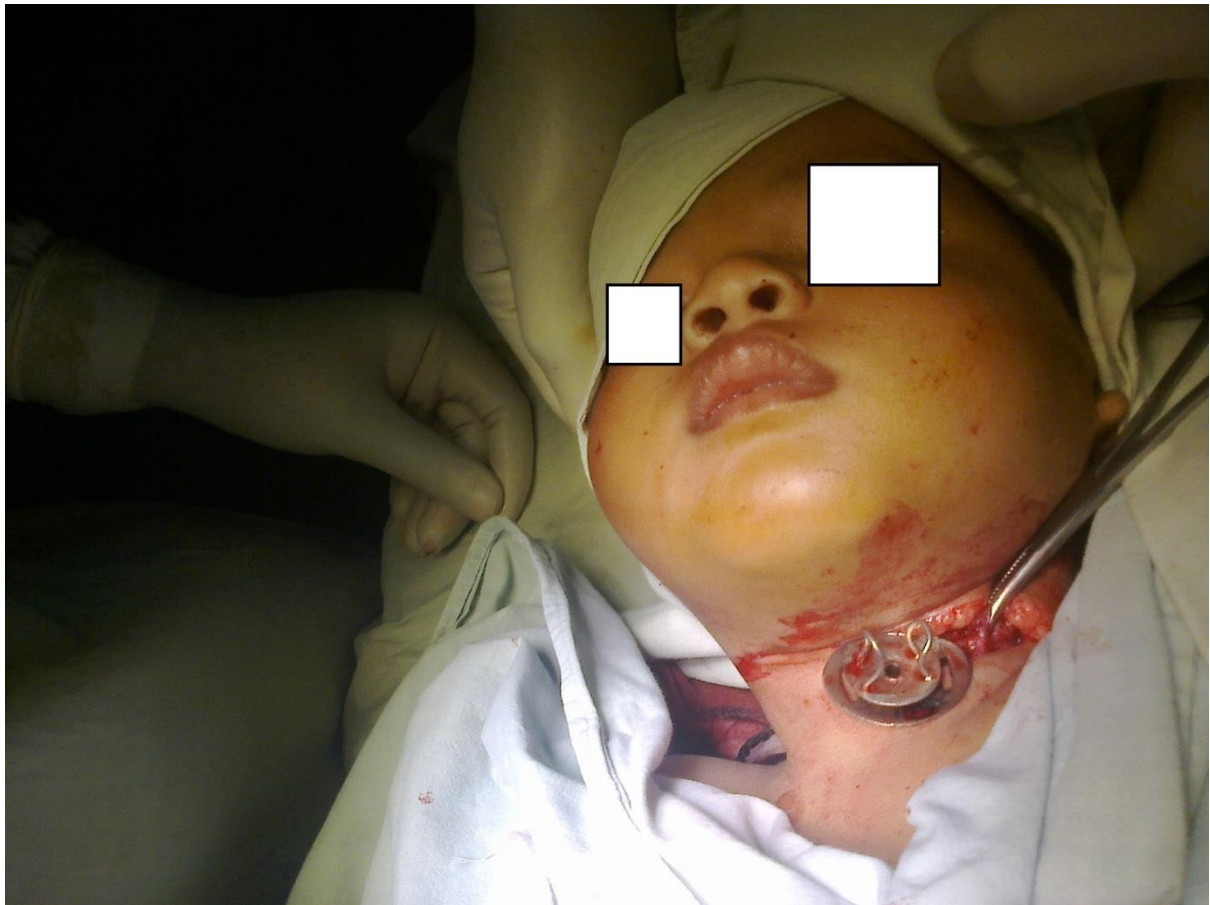

Figure 4 : airway and haemostasis secured

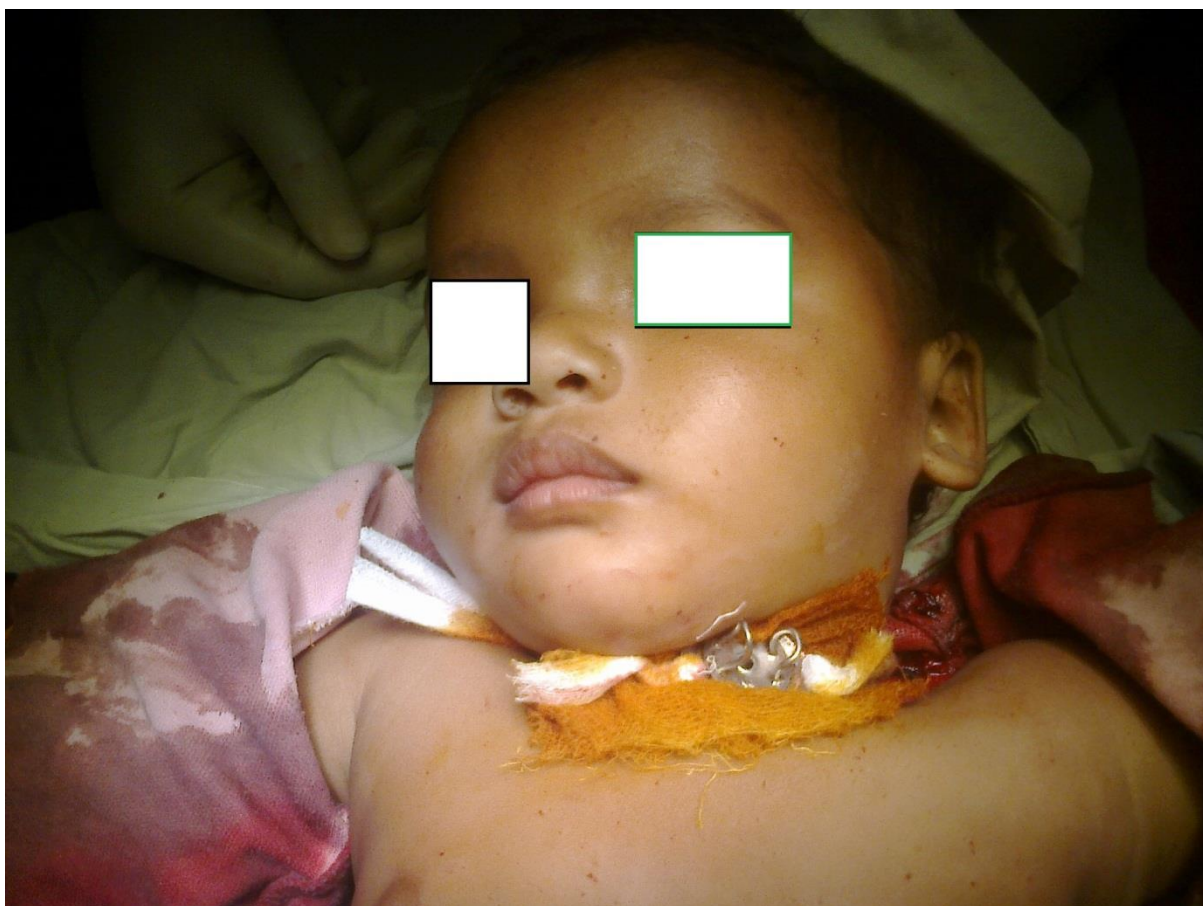

Figure 5: procedure completed.

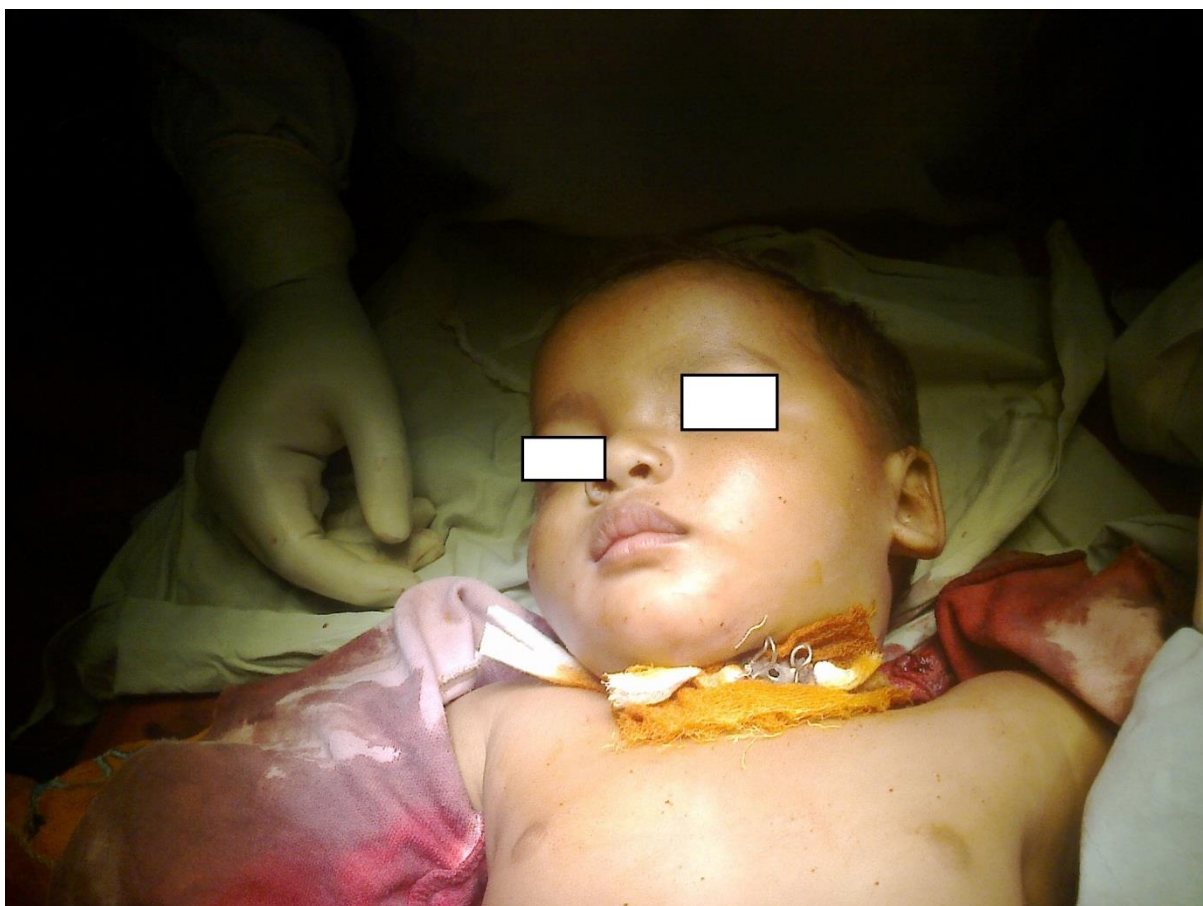

Figure 6: procedure completed.

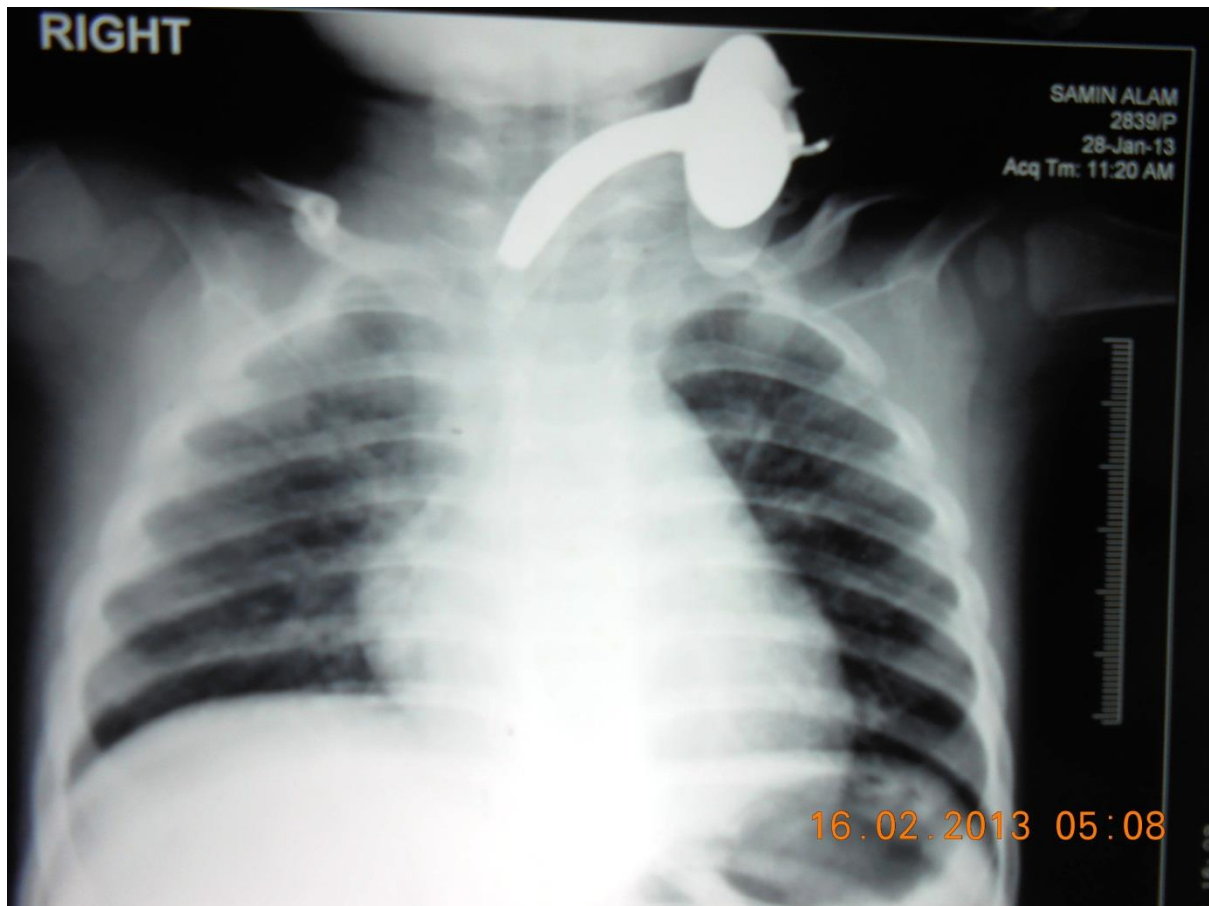


Figure 7: X RAY on post-operative day 5 showing patchy consolidation in upper mid zone of right lung.



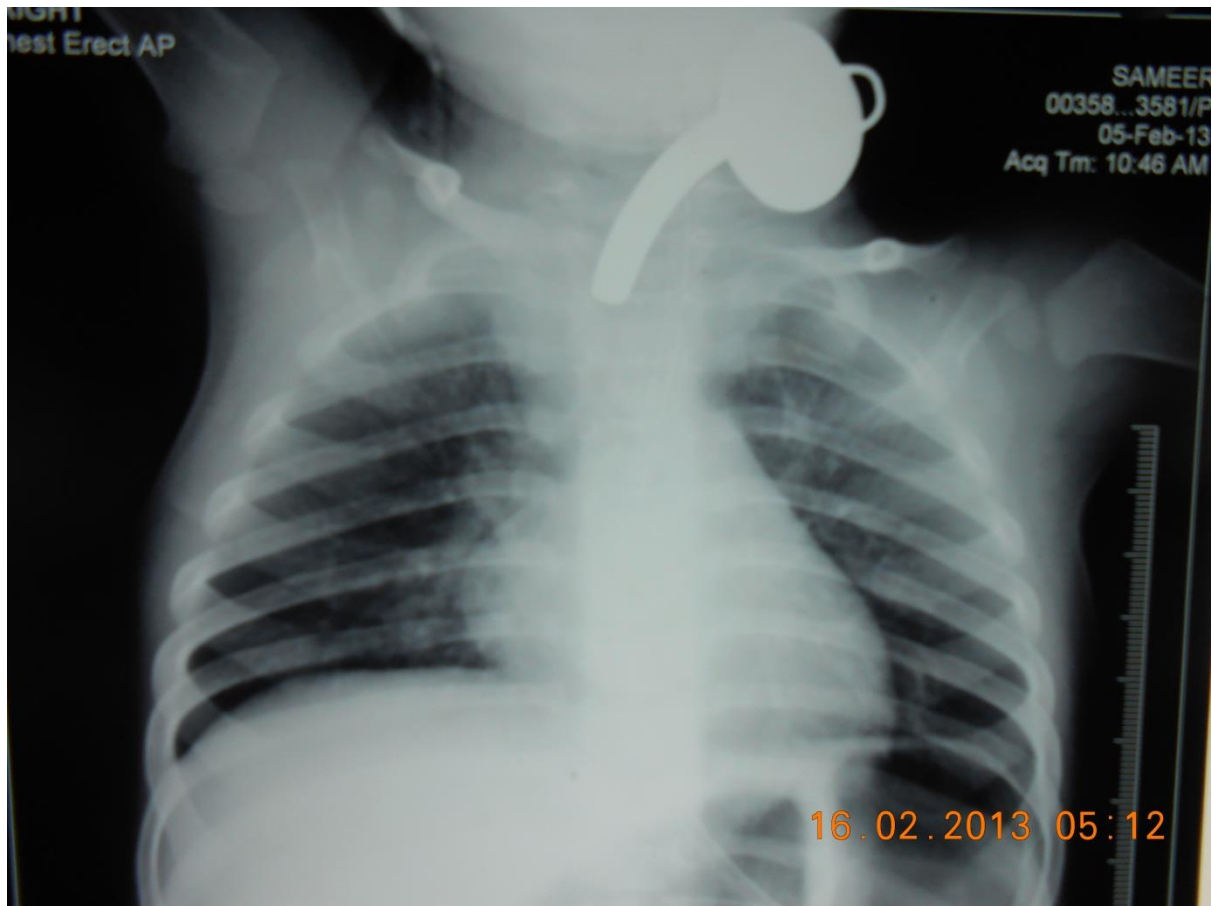

Figure 8: X RAY on post-operative day 12 showing patchy consolidation in upper mid zone of left lung also.

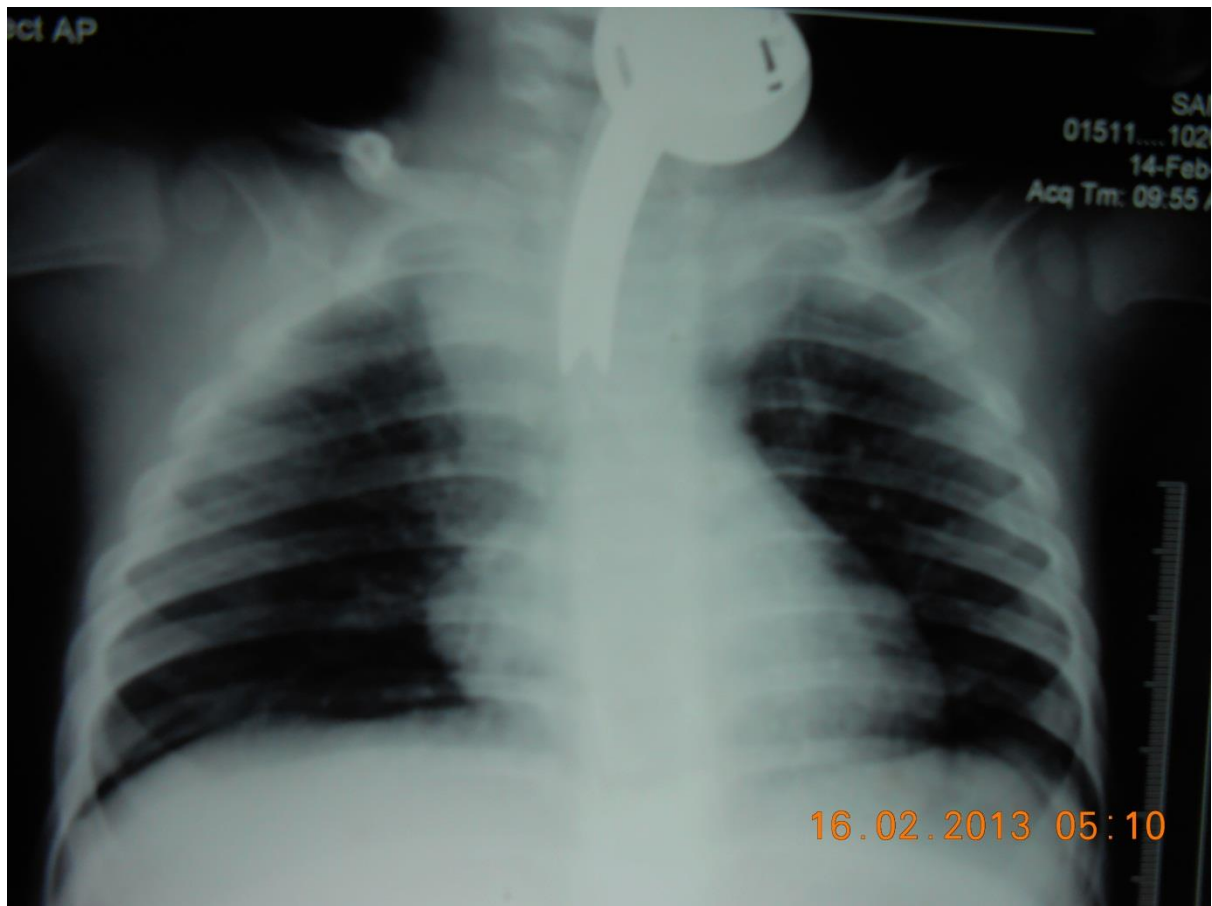

Figure 9: x ray showing normal lungs on post-operative day 20.



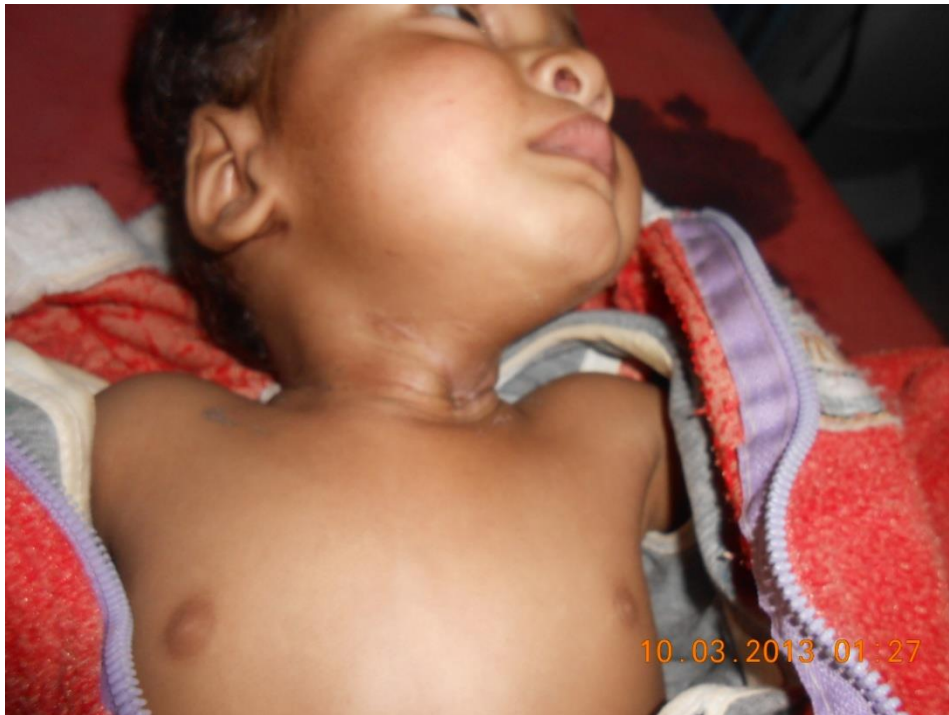

Figure 10.six weeks post operative.

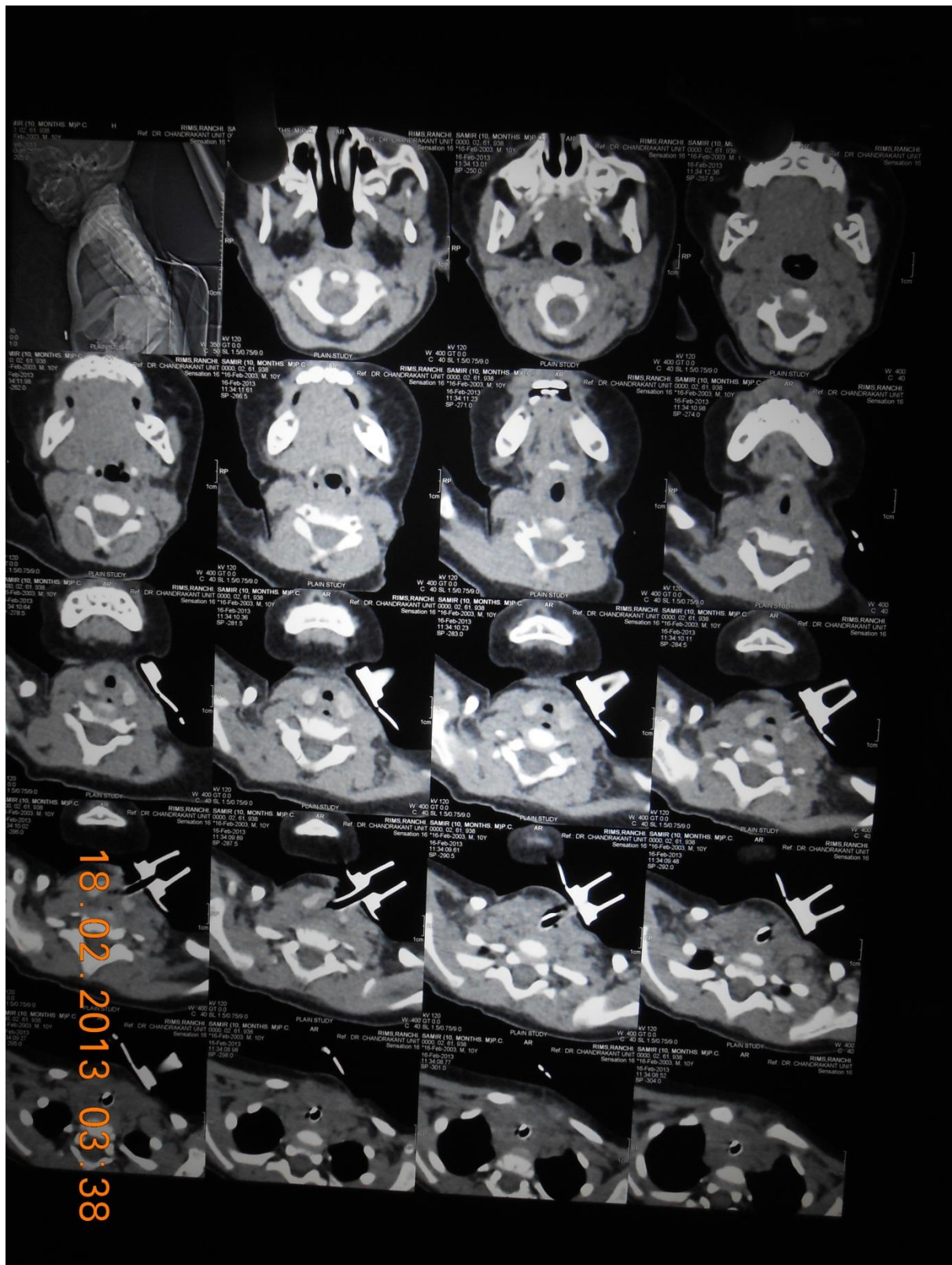


Figure 11: A normal CT scan after 6 weeks postoperative.

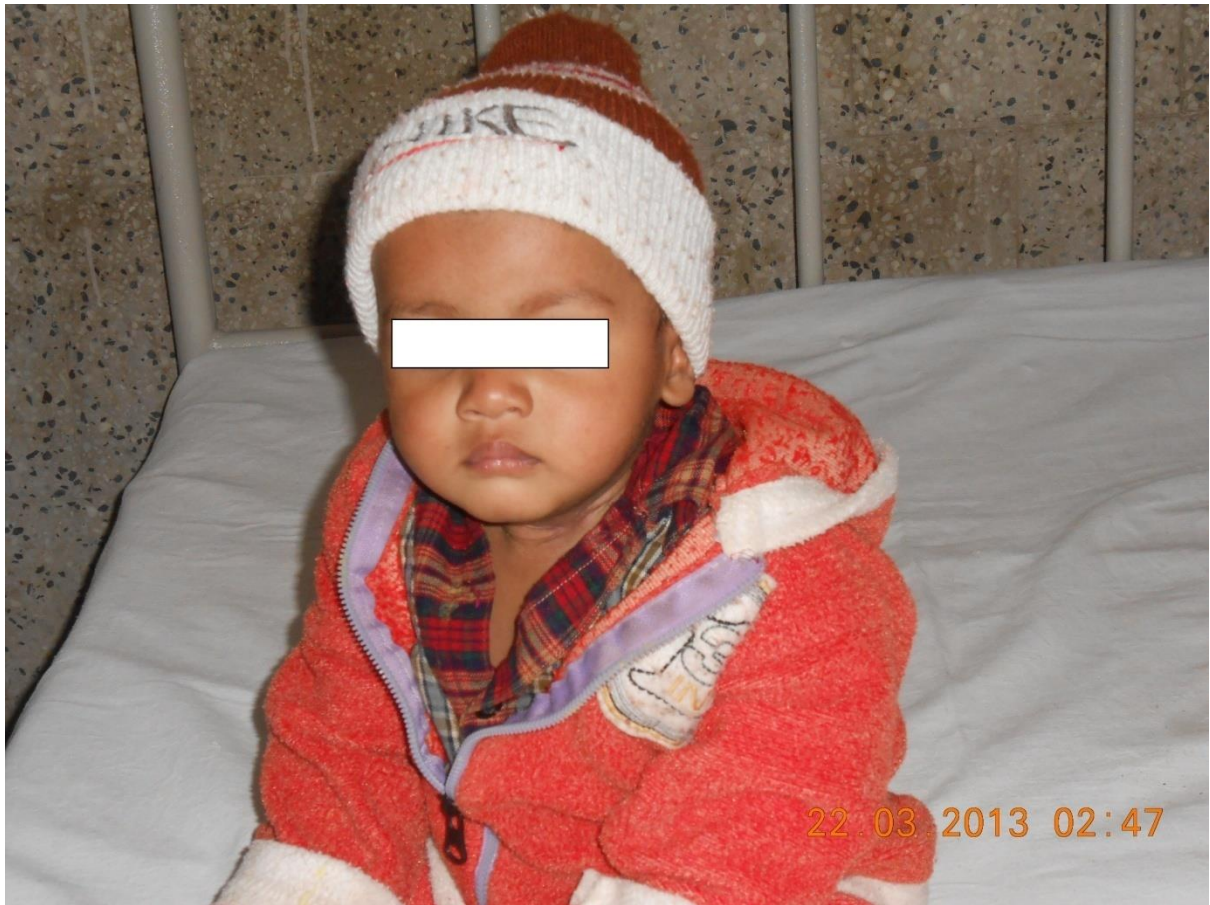

Figure12: eight weeks post operative.