



## Adenoid facies and chronic refractory rhinosinusitis managed by endoscopic-assisted adenoidectomy A Study

Sudhir M Naik<sup>1</sup>, Ravishankara S<sup>2</sup>, Mohan Appaji<sup>2</sup>, Goutham MK<sup>2</sup>, N Pinky Devi<sup>2</sup>, Sarika S Naik<sup>3</sup>

<sup>1</sup>Cosmetic Surgery Institute of India <sup>2</sup>KVG Medical College Sullia <sup>3</sup>Narayana Hrudayalaya, Bangalore.

### ABSTRACT

**Background /Objectives:** To study 30 cases of patients of chronic adenoiditis with adenoid facies and refractory chronic rhinosinusitis managed by endoscopic assisted adenoidectomy.

**Materials and method:** 7 cases of adenoid facies and 23 cases of chronic refractory rhinosinusitis with adenoiditis were managed by endoscopic assisted adenoidectomy during the study period of 12 months from August 2012 to July 2013.

**Result:** endoscopic assisted adenoidectomy proves to be more effective in managing adenoid facies and chronic refractory rhinosinusitis with adenoid hyperplasia.

**Conclusion:** visualization of the adenoid mass using endoscope helps complete removal of the diseased adenoids. Endoscopic assisted adenoidectomy is treatment of choice in adenoid facies and chronic refractory rhinosinusitis with adenoid hyperplasia and more effective than conventional adenoidectomy.

## INTRODUCTION

Adenoidectomy is a common procedure performed in the otolaryngological practice it is a safe and effective procedure, regardless of the methods employed.<sup>1</sup> Many different instruments and techniques have been utilized throughout the history of the procedure. The procedure is performed to treat chronic adenoiditis which are not responding to medical line of treatment.<sup>1</sup> It is indicated in enlarged adenoids causing obstructive sleep apnoea, recurrent serous otitis media, chronic resistant rhinosinusitis, adenoid facies and chronic suppurative otitis media.<sup>1,2</sup>

Visualizing the adenoids in the OPD is not possible in all children because the paediatric patient may not cooperate during postnasal mirror or endoscopic examination. Lateral radiographs of adenoids are routinely investigated before an adenoidectomy. We have previously used the adenoid curette technique transorally guided by digital palpation of the adenoids following soft palate retraction.

Several adenoidectomy methods have been well described in the literature. Adenoid curette guided by an indirect transoral mirror and a headlight is a simple and quick procedure that has already been in use for a long time. Endoscopic assisted adenoidectomy has more advantages than blind palpation and curettage and indirect transoral mirror assisted curettage. Recently a curved suction electrical coagulator and the curved microdebrider shaver guided by nasal endoscope have successfully been used.

Nasal endoscopy allows easy size assessment of the adenoid and improves the accuracy of the adenoidectomy via a transoral curette.

This method is particularly important for younger paediatric patients with smaller oral cavities, because the size assessment of the adenoids by conventional palpation and mirror examination is challenging and the placement of the adenoid curette guided by the indirect mirror is difficult.

### Materials and Methods:

This is a retrospective study of 30 operative cases of endoscopic assisted adenoidectomy done in medical college hospital. The cases were operated during the study period of 12 months from August 2012 to July 2013.

30 cases operated for chronic adenoiditis were included in the study. Of the 30 cases, 7 were presented with features of adenoid facies and 23 presented with features of chronic persistent rhinosinusitis. (fig 1,2) Of the 30 cases 16 were males and 14 were females and the all the patients ranged between 4 to 9 years. The follow-up duration ranged from 6-12 months. Mouth breathing and bad oral hygiene were seen in all cases. Hyponasal voice and snoring was seen in 22 patients, 7 patients complained of abnormal upper dentition, 8 had bilateral chronic suppurative otitis media and 4 had unilateral chronic suppurative otitis media. 23 patients had chronic refractory rhinosinusitis.

In our study, all the patients were diagnosed to have chronic adenoiditis, 27 patients chronic adeno-tonsillitis, 8 patients chronic adeno-tonsillitis with bilateral CSOM and 4 patients had chronic adeno tonsillitis with unilateral CSOM. Routine investigations was done in all the patients. X-ray of the neck and the nasopharynx lateral view was taken. (fig 3) Post-nasal examination could be done in only 11 patients. X-ray lateral view showed adenoid mass in almost all cases.

21 patients underwent tonsillectomy at the same sitting. All the patients underwent adenoidentomy under general anaesthesia with orotracheal intubation. 21 patients underwent adenotonsillectomy with orotracheal intubation. All the patients had decongestion of the nasal mucosa by ribbon gauze soaked with 0.05% oxymetazoline solution inserted for 5 minutes to shrink the nasal mucosa. A Boyle- Davis mouth gag was inserted to open the mouth widely as during the classic adenoidectomy. A throat pack was also inserted around the orotracheal tube to prevent any blood from entering the trachea. The nasal cavities and nasopharynx were examined with a zero-degree nasal endoscope (2.7 mm) after removing the decongestant nasal pack. In all 21 cases where adenotonsillectomy were performed adenoidectomy was performed first and tonsillectomy later. This is to avoid fogging of the endoscope with bleeding from tonsillectomy site.

The patients were operated in Rose's position with the neck extended. A suitably sized St Clair Thompson's adenoid curette was placed transorally into the nasopharynx. Under nasal endoscopic guidance, the blade of the adenoid curette was placed just above the superior border of the adenoid.

The lateral ends of the blade should just be away from the Eustachian tube area on both sides. The nasal endoscope was then taken out from the nose and the adenoid was curetted with a sustained force as in conventional curettage. In all the cases adenoid tissue was curetted out in piece meal. Transoral packing gauze was used for 3 to 5 minutes to control any bleeding below the soft palate, which usually stopped spontaneously. Tonsillectomy was then performed in 21 of the cases.

All of the patients did not have any postoperative complications and were followed up for 6-12 months. Symptoms of mouth breathing subsided in all the patients. All the 12 cases who had chronic suppurative otitis media did not have any future episodes of discharging ears during 12 months of follow up. In our study, the commonest symptoms are nasal obstruction, mouth breathing, snoring followed by nasal discharge. Mouth breathing and snoring subsided in all patients. Nasal obstruction was seen to persist in 6 patients, after surgery.

## Discussion:

Adenoidectomy is one of the most commonly performed paediatric procedures in the otolaryngology.<sup>1</sup> Adenotonsillectomy remains one of the most commonly performed surgical procedures in the paediatric age group, with the indications for surgery being obstructive sleep apnoea and chronic adenotonsillitis with refractory chronic rhinosinusitis.<sup>2</sup> The other common indications for the procedure include chronic otitis media (often combined with bilateral myringotomy and grommet) and adenoid facies (often combined with tonsillectomy).<sup>3</sup>

Rhinosinusitis continues to be a prominent problem in paediatric population with most patients failing conservative medical management and surgical line of treatment are indicated.<sup>3,4</sup> Adenoidectomy has shown improvement in chronic rhinosinusitis symptoms such as rhinorrhea, cough, post-nasal drip and halitosis.<sup>4</sup> In the paediatric population, adenoid hyperplasia is associated with nasal obstruction, rhinosinusitis, obstructive sleep apnoea, and recurrent otitis media.<sup>5</sup> Enlargement of the adenoids during early and middle childhood may occur in response to a variety of antigenic challenges including viruses, bacteria, allergens, foods, and environmental irritants.<sup>5</sup> Adenoid enlargement and inflammation may create problems in both the functional and mechanical obstruction of the eustachian tube resulting in the development of middle ear disease.<sup>6,7</sup> The beneficial effects of adenoidectomy in decreasing the number and duration of episodes of otitis media have been well established in randomized trials.<sup>8,9</sup> Similarly a significant decrease in the number of episodes of paediatric rhinosinusitis after adenoidectomy has been described.<sup>10</sup>

Adenoidectomy may benefit the middle ear by removing a source of infection from the nasopharynx and has been shown to be helpful in children over 4 years of age with chronic otitis media with effusion.<sup>9,11,12</sup> In contrast, the evidence of the efficacy of adenoidectomy in preventing recurrent episodes of acute otitis media is conflicting.<sup>10</sup> Chronic nasal obstruction and mouth breathing lead to characteristic facial appearance called adenoid facies.<sup>13</sup> Features of adenoid facies include an elongated face with dull expression, open mouth, prominent and crowded upper teeth and hitched up upper lip.<sup>13</sup> Nose gives a pinched –in appearance due to disuse atrophy of alae nasi.<sup>13</sup> Hard palate in these cases is highly arched as moulding action of the tongue on the palate is lost.<sup>13</sup>

The results of this analysis strongly suggest that adenoidectomy should be considered as first line therapy for medically refractory paediatric rhinosinusitis.<sup>4</sup> It is a simple, low risk procedure that can easily be performed on an day care basis with minimal required post-operative follow-up visits.<sup>4</sup> The current clinical indicators for adenoidectomy as recommended by the AAO-HNS in 2000 are: a) 4 or more episodes of recurrent purulent rhinorrhea in prior 12 months in a child <12. One episode documented by intranasal examination or diagnostic imaging. (b) Persisting symptoms of adenoiditis after 2 courses of antibiotic therapy.

One course of antibiotics should be with a beta-lactamase stable antibiotic for at least 2 weeks. (c) Sleep disturbance with nasal airway obstruction persisting for at least 3 months. (d) Hypo-nasal or nasal speech. (e) Otitis media with effusion >3 months or second set of tubes (f) Dental malocclusion or orofacial growth disturbance documented by orthodontist. (g) Cardiopulmonary complications including cor pulmonale, pulmonary hypertension, right ventricular hypertrophy associated with upper airway obstruction. (h) Otitis media with effusion over age 4. <sup>2</sup>

It is reported that in conventional adenoidectomy, there is always residual tissue in the posterior superior choanae of the nose and nasopharynx.<sup>14</sup> The problems of residual tissue remaining can be solved by the use of a nasal endoscope, which allows accurate placement of the adenoid curette at the superior border of the adenoids.<sup>14</sup> This positioning allows the complete transoral removal of the main bulk of the adenoid under vision and also removal of the lateral tissue of the adenoids without damaging the eustachian tube prominence.<sup>14</sup> The duration of surgery in endoscopic assisted methods is marginally more as some time is consumed in adjusting the endoscope.<sup>14</sup> However there is no difference in blood loss and postoperative recovery time.<sup>14</sup> In both the methods adenoid tissue was removed piece meal.<sup>14</sup> The EAA technique is minimally invasive, adds less than 5 minutes to the procedure, and is not associated with excessive bleeding.<sup>14</sup>

Recurrence of symptoms after adenoidectomy are most probably due to regrowth of residual lymphoid tissues left as a result of blind removal with conventional technique.<sup>15</sup> Also it is reported in literature that adenoids rarely regrow after adenoidectomy to cause nasal obstruction.<sup>16</sup> None of the patients operated by endoscopic assisted adenoidectomy came with recurrence of the adenoid tissue over a period of 6-12 months. Therefore, the use of endoscopic assisted adenoidectomy allows a more complete removal of the adenoids and in a more precise manner compared with conventional methods.<sup>14</sup>

Transoral endoscopic assisted adenoidectomy is a recent advancement of classic curettage adenoidectomy with direct vision of the nasopharynx that enables the surgeon to avoid injury of important structures as Eustachian tube orifices, and also it gives him the chance to completely remove the adenoidal tissues.<sup>17</sup> All the 30 cases treated with endoscopic assisted adenoidectomy were symptom free after 12 months of follow up. Endoscopic assisted adenoidectomy should be considered first line management of chronic refractory paediatric rhinosinusitis and chronic adenoiditis with mouth breathing and snoring. It is also surgical method of choice for treatment of adenoid facies.

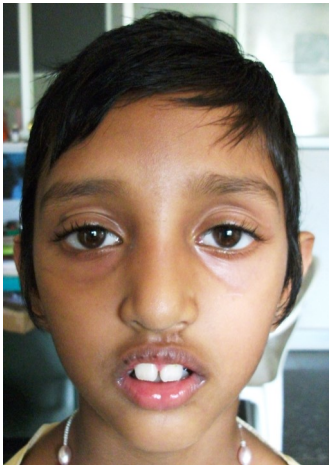

Figure 1 showing classic adenoid facies as seen frontally

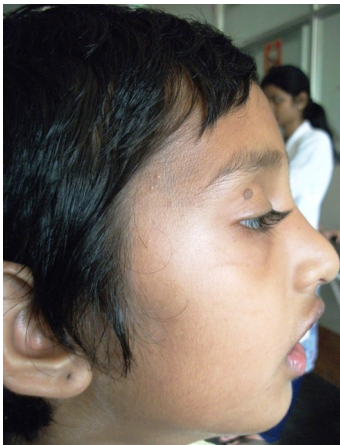


Figure 2 Adenoid facies as seen on profile view

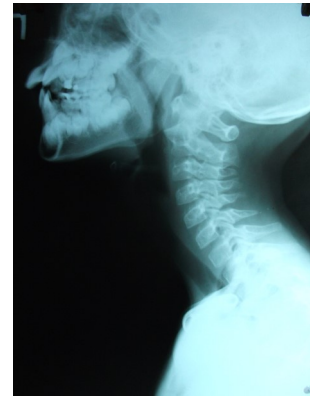

Figure 3 X-ray neck , nasopharynx lateral view, with enlarged adenoids

#### Conclusion:

Endoscopic assisted technique allows more complete removal of adenoid tissue without a significant increase in the operative time, blood loss or association with any postoperative complications. Both the conventional adenoidectomy in experienced hands and endoscopic assisted adenoidectomy have comparable success rates, but the adenoid tissue removed by endoscopic assisted adenoidectomy is more substantial and seems to be greater in total mass compared with conventional method. Endoscopic assisted adenoidectomy is an adjunct to performing a more complete adenoidectomy, thereby reducing the chances of developing recurrent adenoid obstructive symptoms and reducing the bacterial reservoir in the nasopharynx. The procedure costs are nearly equal as the endoscope is readily available in operation theatres.

## References:

1. Ambulatory and Inpatient Procedures in the United States, National Center for Health Statistics, 1996, [http://www.cdc.gov/nchs/data/series/sr\\_13/sr13\\_139.pdf](http://www.cdc.gov/nchs/data/series/sr_13/sr13_139.pdf).
2. Khalid Al-Abdulhadi, Rihab Al-Wotayan, Pooja Chodankar: Common throat infections: a review: Bulletin of the Kuwait Institute for Medical Specialization. 2007; 6:63-67.
3. National Ambulatory Medical Care Survey, National Center for Health Statistics, <http://www.cdc.gov/nchs/about/major/ahcd/ahcd1.htm>.
4. Scott E. Brietzke, Matthew T. Brigger: Adenoidectomy outcomes in pediatric rhinosinusitis: A meta-analysis: International Journal of Pediatric Otorhinolaryngology (2008) 72, 1541—1545.
5. C. Poje, L. Brodsky, Tonsillitis, Tonsillectomy, Adenoidectomy. Head and Neck Surgery—Otolaryngology, 3rd ed. 2001, 81; 979—1006.
6. T. Watanabe, T. Fujiyoshi, K. Tomonaga, et al., Adenoids and otitis media with effusion in children, Adv. Otorhinolaryngol. 47 (1992) 290—296.
7. J.M. Bernstein, H.F. Faden, D.M. Dryja, et al., Micro-ecology of the nasopharyngeal bacterial flora in otitis-prone and non-otitis prone children, Acta Otolaryngol. (stockh) 113 (1993) 88—92.
8. J.L. Paradise, C.D. Bluestone, D.K. Colborn, et al., Adenoidectomy and adenotonsillectomy for recurrent acute otitis media: parallel randomized clinical trials in children not previously treated with tympanostomy tubes, JAMA 282 (1999) 945—953.
9. G.A. Gates, C.A. Avery, T.J. Prihoda, J.C. Cooper Jr., Effectiveness of adenoidectomy and tympanostomy tubes in the treatment of otitis media with effusion, N. Engl. J. Med. 317 (1987) 1444—1451.
10. J.L. Paradise, C.D. Bluestone, K.D. Rogers, et al., Efficacy of adenoidectomy for recurrent otitis media in children previously treated with tympanostomy tube placement, JAMA 263 (1990) 2066—2073.
11. Sade J, Luntz M. Adenoidectomy in otitis media—a review. Ann Otol Rhinol Laryngol 1991;100:226-31.
12. Maw AR, Herod F. Otoscopy, impedance and audiometric findings in glue ear treated by adenoidectomy and tonsillectomy. Lancet 1986;1:1399-402.
13. Ravindhra G. Elluru et,al: Adenoid Facies and Nasal Airway Obstruction; Arch Otolaryngol Head Neck Surg. 2005;131:919-920.
14. Cannon CR, Replogle WH, Schenk MP. Endoscopic – assisted adenoidectomy. Otolaryngol Head Neck surg 1999;121:740-44.
15. K. S. Emerick and M. J. Cunningham, “Tubal tonsil hypertrophy: a cause of recurrent symptoms after adenoidectomy,” Archives of Otolaryngology—Head and Neck Surgery, vol. 132, no. 2, pp. 153–156, 2006.
16. F. J. Buchinsky, M. A. Lowry, and G. Isaacson, “Do adenoids regrow after excision?” Otolaryngology—Head and Neck Surgery, vol. 123, no. 5, pp. 576–581, 2000.
17. Transoral Endoscopic Adenoidectomy Amr El-Badrawy and Mosaad Abdel-Aziz; International Journal of Otolaryngology Volume 2009 (2009), Article ID 949315, 4 pages