

Acquired hypothyroidism in a 6 year old girl with Down's syndrome presenting with isolated menarche

Author(s): **Abdulkarim A. Al-Rabiaah**

Vol. 10, No. 1 (2006-10 - 2006-12)

Current Pediatric Research 2006; 10 (1 & 2): 51-53

Abdulkarim A. Al-Rabiaah

Department of Pediatrics, College of Medicine and King Khalid University Hospital, King Saud University, Riyadh, Kingdom of Saudi Arabia

Key words: Acquired hypothyroidism, Down's syndrome, precocious puberty, ovarian cysts, isolated menarche.

Accepted June 27 2006

Correspondence to:

Abdulkarim Al-Rabiaah

Department of Pediatrics, College of Medicine and King Khalid University Hospital

King Saud University

P.O. Box 2925 (39), Riyadh 11461

Saudi Arabia

e-mail: alrabiaah(at)gmail.com

Abstract

A 6 year old girl with Down's syndrome presented with cyclic vaginal bleeding, without other signs of sexual precocity, and bilateral ovarian cysts. Endocrine investigations indicated severe autoimmune hypothyroidism. Basal luteinizing hormone (LH) was suppressed and follicular stimulating hormone (FSH) was high, with high serum estradiol level and blunted response to GnRH test.

Introduction

It is not unusual for Primary hypothyroidism to present with precocious puberty as first described by Kendle in 1905 [1]. However it is very rare for this disease to present with an isolated menarche [2-6].

We report a 6 year old girl with Down's syndrome who presented with cyclical vaginal bleeding for the last three months. It was moderate in amount and each cycle lasted for three to four days. She had bilateral ovarian cysts without other signs of sexual precocity. Endocrine investigations indicated severe primary autoimmune hypothyroidism. We would like to draw the attention of the pediatricians and general practitioners to such a problem.

Case report

A 6 year old girl, who was known to have trisomy 21, referred to the endocrine clinic for evaluation of three episodes of monthly vaginal bleeding for the previous three months, each cycle lasting for three to four days. She was the product of full term vaginal breech delivery to healthy nonconsanguineous parents. At the age of three years, she was noted to be slow in her growth and tends to constipate. She was not on any medication. On admission, physical examination revealed a height of 102 cm (10-25th centile for Down's syndrome) and a weight of 26 kgs (>50th centile) with classical signs of Down's syndrome. Thyroid was not palpable. Vaginal bleeding was observed with no

breast or pubic hair development. Thyroid stimulating hormone (TSH) was elevated at 1130 mIU/L (N: 0.25-5), with very low free thyroxine (FT4) 1.7 pmol/L (N: 10-25).

Thyroid microsomal antibodies were strongly positive (1:25600), while thyroglobulin antibodies were negative.

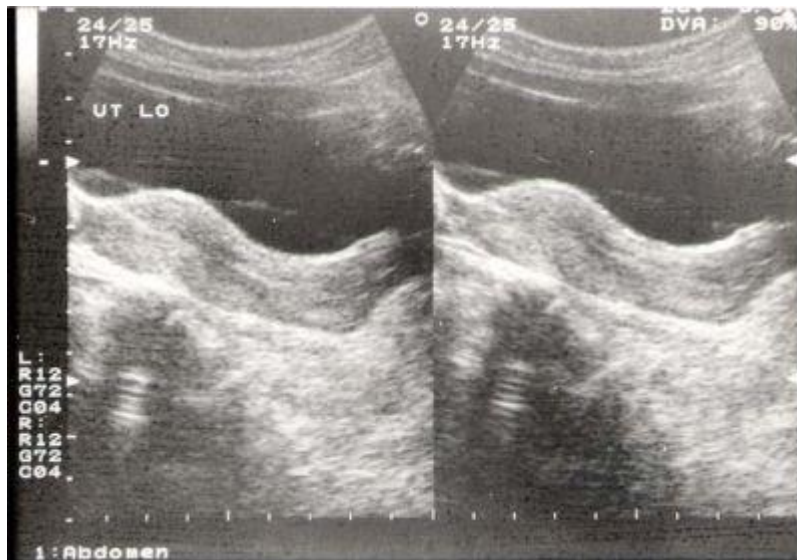
Basal luteinizing hormone (LH) was 0 IU/L, and follicle stimulating hormone (FSH) was 21 IU/L and high estradiol (E2) level at 134.5 pmol/L. GnRH (100µg IV) stimulating test revealed a blunted response.

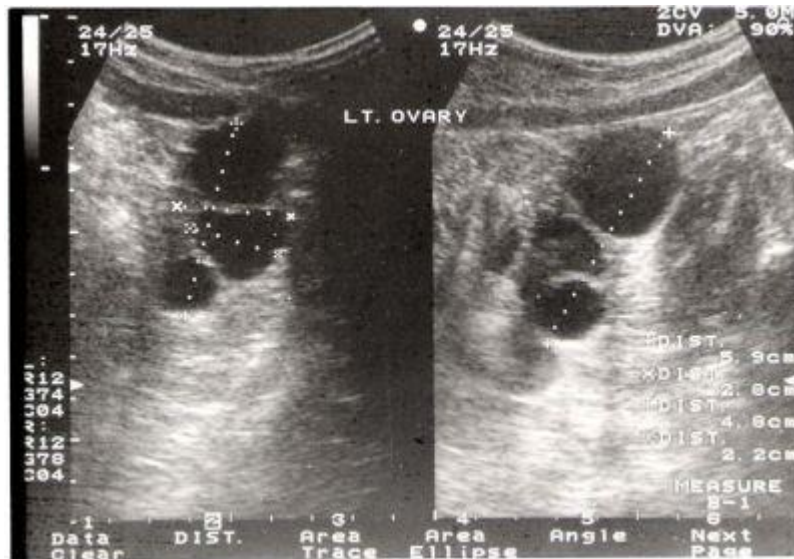
The abdominal sonogram (figure) showed a well developed adult type uterus with normal echo texture, endometrial lining and size of 6.5x3.5x1.8 cm. The left ovary measured 5.9x4.8x2.8 cm with multiple cysts, the largest measuring 2.5x2.6 cm. The right ovary measured 2.8x1.7x1.7 cm with a small cyst measuring 1.3x1.3 cm. CT brain revealed a normal sized pituitary gland. Bone age (Greulich and Pyle) was at 3 years.

Treatment with L thyroxine was initiated. Three months later, while clinically and biochemically euthyroid, she showed no further vaginal bleeding.

Figure 1: Abdominal sonogram showing:

(A) an adult sized uterus. (B) the left ovary; measures 5.9x4.8x2.8 cm with multiple cysts.





(For larger images, [click here](#) and [here](#))

Discussion

Children with primary hypothyroidism may present with abnormal sexual maturation. In both sexes, there is a loss of the consonance of pubertal development [7]. In girls, it is characterized by breast enlargement, large multicystic ovaries, which resolved rapidly with thyroid replacement, galactorrhea, vaginal bleeding which is rarely isolated [2- 6], and lack of pubic and axillary hair development which is secondary to normal adrenal hormonogenesis [8]. In patients with Down's syndrome, it is not easy to identify cognitive impairment and behavioral changes as in other normal children, leading to delay in diagnosis of hypothyroidism. Furthermore, this syndrome predispose to auto immune disorders, including chronic autoimmune thyroiditis [9].

In addition to have low serum thyroxine (T4) and a high thyroid stimulating hormone (TSH) concentrations, these children have been noted to have elevated basal serum prolactin (PRL) and follicle stimulating hormone (FSH) concentrations [3,7,10]. The pathogenesis of ovarian cyst formation or precocious puberty in hypothyroidism remains unclear due to the complexity of the endocrine interactions involved. Several mechanisms have been considered, such as over production of gonadotropins [2,11,-12], increased sensitivity to gonadotropins [13], increased aromatization of androstenedione to oestosterone [14], and high levels of TSH acting via the FSH receptor causing the gonadal stimulation [15], which seems to be the most likely, as it explains similar observations of the predominance of FSH mediated function (ovarian hyper- stimulation in girls and enlarged testes without other signs of virilisation in boys) over LH mediated functions [16].

Conclusion

Precocious puberty should be considered as a cause of vaginal bleeding, even in the absence of breast and pubic hair development. As bone age is generally greater than chronological age in almost all forms of precocious puberty, children with delayed bone age and precocious puberty should be evaluated for hypothyroidism. Children with Down's syndrome need a special attention as they are at higher risk of thyroid disease than others.

Acknowledgement

The author would like to thank Professor Nasir A. M. Al-Jurayyan for his guidance and assistance.

References

1. Kendle F. Case of precocious puberty in a female cretin. Br Med J 1905; 1: 246.

2. Van Wyk J, Grumbach M. syndrome of precocious menstruation and galactorrhea in juvenile hypothyroidism: an example of hormonal over lap in pituitary feed back. J Pediatr 1960; 57: 416-423.
3. Barnes ND, Hayles AB, Ryan RJ. Sexual maturation in juvenile hypothyroidism. Mayo Clin Proc 1973; 48: 849-856.
4. Piziak VK, Hahn Jr HB. Isolated menarche in juvenile hypothyroidism. Clin Pediatr 1984; 23: 177-179.
5. Rakover Y, Weiner E, Shalev E, Luboshitsky R. Vaginal bleeding: presenting symptom of acquired primary hypothyroidism in seven year old girl. J Pediatr Endocrinol 1993; 6: 197-200.
6. Lindsay A, Vorhess ML, MarGillivray M. Multicystic ovaries detected by sonography in children with hypothyroidism. Am J Dis Child 1993; 134: 588-592.
7. Pringle PJ, Stanhope R, Hindmarsh P, Brook CGD. Abnormal pubertal development in primary hypothyroidism. Clin Endocrinol 1988; 28: 479-486.
8. Burke G. "Pubertal" hypothyroidism: case report and review of literature. Metabolism 1961; 10: 126-133.
9. Karlsson B, Gustaffson J, Hedov G, Ivarsson S-A, An-neren G. Thyroid dysfunction in Down's syndrome: relation to age and thyroid autoimmunity. Arch Dis Child 1998; 79: 242-245.
10. Hemady ZS, Siler-khodr TM, Najjar S. Precocious puberty in juvenile hypothyroidism. J pediatr 1978; 92: 55-59.
11. Beitins I, Bode H. Hypothyroidism with elevated gonadotropin secretion. Pediatr Res 1980; 14: 475-476.
12. Lee PA, Blizzard RM. Serum gonadotropins in hypothyroid girls with and without sexual precocity. Johns Hopkins Med J 1974; 135: 55-60.
13. Mandi AM. Factors influencing ovarian sensitivity to gonadotropins. J Endocrinol 1957; 15: 448-457.
14. Adams WC, Senseman DM. Aromatization of androstenedione by induced polycystic ovaries in rat. J Steroid Biochem 1976; 7: 309-310.
15. Anasti JN, Flack MR, Froehlich J, Nelson LM, Nisula BC. A potential novel mechanism for precocious puberty in juvenile hypothyroidism. J Clin Endocrinol Metab 1995; 80: 276-279.
16. Gordon CM, Austin DJ, Radovick S, Laufer MR. Primary hypothyroidism presenting as severe vaginal bleeding in a prepubertal girl. J Pediatr Adolesc Gynecol 1997; 10: 35-38.

Correspondence to:

Abdulkarim Al-Rabiaah

Department of Pediatrics, College of Medicine and King Khalid University Hospital

King Saud University

P.O. Box 2925 (39), Riyadh 11461

Saudi Arabia

e-mail: alrabiaah(at)gmail.com