



A STUDY ON EFFICACY OF AUTOLOGOUS PLATELET RICH PLASMA IN MYRINGOPLASTY

**Authors: Dr. G.SANKARANARAYANAN M.S. (ENT)., DLO.,DNB.,
Dr.V.Prithiviraj MS.,
Dr.R.V.Kumar MBBS.,DLO.,**

First author is the Professor of ENT and the second author is Assistant Professor and third author is a Senior Resident attached to Department of ENT, The Government Kilpauk Medical College and Royapettah Hospital, Chennai, Tamilnadu, India.

Correspondence address :
Dr.G.Sankaranarayanan
Department of ENT,
Government Royapettah Hospital,
Chennai, Tamilnadu, India.

Permanent Residential address:
Dr.G.Sankaranarayanan,
No.39., Third east street,
Kamaraj nagar, Thiruvanmiyur,
Chennai, India -600041.
Phone : Off:044 28483051. Res : 044 24412839. Mob : 09444468277.
Fax:04428483272
E mail address : sankar.ent@gmail.com

A STUDY ON EFFICACY OF AUTOLOGOUS PLATELET RICH PLASMA IN MYRINGOPLASTY

ABSTRACT

Objective: To study the efficacy and advantage in using autologous platelet rich plasma during myringoplasty in closure of tympanic membrane perforation preventing the graft displacement, promoting quicker healing & improving overall outcome.

Methods : Platelet rich plasma (PRP) is an autologous platelet rich concentrate prepared from patient's own blood with growth factors up to 8 times that of normal serum and its efficacy when used during myringoplasty is studied. 50 patients with chronic otitis media inactive mucosal disease were randomly chosen and 25 of them were the study group and other 25 were the control group. Both group patients underwent myringoplasty and PRP was used in the study group and the results were evaluated.

Results: In our study among 25 cases that underwent myringoplasty with use of platelet rich fibrin, 24 had complete tympanic membrane closure and only one failure has been noticed. In controls 5 out of 25 cases had failure. The graft take up rate in our study is comparable with the reference studies. Use of PRP accelerates graft uptake.

Conclusion: Platelet rich plasma is a cheap and cost effective platelet concentrate with enriched growth factors. It accelerates the tympanic membrane closure following myringoplasty.

Keywords: Platelet rich plasma, myringoplasty, Autologous.

INTRODUCTION

Chronic suppurative otitis media is defined as chronic inflammation of the mucoperiosteal lining of the middle ear cleft. It is associated with persistent or intermittent discharge through a non intact tympanic membrane. It is prevalent in developing countries like India and is more common in lower socio economic groups. The incidence is very high among rural population than in urban population⁴. The overall prevalence rate is 46 and 16 persons per thousand in rural and urban population. Both anatomical and functional obstruction of the Eustachian tube can lead to failure of its functions which can result in otitis media¹. Tympanic membrane perforation may result from AOM, chronic otitis media, or trauma (injury or surgery). In some instances, a dry, simple perforation results from a single episode of AOM (i.e., necrotizing otitis media). In our study we analyze the case of chronic otitis media mucosal type only which is one of the common diseases seen in ENT OPD.

MATERIALS AND METHODS

Platelet rich plasma was first used in cardiothoracic surgery. M.Ferari used platelet rich plasma in 1987 after an open heart surgery. Now it is widely used in various fields like dentistry, orthopedics, otorhinolaryngology,

maxillofacial surgery, dermatology, plastic and cosmetic surgery, urology, wound healing etc².

Platelet isolated from the blood forms a rich autologous source of growth factors. When these platelets are concentrated and applied to the surgical site more predictable outcome can be expected. Platelet rich plasma is such an autologous platelet concentrate. A blood clot is the important factor in soft tissue healing in all natural wounds. Platelet rich plasma is a similar strategy where platelet concentrate which is an enriched natural blood clot is produced which initiate a more rapid and complete healing process. A natural blood clot usually contains 95% RBC's, 5% platelets, and less than one percent of white blood cells and numerous amount of fibrin strands. A platelet rich plasma blood clot contains 95% of platelet, 4% of RBC's and 1% of WBC's⁹.

PREPARATION OF PRP:

PRP can be prepared by two techniques³.

1. General-purpose cell separators
2. Platelet-concentrating cell separators

1. General-purpose cell separators:

They require large amount of blood (450 ml) and requires good hospital setup. Blood is drawn into the collection bag which contains citrate

phosphate-dextrose anticoagulant and is first centrifuged at 5,600 rpm to separate RBCs from platelet to get platelet poor plasma (PPP) and platelet rich plasma (PRP). Next the centrifugation speed is reduced to 2,400 rpm and final separation of about 30 ml of PRP is obtained from the RBCs. The remaining PPP and RBCs can be returned to the patient's body or can be discarded.

1. Platelet-concentrating cell separators:

They require small quantity of blood and can be prepared by in clinic itself. The preparation and the processing of PRP are similar in most of the platelet-concentrating systems but the anticoagulant used and the speed and duration of centrifugation might differ with different systems.

1. Venous blood is taken into a tube containing an anticoagulant which avoids platelet activation and degranulation.
2. The first centrifugation is a "soft spin", which separates blood into three layers, namely bottom-most layer containing RBC (55% of total volume), top most acellular layer called Platelet Poor Plasma- PPP (40% of total volume), and an intermediate Platelet Rich Plasma layer (5% of total volume) called the "Buffy coat".
3. Using a syringe PPP, PRP and some RBCs are transferred into another tube without an anticoagulant.

4. This tube now undergoes a second centrifugation; it is longer and faster than the first one, so called "hard spin". This allows the PRP to settle at the bottom of the tube with a very few RBCs. The acellular plasma (80% of the volume) is found at the top.
5. PPP is removed with a syringe and discarded and the remaining PRP is shaken well.
6. This PRP is mixed with bovine thrombin & calcium chloride during the time of application which results in gelling of this platelet concentrate.

SIDE EFFECTS OF PRP:

Since it is an autologous preparation, PRP is inherently safe and therefore it is free from transmissible diseases such as HIV, Hepatitis etc⁹. During the preparation of PRP calcium chloride and bovine thrombin are used. It has been found that the use of this bovine thrombin can lead to the development of antibodies to the factors V, XI and thrombin which results in the risk of life threatening coagulopathies. Bovine thrombin preparation contains factor V, which can result in the stimulation of immune system when challenged with a new protein.

PLATELET RICH FIBRIN (PRF):

PRF was first developed by Choukroun et al in France. It is usually called as second generation platelet rich plasma⁸. It has several advantages over traditional PRP. The chief advantages are

- The ease of preparation and
- The absence of biochemical handling of the blood, which makes this preparation purely autologous.

PREPARATION OF PRF:

The preparation of PRF is very simple procedure. Since we do not use bovine thrombin for the preparation; PRF is free from the associated risks.

- The required quantity of blood is taken into 10ml test tubes
- No anticoagulant is added.
- It is centrifuged immediately.
- Blood is centrifuged using a tabletop centrifuge, which is easily available in most of the labs.
- It is centrifuged for 12 min at 2,700 rpm.

The resultant product consists of the following three layers:

- Topmost layer consisting of acellular Platelet poor plasma.
- PRF clot is in the middle
- RBCs at the bottom⁹.

Because of the absence of the anticoagulant, blood begins to coagulate very soon when it comes in contact with the glass surface. So for successful preparation of PRF, quick blood collection and centrifuging it immediately before the clotting cascade is initiated is necessary. PRF can be applied to surgical site. In our study we have used this second generation platelet




Fig 1 platelet rich fibrin preparation

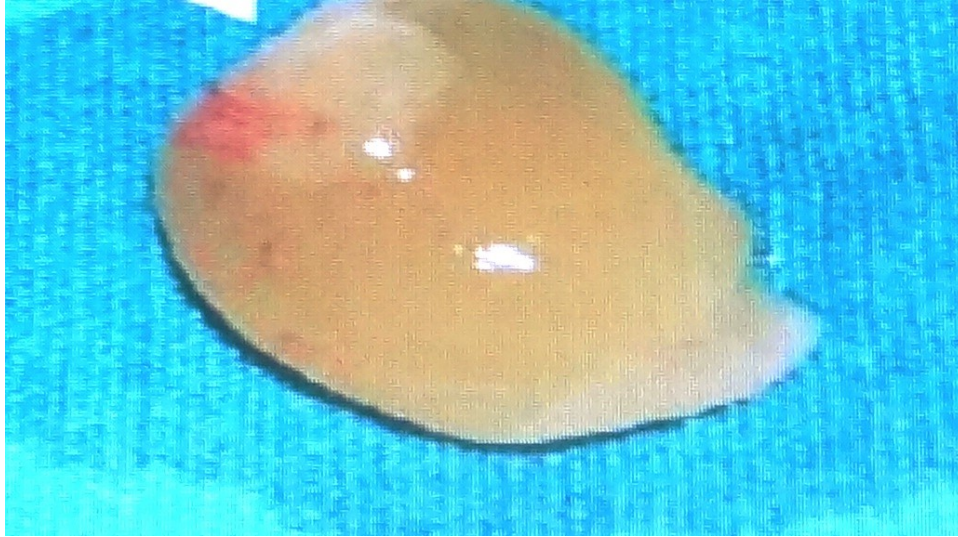


Fig 2 Middle PRF layer

rich concentrate. The growth factor content (PDGF and TGF- β) was comparable in both PRF and PRP. PRF has many advantages over usually prepared PRP. It eliminates adding anticoagulant and neutralizing it. The addition of bovine-derived thrombin which promotes the conversion of fibrinogen to fibrin in PRP is also eliminated. All these steps considerably reduce biochemical handling of blood and reduce the risk associated with the bovine derived thrombin. The conversion of fibrinogen into fibrin occurs slowly with the available small quantities of physiological thrombin present in the blood sample itself. Thus there is a normal physiologic architecture which is very favorable to the healing which is obtained due to this slow polymerization process⁷.

Our study is a Cohort study / Prospective Observational study of myringoplasty done in our institution, in patients with chronic otitis media inactive

mucosal disease (central perforation with dry ear). Children below 12 years of age , Active ear disease, Atopic ear conditions, Diabetes mellitus, Other systemic illness like autoimmune disease, active neoplastic disease , Patient on immunosuppressant drugs were excluded from the study. Patient in whom platelet rich plasma is not used for myringoplasty during the same study period are taken as control group.

Patient with chronic otitis media mucosal disease were randomly selected from the OPD of our institution. They were first subjected to examination under microscope. Ear examination with the aid of microscope is the gold standard for diagnosis of COM¹. Pus was sent for culture and sensitivity. The bacteriological culture is of potential value in starting specific antibiotics. All the patients with active ear disease were treated up to one month with specific antibiotics. Diagnostic nasal endoscopy was done for all patients. Those who had nasal obstruction and features of chronic sinusitis were subjected to computerized tomography of paranasal sinus. Patients with persistent symptoms and signs of chronic sinusitis after adequate medical treatment underwent Functional endoscopic sinus surgery with or without septal correction. Pure tone audiogram is done in all patients which is helpful in assessing degree and type of hearing loss.

After achieving dry ear for six to eight weeks, patient is subjected to X-ray of both mastoids – Law's view or lateral oblique view. X-ray showed sclerotic mastoid or clouding of air cells or cellular mastoid. Depending upon the

X-ray finding the surgical procedure was planned. Patients with sclerosed mastoids and clouding of air cells underwent cortical mastoidectomy with myringoplasty with or without ossicular reconstruction. Patients with cellular mastoid underwent myringoplasty alone with or without ossicular reconstruction⁵. Under lay myringoplasty was done and platelet rich fibrin was placed over the myringoplasty site.

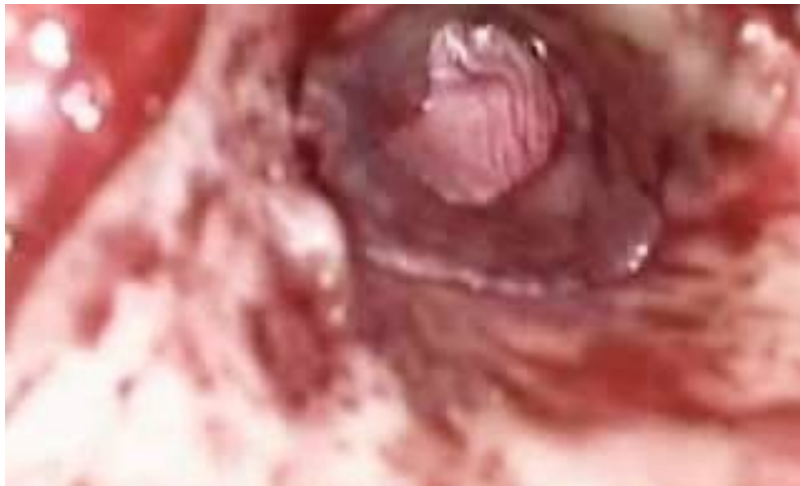

Fig 3 underlay myringoplasty done and PRF placed in myringoplasty site.

DISCUSSION

In our study out of the 50 patients who underwent surgery, 30 were females (60 percent) and 20 (40 percent) were males. The disease is common in 20 to 30 yrs age group in our study population. This disease is more common in lower

socioeconomic group due to overcrowding, poor sanitation, poor nutrition and illiteracy.

About 84 percent (42 patients) of people in the study population had unilateral ear disease whereas remaining 16 percent (8 patients) had bilateral disease. In study cases 19 patients had unilateral disease and 6 patients had bilateral disease. In controls 23 patients had unilateral disease whereas 2 patients had bilateral disease. Among the unilateral disease in controls 13 patients had right ear disease whereas 10 patients had left ear disease. Among study cases 7 patients had right ear disease and 12 patients had left ear disease. Bilateral disease is commonly due to bilateral Eustachian tube dysfunction.

In our study large and subtotal perforation is very common in comparison to other perforations. Among cases 2 patients had small perforation, 7 patients had medium, 6 patients had large and 10 patients had subtotal perforation. In controls 3 small, 2 medium, 11 large and 9 subtotal perforations was seen. According to the study conducted by [Braccini F](#) regarding the relevance of Choukroun's Platelet-Rich Fibrin (PRF) during middle ear surgery residual perforations were noticed in 4 percent of cases, all of them had large perforation preoperatively. Out of 6 failures in our study 5 occurred in large/ subtotal perforations which is similar to the above study.

X – Ray both mastoids was the important investigation based on which surgery for the patient is decided. All patients underwent this investigation after attaining dry ear for 6 to 8 weeks. Among cases 12 patients had well pneumatised mastoids, they underwent myringoplasty and 13 had sclerosed mastoids or clouding of air cells, they underwent cortical mastoidectomy with myringoplasty. Among control 6 patients had well pneumatised mastoids whereas 19 had sclerosed mastoids.

The graft take up rate in our study is comparable with the reference studies. According to [Maria Luisa Navarrete Alvaro](#) use of platelet rich plasma during myringoplasty had a satisfactory result². A study was conducted by Mehmet Habesoglu M.D in 2011 among 32 patients with acute tympanic membrane perforations. He concluded that use of platelet rich fibrin accelerated the tympanic membrane closure. In our study among 25 cases that underwent myringoplasty with use of platelet rich fibrin, 24 had complete tympanic membrane closure and only one failure has been noticed. In controls 5 out of 25 cases had failure. At the end of first month follow up, 72 percent of cases had closure of tympanic membrane, while only 40 percent of controls had tympanic membrane closure. At the end of second month 92 percent of cases had closure while only 72 percent of control had closure. At the end of 3 months 96 percent of cases had closure,

whereas only 80 percent of control had closure. Thus Our study shows that autologous platelet concentrates accelerates the tympanic membrane closure³.

Among cases, only one failure is noted which is due to infection. Among controls, 5 failures were noted 4 of them due to graft displacement and one due to infection. According to [Maria Luisa Navarrete Alvaro](#) use of platelet rich plasma during myringoplasty will prevent graft displacement, which is seen in our study also⁽²⁾⁽³⁾⁽⁶⁾⁽⁷⁾.

CONCLUSION

Platelet rich plasma is a cheap and cost effective platelet concentrate with enriched growth factors. It accelerates the tympanic membrane closure following myringoplasty. It prevents graft displacement. It improves the overall success rate of myringoplasty. It has no noticeable side effects.

REFERENCES

1. Michael Gleason/ Scott Brown's, otorhinolaryngology head and neck surgery – 7th edition – volume 3 – chronic otitis media : pages:– 3395 -3445.
2. [Maria Luisa Navarrete Alvaro](#), [N. Ortiz](#), [L. Rodriguez](#), [R. Boemo](#), [J. F. Fuentes](#), [A. Mateo](#), and [P. Ortiz](#) - Research Article on Pilot Study on the Efficiency of the Biostimulation with Autologous Plasma Rich in Platelet Growth Factors in Otorhinolaryngology: Otologic Surgery (Tympanoplasty Type I) - ISRN Surgery Volume 2011 (2011), Article ID 451020, 4 pages issue 2011.

3. Mehmet Habesoglu M.D.; Cagatay Oysu M.D.; Serap Sahin M.D.; Asli Sahin-Yilmaz M.D.; Deniz Korkmaz M.D.; Ahmet Tosun M.D. - Umraniye Education & Research Hospital, Department of Otorhinolaryngology – Platelet rich fibrin for repair of tympanic membrane.
4. Anil K. Lalwani- Current diagnosis and treatment in otolaryngology – Head and Neck surgery
5. Byron J. Bailey and Jonas T. Johnson Head and neck surgery – otolaryngology - 4th edition
6. [Erkilet E](#), [Koyuncu M](#), [Atmaca S](#), [Yarim M](#). - Platelet-rich plasma improves healing of tympanic membrane perforations: experimental study - [J Laryngol Otol](#). 2009 May; 123(5):482-7. Epub 2008 Oct 28.
7. [Braccini F](#), [Tardivet L](#), [Dohan Ehrenfest DM](#) - The relevance of Choukroun's Platelet-Rich Fibrin (PRF) during middle ear surgery preliminary results - [Rev Laryngol Otol Rhinol \(Bord\)](#). 2009; 130(3):175-80
8. [Choukroun JI](#), [Braccini F](#), [Diss A](#), [Giordano G](#), [Doglioli P](#), [Dohan DM](#) - Influence of platelet rich fibrin (PRF) on proliferation of human preadipocytes and tympanic keratinocytes: A new opportunity in facial liposuction (Coleman's technique) and tympanoplasty - [Rev Laryngol Otol Rhinol \(Bord\)](#). 2007;128(1-2):27-32.
9. Sunitha Raja V, Munirathnam naidu E – Platelet rich fibrin – Evolution of a second generation platelet concentrate – Indian J Dent Res 2008; 19:42-6.