



A Rare Cause of Diminished Vision: Large Spheno-Ethmoidal Mucocele

Adouly T*, Adnane C, Zouak A, Elhani L, Rouadi S, Abada R, Roubal M and Mahtar M

Department of ENT, 20 Août Hospital, IBN Rochd University Hospital, Casablanca, Morocco

*Corresponding author: Adouly T, Department of ENT, 20 Août Hospital, IBN Rochd University Hospital, Casablanca, Morocco, E-mail: adouly.taoufik@gmail.com

Received: April 06, 2016; **Accepted:** June 01, 2016; **Published:** June 07, 2016

ABSTRACT

Sphenoid sinus mucocele comprises only 2% of all paranasal sinus mucoceles which can compress on the optic canal or inferior orbital fissure, and causing loss of vision. One case with sphenoidal sinus mucocele is reported and discussed. A 45 years-old male was complaining of decrease in vision in the right eye and severe headache at the right-sided. Computed tomography showed a right sphenoidal sinus mucocele with right ethmoidal extension and compressing the right inferior orbital fissure and the right optic nerve. The lesion was removed through an endonasale sphenoidotomy. Histological examination confirmed diagnosis. The patient's follow-up for the last six months was normal with normal vision. The rarity of sphenoidal sinus mucocele made our case interesting to report.

Keywords: Sphenoid sinus; Mucocele; Optic nerve; Headache; Surgery

Introduction:

Mucoceles are benign, encapsulated, locally invasive masses within a paranasal sinus, filled with mucus and lined by respiratory epithelium. However, the sphenoid sinus is the least common site of the paranasal sinuses, representing 1-2%¹. The presenting symptoms are primarily caused by compression on contiguous neurological and vascular structures². Diminished vision is a common presenting symptom. The authors report a case of a large sphenoid sinus mucocele associated with ophthalmic symptomatology and headache in order to describe the presenting symptoms, location, and management of this rare disease.

Case History:

A 45-year-old male, presented with gradual decrease in vision in the right eye and severe headache also at the right-sided for the past six months. There were no associated nasal symptoms. The patient denied any history of paranasal sinus disease or trauma.

Rhinological examination, indicated congestion on the right side but nothing else of note. Nasal endoscopic examination found no nasal polyposis or mass. Ophthalmic examination revealed a decrease of visual acuity in the right eye (7/10) and (10/10) in the left. Eye movements were normal. The neurological examination and the cranial nerves and peripheral nervous system examination was otherwise normal.

A systemic examination was unremarkable. Computed tomography (CT) of the head revealed a large, well-defined lobulated mass, measuring 67 mm × 42 mm × 32 mm arising from sphenoid sinus with extension into the right ethmoidal and compressing the right inferior orbital fissure and the right optic nerve. It was responsible of marked thinning of the internal wall of the orbit without erosion of the bony. There was no evidence of calcification or any fat density within the lesion. The diagnosis of a large sphenoethmoidal mucocele was suspected (Figures 1 and 2).

The patient underwent an endoscopic right sphenoidotomy and drainage of the mucocele. The postoperative course was uncomplicated (no bleeding or cerebrospinal fluid leakage). Histopathology was suggestive of mucocele lined with pseudo stratified columnar epithelium. The man's vision gradually

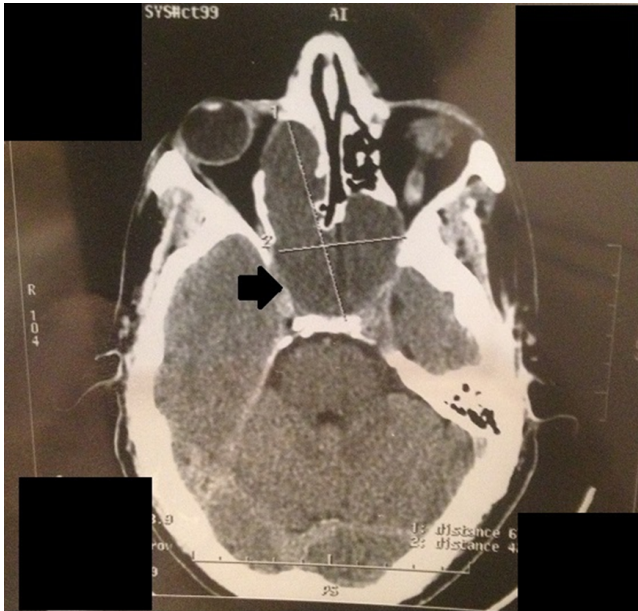

Figure 1: Axial CT revealed a large mass in sphenoid sinus with extension into the right ethmoidal with marked thinning of the internal wall of the orbit.

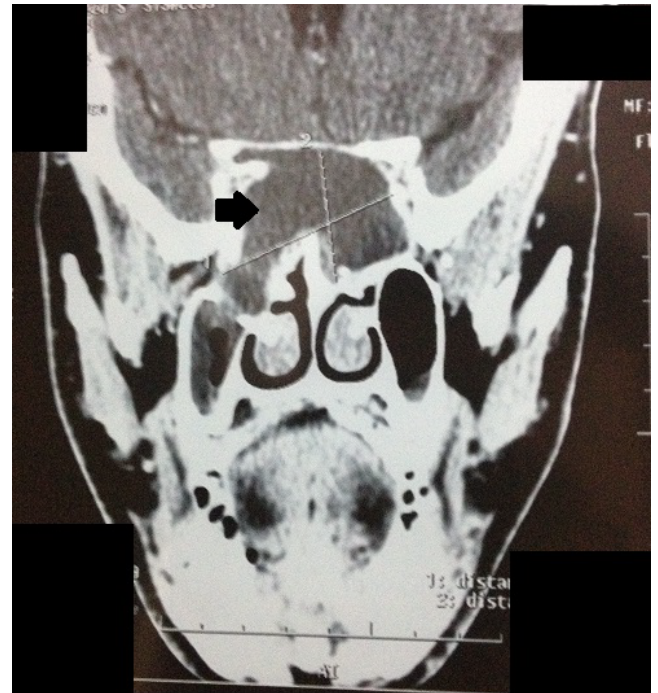


Figure 2: Coronal CT revealed a large mass in sphenoid sinus.

improved after operation. The patient was still free of symptoms with normal vision after six months.

Discussion:

In 1872, Rouge identified the first case of sphenoid sinus mucocele and later described by Berg in 1889². Mucoceles are benign lesions, expansile and locally destructive, causing erosions of the bony walls of the sinus³. Approximately two-thirds of all mucoceles are commonly found in the frontal sinuses, and the majority of the remainder involves the ethmoidal sinus^{4,5}. The aetiology of sphenoid sinus mucocele is still unknown. Proposed theories for development of mucocele include cystic dilatation of the glandular structures and cystic development of embryonic epithelial residues^{6,7}. Furthermore, Trauma and chronic inflammation (polypoid sinusitis) are considered to be causes of mucocele formation^{8,9}. In the literature, some authors suggested also that late complication of radiotherapy to the head and neck can cause sphenoid sinus mucocele formation by scarred mucosa which occludes the sinus ostium¹⁰. Our patient didn't have any risk factor for the development of a mucocele. The clinical manifestation of sphenoid sinus mucocele is dependent on the sinus anatomy and its contiguous neurological and vascular structures such as: cranial nerves II-III-IV-V-VI, the cavernous sinus, the carotid artery, the pituitary gland². The most common symptom of sphenoid sinus mucoceles is headache¹¹. It can be caused by mechanical pressure on the sinus anatomy; stretching of the

dura covering the planum sphenoidale and the floor of the anterior cranial fossa or by cytokines and their role in modulation of the pain threshold, and also in trigeminal sensitization^{12,13}. Other visual symptoms include diplopia; ocular muscle paresis; exophthalmus and complete visual loss are reported⁷⁻¹⁴. Computed tomography (CT) and Magnetic resonance imaging (MRI) are the imaging techniques of choice. Mucocele appears like a hypodense non enhancing mass that fills and distorts the sinus cavity on CT, and with a low signal on T1-weighted MRI and a high signal on T2-weighted MRI due to their high water content¹⁵. Usually, there is no enhancement, or at most marginal enhancement on CT or MRI (T1). The differential diagnosis includes pituitary tumour, craniopharyngioma, epidermoid, chordoma, dermoid, aneurysm, metastatic lesions and arachnoid cyst^{16,17}. The recommended management of a mucocele of the sphenoid sinus is endonasal sphenoidotomy with drainage and marsupialization of the mucocele¹⁸. After six months, our patient reported an improvement in symptoms post-operatively, and showed no recurrence.

Conclusion:

Sphenoid sinus mucocele is a rare entity. Imaging is crucial to diagnosis. Endoscopic drainage is safe and effective in eradication of disease. The rarity of sphenoidal sinus mucocele made our case interesting to report.

References

1. Kosling S, Hintner M, Brandt S (2004) Mucocele of the sphenoid sinus. *Eur J Radiol* 51: 1-5.
2. Stankiewicz JA (1989) Sphenoid sinus mucocele. *Arch Otolaryngol Head Neck Surg* 115: 735-740.
3. Buckmuhl U, Kratzsch B, Benda K, Draf W (2005) Paranasal sinus mucoceles: surgical management and long term results. *Laryngorhinootologie* 84: 892-298.
4. Levy J, Monos T, Puterman M (2005) Bilateral consecutive blindness due to sphenoid sinus mucocele with unilateral partial recovery. *Can J Ophthalmol* 40: 506-508.
5. Akan H, Cihan B, Celenk C (2004) Sphenoid sinus mucocele causing third nerve paralysis: CT and MR findings. *Dentomaxillofac Radiol* 33: 342-344.
6. Friedman A, Batra PS, Fakhri S (2005) Isolated sphenoid sinus disease: etiology and management. *Otolaryngol Head Neck Surg* 133: 544-550.
7. Sundar U, Sharma AL, Yeolekar ME (2004) Sphenoidal sinus mucocele presenting as monocular painless loss of vision. *Postgrad Med J* 80: 40-43.
8. Uren BA, Berkowitz RG (2003) Isolated inflammatory sphenoid sinus disease in children. *Ann Otol Rhinol Laryngol* 112: 370-372.
9. Malard O, Gayet-Delacroix M, Jegoux F (2004) Spontaneous sphenoid sinus mucocele revealed by meningitis and brain abscess in a 12-year-old child. *AJNR* 25: 873-875.
10. Rejab E, Said H, Saim L, Thim L (1991) Sphenoid sinus mucocele: a possible late complication of radiotherapy to the head and neck. *J Laryngol Otol* 105: 959-960.
11. Giovannetti F, Filiaci F, Ramieri V, Ungari C (2008) Isolated sphenoid sinus mucocele: etiology and management. *J Craniofac Surg* 19: 1381-1384.
12. Iqbal J, Kanaan I, Ahmed M, al-Homsi M (1998) Neurosurgical aspects of sphenoid sinus mucocele. *Br J Neurosurg* 12: 527-530.
13. Kariya S, Okano M, Hattori H, Sugata Y, Matsumoto R, et al. (2007) Expression of IL-12 and T helper cell 1 cytokines in the fluid of paranasal sinus mucoceles. *Am J Otolaryngol* 28: 83-86.
14. Jaime L, Tova M, Moshe P (2005) Bilateral consecutive blindness due to sphenoid sinus mucocele with unilateral partial recovery. *Can J Ophthalmol* 40: 506-508.
15. Levine HL, Clemente MP, Levine HL, (2004) In: editor. *Sinus surgery: endoscopic and microscopic approaches*. New York: Thieme Medical Publishers pp: 77.
16. Yokoyama T, Inoue S, Imamura J, Nagamitsu T, Jimi Y, et al. (1996) Sphenoidal mucoceles with intracranial extension – three case reports. *Neurol Med Chir (Tokyo)* 36: 822-828.
17. Hejazi N, Witzmann A, Hassler W (2001) Ocular manifestations of sphenoid mucoceles: clinical features and neurosurgical management of three cases and review of the literature. *Surg Neurol* 56: 338-343.
18. Khong JJ, Malhotra R, Wormald PJ, Selva D (2004) Endoscopic sinus surgery for paranasal sinus mucocele with orbital involvement. *Eye* 18: 877-881.