



## A rare case of solitary toxic nodule in a 3yr old female child – a case report

\*Chandrasekaran Maharajan

\* Poongkodi Karunakaran

\*Madras Medical College

### ABSTRACT

A three year old hyperactive female child presented with a midline neck swelling of one year duration. Clinical examination revealed a nodule in the isthmus of thyroid. Her Thyroid Stimulating Hormone (TSH) was suppressed and Free T3 and Free T4 levels were elevated. Radionuclide scintigraphy showed a hyperfunctioning nodule in the isthmus of thyroid. Patient was administered antithyroid medication and brought to euthyroid state. Isthmectomy was done. Post-operative period was uneventful. Patient was discharged on third post-operative day and is on regular follow up.

**KEY WORDS:** Toxic nodule, isthmectomy, scintigraphy

### CASE REPORT

A three year old hyperactive female child presented with a neck swelling of one year duration. Patient had no other features suggestive of hyperthyroidism. There was no history of endocrine disorder or malignancy in the family. There was no exposure to radiation.

Clinical examination revealed a well defined, non tender nodule in the isthmus of thyroid. She did not have any cervical lymphadenopathy. She had multiple café au-lait spots with irregular borders over the abdomen and right thigh. Ultrasound of the neck showed an isthmic nodule with increased vascularity. TSH was less than 0.01uIU/ml (reference range: 0.35-5.5 uIU/ml), Free T3 was 4.8 pg/ml (reference range: 1.7-4.2 pg/ml) and FT4 was 3.5 ng/dl (reference range: 0.7-2 ng/dl). Thus, the TSH was suppressed and FT3, FT4 levels were elevated. <sup>99m</sup>Tc pertechnetate thyroid scintigraphy (Fig.1) showed 3% uptake and hyperfunctioning nodule in the isthmus of thyroid. Serum calcitonin, the tumour marker for medullary carcinoma was estimated. It was 3 pg/ml (Normal value:< 10pg/ml). FNAC was hemorrhagic with few scattered bare nuclei and inconclusive.

Patient was given antithyroid medication, carbimazole 2.5mgBD for 2 months. She became euthyroid and was taken up for surgery. Intraoperative finding was a well encapsulated isthmic nodule measuring 3\*3\*1cm in size and the rest of the thyroid was normal(Fig.2). Hence, Isthmectomy was done. On macroscopic examination, it was an encapsulated, tan-brown nodule replacing entire isthmus. Cut section of the nodule showed central cystic change containing brown hemorrhagic fluid (Fig.3,4). Histopathological examination revealed a colloid cyst with papillary hyperplasia(Fig.5).

Post operative period was uneventful. Patient was discharged on third post operative day (Fig.6). Patient is on regular follow up.

## DISCUSSION:

A true solitary nodule is quite rare in the first two decades of life<sup>1,2</sup>. The prevalence of thyroid nodules in children is 0.22-1.35% as opposed to the adult population, in which the prevalence is closer to 4%. Suspected thyroid nodules merit close attention because the risk of malignancy is higher in children than adults. It is found that 20% of thyroid nodules in children harbour malignancy<sup>3,4</sup>. In addition, thyroid cancer is much more aggressive in children and is associated with early metastasis to regional lymph nodes and parenchymal organs, most commonly lung and bone. The risk of malignancy in hot nodules in children is estimated around 15% (compared with < 1% in adults). Thus, one major goal of the diagnostic evaluation of thyroid nodules is to differentiate thyroid cancers, especially aggressive lesions, from benign adenomas.

Most children with thyroid nodule come to the attention of a physician because of mass in the thyroid region. The majority of the children with autonomous thyroid nodules are clinically euthyroid, in contrast to adults<sup>5</sup>. Development of hyperthyroidism occurs predominantly in nodules greater than 3cm in diameter<sup>6</sup>, with a minimal volume of 16ml by ultrasound<sup>7</sup>. The early onset hyperthyroidism may be associated with McCune Albright syndrome, a syndrome characterized by polyostotic fibrous dysplasia, multiple café au-lait spots and hyperfunctioning endocrinopathies. It is more common in girls and the age of onset of hyperthyroidism is between 3 and 12 yrs.

The differential diagnosis of thyroid nodules in children should also include other benign thyroid conditions such as: (i) congenital hypothyroidism due to dysmorphogenesis or ectopy, (ii) thyroid hemiagenesis, (iii) thyroglossal duct cyst, (iv) simple goiter, (v) cystic lesion, (vi) nodular hyperplasia, (vii) follicular adenoma, (viii) Graves' disease and (ix) Hashimoto thyroiditis.

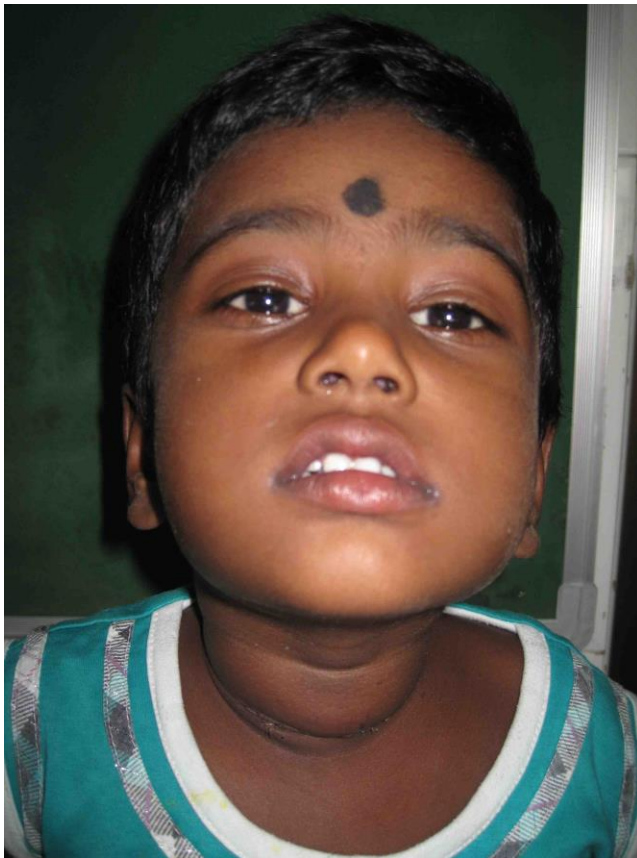Hence, to improve the preoperative diagnosis, a careful work-up comprising the patient's history, clinical examination, laboratory tests, thyroid ultrasound, scintigraphy, fine-needle aspiration cytology (FNAC) and molecular studies, is necessary.

Ultrasound is a safe and widely available technique, and is used as the first-line screening diagnostic test in all pediatric patients with thyroid nodules. Colour-Doppler sonography may be helpful in hyperfunctioning nodule indicating an intensive vascular flow within a highly vascularised lesion, and no visible flow through the remaining suppressed thyroid gland.

If a thyroid swelling is diagnosed as a truly solitary solid thyroid nodule, Fine Needle Aspiration cytology should be done to obtain definitive diagnosis. Radioisotope scintigraphy is helpful to classify its activity into hot, warm, or cold. Radioactive iodine uptake characteristics of nodules can direct treatment and assist in estimating risk of

malignancy. Radionuclide  $I^{123}$  scintigraphy enables to study both the trapping and organification by the nodules. On the other hand, Technetium pertechnetate image demonstrates only the trapping by the nodule. The diagnosis of a hyperfunctioning or hot nodule is established when the image reveals increased accumulation of the radioisotope in the nodule and decreased or absent uptake in the surrounding thyroid tissues.

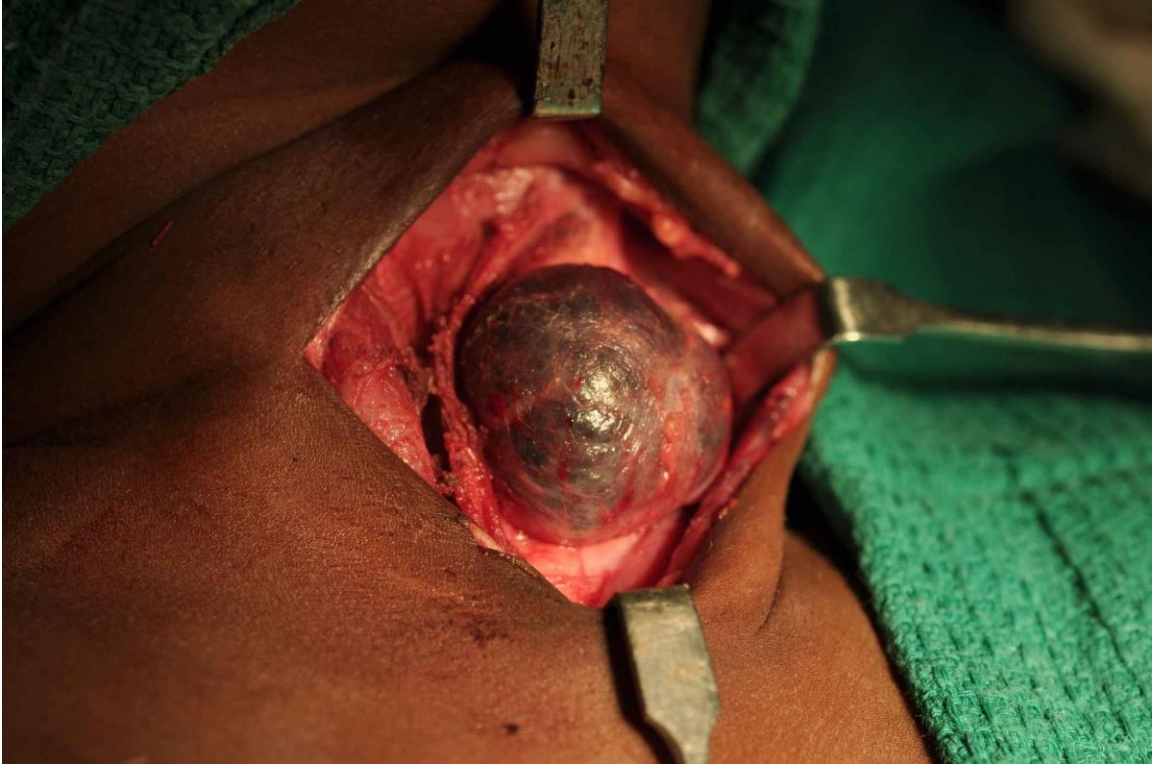Surgical treatment is preferred for all children and adolescents with solitary toxic nodule after preoperative antithyroid medication, because of the risks of thyroid carcinoma. If the nodule is present in a thyroid lobe, we proceed with hemithyroidectomy. If the nodule is in the isthmus, we prefer isthmectomy to hemithyroidectomy, because hemithyroidectomy may cause compensatory hypertrophy of the opposite lobe due to the removal of larger volume of normally functioning thyroid tissue. In addition, isthmectomy has the advantage of avoiding injury to the recurrent laryngeal nerve and parathyroids on both sides. It renders the patient euthyroid and gives better cosmesis. Antithyroid drug therapy is considered for short term preoperative management to bring the patient to euthyroid state. Administration of iodides is not indicated in the preoperative treatment of AFTNs. Radioiodine is not given in children because RAI may precipitate a malignant transformation at a later date.



Clinical Photograph of the patient




Image showing Tc 99 Scintigraphy performed on this patient



Per operative picture showing nodule arising from isthmus region

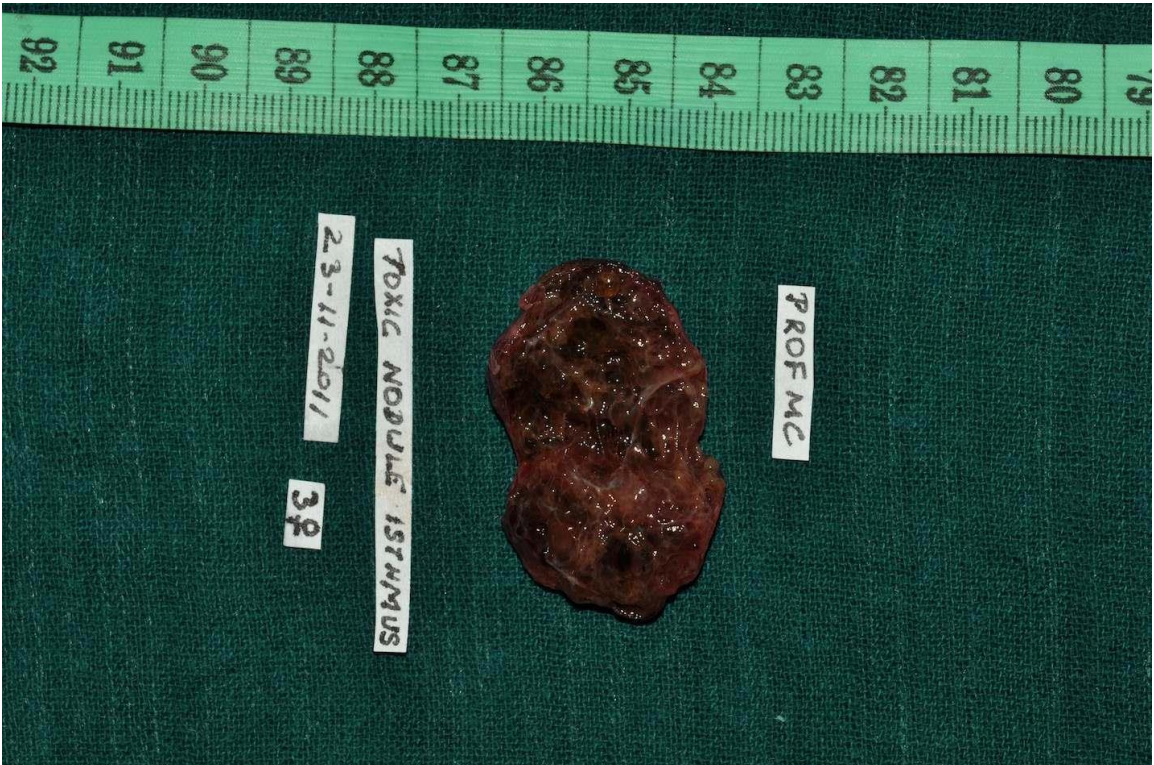

Image showing cut section of the specimen

## REFERENCE:

1. . Hung W (1999). Solitary thyroid nodules in 93 children and adolescents. *Horm Res* 52:15.
2. Bauer AJ, Tuttle RM, Francis GL (2002). Differentiated thyroid carcinoma of children and adolescents. *The Endocrinologist* 12:135.
3. Parcini F, DeGroot LJ, (2006). Thyroid neoplasia. In DeGroot LJ, Jameson JL(eds.), *Endocrinology*, fifth edition. Philadelphia: Elsevier-Saunders 2147-2180.
4. Schlumberger MJ, (1998). Papillary and follicular thyroid carcinoma. *N Engl J of Med* 338:297.
5. Abe K, Konno M, Sato T, Matsuura N, (1980). Hyperfunctioning thyroid nodules in children. *Am J Dis Child* 134:961.
6. BransamCJ, Jalbot CH, Henry J et al: Solitary toxic adenomaof thyroid gland, *Br J Surg* 66: 590, 1997.
7. Emrich D,Erlenmaier U, Dohl M, et al: Determination of the autonomously functioning volume of thyroid, *Eur J Nucl Med* 20: 410, 1993.