

A catastrophic mechanical complication of a neglected myocardial infarction.

Mahmoud Abdelnaby¹, Moustafa Dawood¹, Yehia Saleh^{1,2}, Abdallah Almaghraby²

¹Department of Clinical and Experimental Internal Medicine, Cardiology and Angiology Unit, Medical Research Institute, University of Alexandria, Egypt

²Michigan State University, East Lansing, USA

Accepted on Sept 28, 2018

Clinical Image

A 50-year-old male patient, heavy smoker and cannabis abuser with no past medical or surgical history, presented to our facility complaining of dyspnea grade III for two days and he recalled an attack of retrosternal chest pain in the past one week but he didn't seek any medical advice. On clinical examination, he was tachycardic and distressed with a loud harsh ejection systolic murmur heard over the lower end of the sternum was noted. Urgent Transthoracic Echocardiography (TTE) showed reduced LV systolic function with dilated dimensions and a large non-restrictive ventricular septal rupture (VSR) located at the apicoseptal segment (Panel A) with a left to right shunt. (Panels B and C) with a gradient of 45 mmHg (Panel D). Urgent coronary angiography revealed proximal total left anterior descending (LAD) artery occlusion and the patient was referred for urgent surgery but unfortunately during the surgery, the patient passed away (Figure 1).

Ventricular septal rupture (VSR) is a rarely seen catastrophic complication in the setting of acute myocardial infarction (AMI). While the incidence of this complication was reduced significantly at the percutaneous coronary intervention (PCI) era, yet still the mortality remains significantly high. VSR often results in cardiogenic shock, right ventricular dysfunction and requires immediate surgical repair with high incidence of surgical mortality.

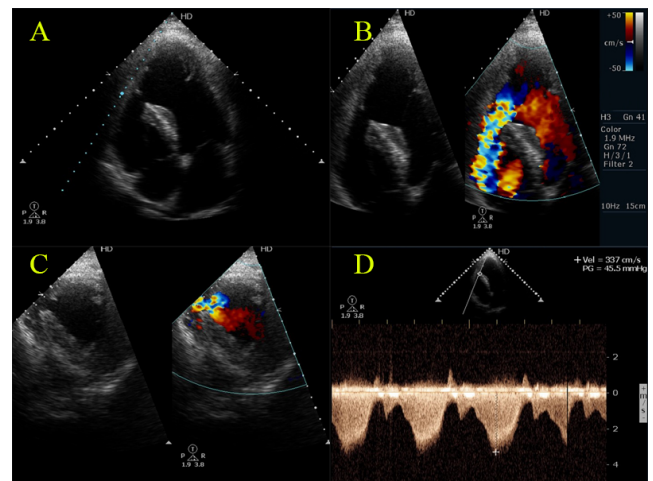


Figure 1. Non-restrictive apico-septal VSR.

*Correspondence to:

Mahmoud Abdelnaby

Department of Clinical and Experimental Internal Medicine

Cardiology and Angiology Unit, Medical Research Institute

University of Alexandria

Egypt

Tel: +201007573530

E-mail: Mahmoud.hassan.abdelnabi@outlook.com